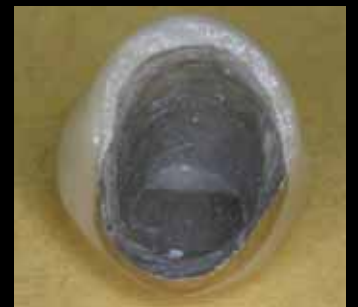
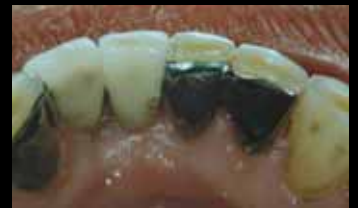
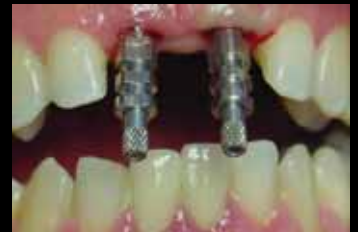# Planning and Making **Crowns and Bridges**

**Fourth Edition**

**Bernard GN Smith  
Leslie C Howe**



**informa**  
healthcare



مرکز تخصصی پروتزهای دندانی

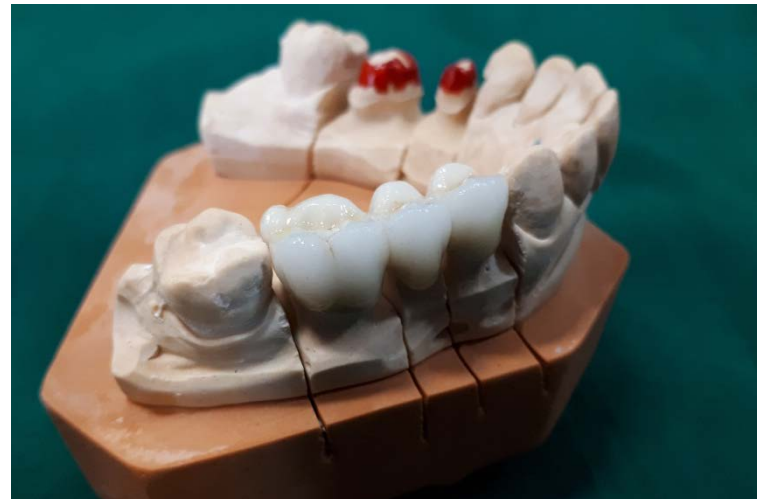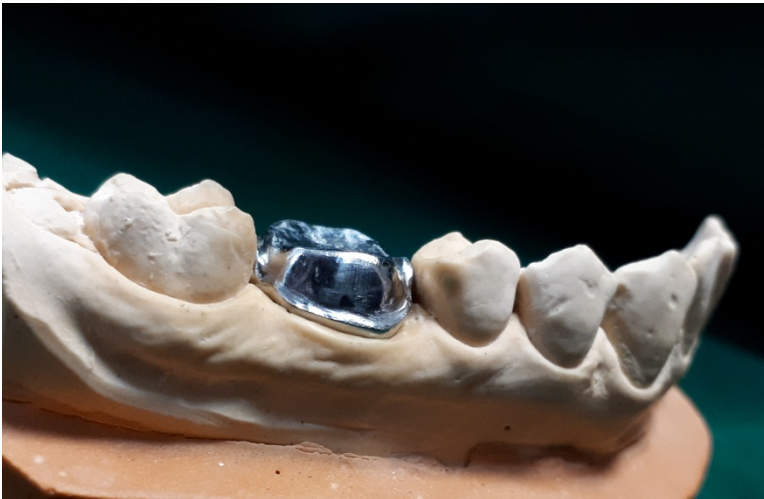هاک دنت

طراحی و ساخت انواع پروتزهای دندانی بویژه ایمپلنت

برگزار کننده دوره های آموزشی تخصصی و جامع دندانسازی و...

**با ما همراه باشید...**

**[WWW.HIGHDENTLAB.COM](http://WWW.HIGHDENTLAB.COM)**



## **Planning and making crowns and bridges**

---

# Planning and making crowns and bridges

---

**Fourth Edition**

**Bernard G N Smith**

BDS, PhD, MSc, MRD, FDSRCSEng, FDSRCSEdin

*Professor Emeritus of Conservative Dentistry  
Guy's, Kings and St Thomas' Dental Institute, London*

**Leslie C Howe**

BDS FDSRCSEng

*Consultant in Restorative Dentistry  
Guy's and St Thomas' NHS Hospitals Trust  
and Private Practitioner*

**informa**  
healthcare

© 1986, 1990, 1998 Bernard GN Smith, 2007 Bernard GN Smith and Leslie C Howe

Fourth edition published in the United Kingdom in 2007 by  
Informa Healthcare  
4 Park Square  
Milton Park  
Abingdon, Oxon OX14 4RN, UK

Informa Healthcare is a trading division of Informa UK Ltd.  
Registered Office: 37/41 Mortimer Street, London W1T 3JH.  
Registered in England and Wales number 1072954.

Tel: +44 (0)20 7017 6000  
Fax: +44 (0)20 7017 6336  
E-mail: [info.medicine@tandf.co.uk](mailto:info.medicine@tandf.co.uk)  
Website: [www.informahealthcare.com](http://www.informahealthcare.com)

All rights reserved. No part of this publication may be reproduced, stored in a retrieval system, or transmitted, in any form or by any means, electronic, mechanical, photocopying, recording, or otherwise, without the prior permission of the publisher or in accordance with the provisions of the Copyright, Designs and Patents Act 1988 or under the terms of any licence permitting limited copying issued by the Copyright Licensing Agency, 90 Tottenham Court Road, London W1P 0LP.

The Authors have asserted their rights under the Copyright, Designs and Patents Act 1988 to be identified as the Authors of this Work.

A CIP record for this book is available from the British Library.

Library of Congress Cataloging-in-Publication Data

Data available on application

ISBN-10: 0 415 39850 9  
ISBN-13: 978 0 415 39850 3

Distributed in the United States and Canada by  
Thieme New York  
333 Seventh Avenue  
New York, NY 10001, USA

Distributed in the rest of the world by  
Thomson Publishing Services  
Cheriton House  
North Way  
Andover, Hampshire SP10 5BE, UK

Composition by Scribe Design Ltd, Ashford, Kent, UK  
Printed and bound in

---

# Contents

---

Preface	vii
Acknowledgements	ix
<b>Part 1 Crowns</b>	
1 Indications and contraindications for crowns	3
2 Types of crown	29
3 Designing crown preparations	53
4 Occlusal considerations	77
5 Planning and making crowns	105
6 Clinical techniques for making crowns	123
<b>Part 2 Bridges</b>	
7 Indications for bridges compared with partial dentures and implant-retained prostheses	177
8 Types of bridge	197
9 Components of bridges: retainers, pontics and connectors	211
10 Designing and planning bridges	225
11 Clinical techniques for bridge construction	241
<b>Part 3 Implants, splints and maintenance</b>	
12 Dental implants	261
13 Fixed splints	287
14 Crown and bridge failures and repairs	297
Index	319



# Preface

The aim of this book is to answer at least as many of the questions beginning with 'why' as those that begin with 'how'. A textbook is not the ideal medium for teaching practical, clinical or technical procedures. These are best learnt at the chair-side and in the laboratory. However, the mass of material which must be learnt, usually in a restricted timetable, in the clinic and laboratory means that there is often insufficient time to answer the questions, 'Why am I doing this?' or, 'When should I not do this?' or even, 'What on earth can I do here?'.

The book is meant for clinicians, both undergraduate and postgraduate, and so although the emphasis is on treatment planning, crown and bridge design and the related theory, clinical techniques are also described in some detail. Laboratory technique is, though, almost completely omitted, both to keep the book to manageable proportions and because most clinicians no longer undertake this themselves. It is nevertheless abundantly clear that a good standard of laboratory work is as important as the other phases in the construction of crowns, bridges and implants.

The process may be divided into three stages:

- Initial decision making and mouth preparation
- Clinical procedures
- Technical procedures.

The purpose of this book is to help quite a lot with the first stage, rather less with the second (a book cannot replace clinical experience) and hardly at all with the third.

The intention is to help solve real clinical problems. The student sitting in a technique laboratory faced with an arch of intact perfectly formed natural or artificial teeth planning to undertake 'ideal' crown preparations will find little help here. It may be good initial teaching to cut 'classic' preparations, but this is only part of the training towards solving the real problems of real patients in the real world. The opinions expressed in a textbook can only go a little way further towards solving these problems.

Undergraduate and postgraduate students need also to take advantage of their own and others' clinical experience and learn by thinking about their clinical problems and talking about them with others. Making the right decision is as important as executing the treatment well.

There is no reference to 'case selection' or 'patient selection' for the techniques described. That is not the way things are in practice. There it is necessary to select the appropriate technique for the patient in front of you rather than select the patient for the technique. Things are different in dental schools. It often happens that in order to provide a balanced range of experience for undergraduate students in a limited period of time, patients are selected to go on to particular waiting lists to provide a flow of 'clinical material' for the students' needs. This may be necessary but the attitudes it sometimes develops are unfortunate. The essential feature of any profession is that it attempts to solve the problems of its clients before concerning itself with its own welfare.

Because this is the approach, clinical photographs or at least photographs of extracted teeth or casts, are used to illustrate the text in preference to line drawings, except where a photograph is impractical. Photographs are used even when the work shown is not 'perfect'. No apology is made for this. In reality, although we should strive for perfection (if we know what perfection is in a given case, and we often do not), we will frequently not achieve it. It is more realistic to talk about levels of acceptability. This is not to advocate unnecessary compromise, but to recognise that in many situations a compromise (from knowledge, not ignorance) is necessary. After all, the ideal would be to prevent caries, trauma and congenital deformity so that crowns and bridges were not necessary in the first place. Once they are needed there is already a situation that is less than perfect.

Some of the work photographed is the authors', some is undergraduate and postgraduate student work with a greater or lesser amount of help by teachers, some of the technical work is carried out



by the clinicians themselves but most by technicians or student technicians, and some illustrations have been kindly lent by colleagues. In view of the likelihood, and indeed the intention that readers will find fault with some of the illustrations and because some illustrate the work of a team rather than an individual, no acknowledgement is given for individual illustrations. We are, however, extremely grateful to all those who have allowed us to photograph their work and in particular to those who have lent their own illustrations. Their names appear in the Acknowledgements.

There are no text references. In a book of this size, which is not intended to be a reference book, it is not possible to be comprehensive, while it is impolite to use phrases such as 'there is evidence that . . .' without making proper reference to the source of the evidence. Isolated references in these cases could well lead the enthusiastic student into an unbalanced reading programme. The further reading suggestions which were in previous editions have been omitted as they so quickly became out-of-date in this fast-developing field and because computer access to the literature is now very easy.

Leslie Howe has joined Bernard Smith as a joint author for the fourth edition. His influence can be seen throughout the book and particularly in

the new Chapter 12 on implants. Much more attention is given to implants than in previous editions. Modern implants had only recently been introduced into the UK when the first edition was published. The purpose is to help dentists to advise patients in their choice of what to do when teeth are missing. It is also to inform dentists about details of implant treatment so that they can explain to patients what to expect and help them to make informed choices.

Chapter 12 is not sufficient to guide dentists in starting to place implant-retained restorations themselves. Much more training is needed before that can be done. A comparison can be made with referral for orthodontic treatment which, like implants, most dentists do not offer but they do need to know who and when to refer and to be able to answer patients' questions.

Much of the material in earlier editions has been omitted as being out-of-date; however, some restorations which are no longer made but which a significant number of patients continue to wear satisfactorily are still included so that dentists can recognise them and know something about their maintenance and repair.

Because of these deletions, many illustrations have been left out but even more have been added.

BGNS  
LCH

---

# Acknowledgements

---

The following have lent photographs but for reasons explained in the preface, specific credit is not given to each one. We are, however, extremely grateful to them for their generosity: Chris Allen; David Bartlett; Nicholas Capp; John Cardwell; Russell Greenwood; George Kantorowicz; Bernard Keiser; Frances Manochi; Orthomax Limited, Bradford; Richard Palmer; David Parr; Ian Potter; John Richards; David Ricketts; Paul Robinson; Saridatum Abdul Samal;

Evelyn Sheehy; Michael Thomas; Sachim Varma; John Walter; Katherine Warren; Tim Watson.

Other help with illustrations has been given by: Ruth Allen; Osama Atta; Dennis Bailey; Trevor Brooker; Peter Chittenden; Cottrell and Co., London; Usha Desai; Andrew Dyer; Terence Freeman; Richard Hamill; June Hodgkin; Orodent Limited, Windsor; Peter Pilecki; Peter Rhind; Bill Sharpling; Nicholas Taylor; Leslie Wilcox; Geraldine Williams.



---

# Part I Crowns

---



# I Indications and contraindications for crowns

Before the introduction of techniques to bond restorative materials to teeth, crowns were the only way of restoring teeth that can now be restored by these other techniques. At the same time, more patients are keeping more of their teeth for longer and are expecting faulty teeth to be repaired rather than extracted. Therefore, although there are fewer indications for crowning teeth than there were, more teeth are actually being crowned than ever before. About two million crowns per year are made in the UK National Health Service, representing two to three crowns per week per dentist. In the latest (1998) Adult Dental Health Survey in the UK, a third of all dentate adults had at least one crown and nearly half the 45–54 age group had one or more crowns. Similar numbers of crowns are being made in many other countries.

So, a lot of crowns are still being made.

When the only choice for a tooth was a crown or extraction, the decision was relatively simple. Now, with more options it is more difficult. This chapter discusses the current indications for crowns and their alternatives, and guides the reader towards a decision. However, clinical decision making is the very substance of the dentist's work and cannot be done by textbook instructions: do not expect a set of clear rules to follow. Each set of clinical judgements and decisions must be unique, taken in the context of the patient's circumstances.

## General indications and contraindications for crowns

### *Crowns versus fillings in the treatment of caries*

Most dental restorations are provided as treatment for dental caries. Once the initial lesion has penetrated the enamel, the caries spreads along

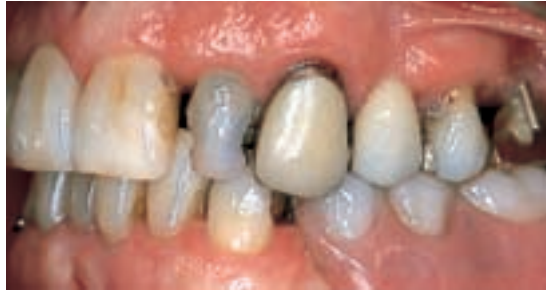the enamel–dentine junction and balloons out in dentine towards the pulp. The growth of the carious lesion is much faster in dentine than it is in enamel, so the enamel becomes undermined and then suddenly collapses into the cavity. (Because of this, our forefathers thought that caries started inside the tooth and worked its way to the surface.) Today, many carious lesions are detected and treated at an early stage while the enamel is still largely intact. Indeed, even more lesions are prevented from occurring at all.

Since caries produces most of its damage inside the tooth rather than on the surface, the commonest types of restoration are fillings (intracoronal restorations). Often, sound enamel has to be cut away to give access to the caries. Only very rarely is the surface of a tooth extensively destroyed by caries leaving a base of sound dentine, and it is therefore most unusual in the treatment of primary caries for a crown (an extracoronal restoration) to be made on a preparation consisting of intact dentine. When secondary caries develops around existing fillings, intracoronal restorations are still more conservative and more closely relate to the pattern of development of caries than crowns, and are therefore preferred whenever possible. Indeed, a high caries rate is a contraindication to crowns. In these cases the caries should be removed, the tooth stabilized and a preventive regime instituted before crowns are made.

With larger lesions and particularly when cusps are lost, the decision between filling and crowning a tooth becomes more difficult (see pages 20–25).

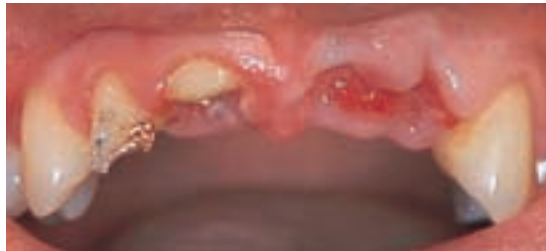### *General indications for crowns for other reasons*

Having established that primary caries is not a common reason for making crowns, more common reasons are:

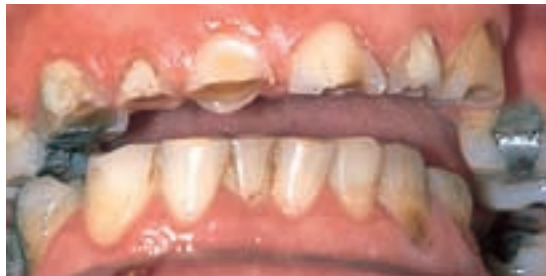**Figure 1.1**

General indications for crowns.

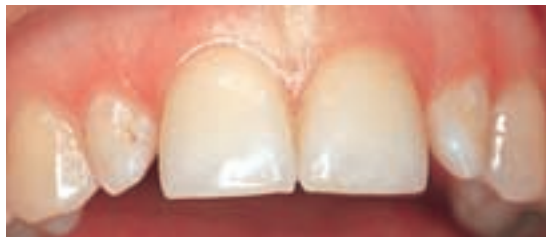*a* This mouth has been well treated in the past but the restorations are now failing. In particular the lateral incisor has lost two fillings, the pulp has died and the tooth is discoloured. It now needs a crown (Figure 2.1k).



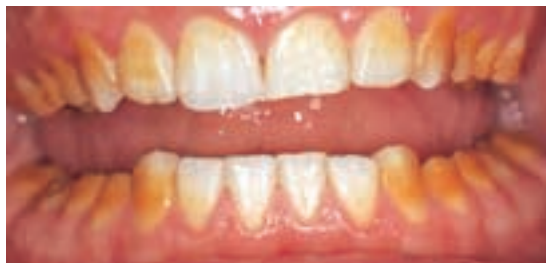*b* Trauma: the result of a blow from a hockey stick. Two incisors have been lost and the upper right central incisor is fractured, exposing the pulp, the fracture line extending subgingivally on the palatal side. The lateral incisor is fractured involving enamel and dentine only. The pulp retained its vitality. Although it could be restored in other ways, a crown would be the most satisfactory solution since it would then match the other anterior restorations. If the central incisor is to be retained, it will need to be root-filled and crowned, probably as a bridge abutment (see later).



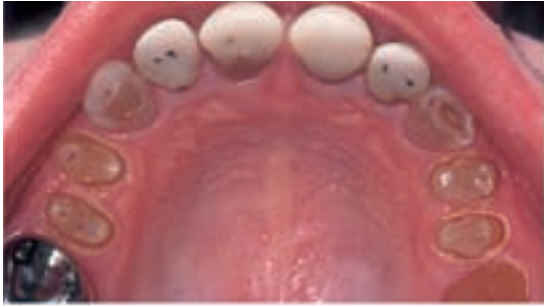*c* Gross tooth wear arising from a combination of erosion and attrition. This has passed the point where the patient can accept the appearance, and crowns are necessary.



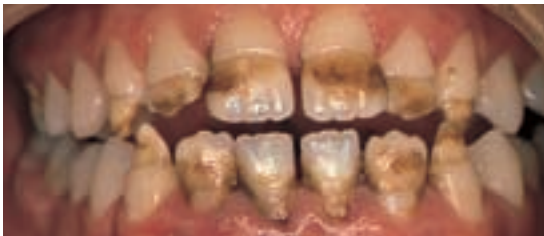*d* Peg-shaped upper lateral incisors.



*e* A moderate degree of amelogenesis imperfecta (defects in the formation of enamel) in a 16 year old. The posterior teeth are affected more than the anterior teeth but the upper incisors are slightly discoloured and are chipping away at the incisal edge. Crowns were made for all the teeth except the lower incisors and these will be kept under review.



f Dentinogenesis imperfecta (a defect in the formation of dentine) in a teenage patient. The incisor teeth have been protected with acid-etch-retained composite from shortly after their eruption and the first molar teeth have been protected with stainless-steel crowns. It is now time to make permanent crowns for all the remaining teeth.



g Typical distribution of enamel hypoplasia, in this case due to typhoid in the patient's early childhood. Crowns were made rather than composite restorations or veneers because the stain was too dark to be disguised by these means.

- Badly broken-down teeth
- Primary trauma
- Tooth wear
- Hypoplastic conditions
- To alter the shape, size or inclination of teeth
- To alter the occlusion
- As part of another restoration
- Combined indications
- Multiple crowns
- Appearance.

### Badly broken-down teeth

Extensive composite or amalgam fillings bonded to the remaining tooth structure or retained by other means have the advantage of being directly placed, are conservative of tooth structure and do not involve laboratory procedures. However, when very large, involving most of the occlusal surface, such restorations are rarely able to produce an acceptable occlusal and proximal contour and have an unpredictable long-term durability and so a crown may be the treatment of choice.

Usually these teeth will have been restored previously, and may have suffered secondary caries or parts of the tooth or restoration may have broken off. Before crowns can be made the

lost dentine will often need to be replaced by a suitable core of restorative material sometimes following endodontic treatment (Figure 1.1a).

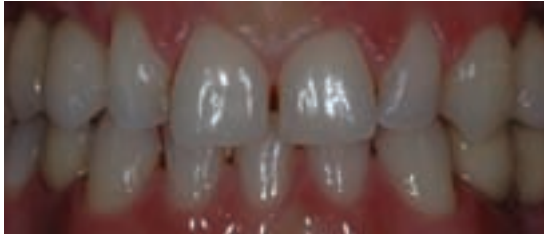### Primary trauma

An otherwise intact tooth may have a large fragment broken off without damaging the pulp and leaving sufficient dentine to support a crown: see the upper right lateral incisor in Figure 1.1b. If this was the only tooth damaged then a directly placed composite restoration bonded to the remaining tooth structure would usually be the initial treatment, progressing to a crown if the direct restoration was inadequate or failed.

### Tooth wear

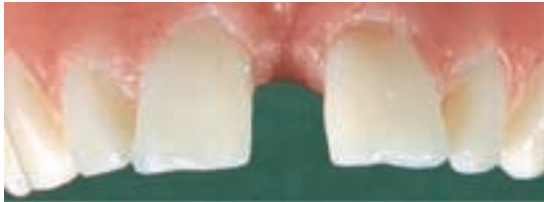
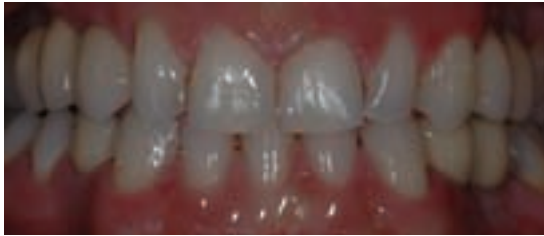The processes of erosion (damage from acid other than that produced by bacteria), attrition (mechanical wear of one tooth against another) and abrasion (mechanical wear by extraneous agents) occur in all patients. What is remarkable is that teeth, which have little capacity for regeneration and which are in constant use, do not wear out long before the patient dies. Although tooth wear is normal, if it is excessive or occurs



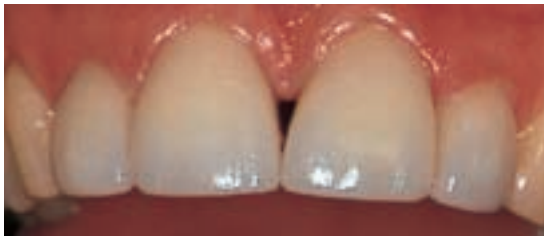**Figure 1.2**

Changing the shape and size of teeth.

*a* and *b* Increasing the size of incisors with composite:  
*a* before, *b* after.



*c* A large midline diastema that the patient found aesthetically unacceptable.



*d* The same patient after the central incisors have been moved closer together orthodontically and all four incisors crowned. The patient must be warned of any compromise in the appearance that is anticipated – in this case the triangular space that remains at the midline. It is possible to increase the width of the incisal edges to fill the space, but the width of the crowns at the neck is determined by the width of the roots, so that only minimal enlargement is possible without creating uncleanable overhanging crown margins. It is unlikely that a long-term acceptable result could have been achieved with composite in view of the size of the gap.

early in life, crowns or other restorations may be needed (Figure 1.1c).

The lifelong management of excessive tooth wear is a topic of increasing interest as patients keep their teeth longer. In general the approach should be:

- Early diagnosis and prevention.
- Monitoring any further progression until the

patient complains of the appearance, sensitivity (which does not respond to other treatment), function is affected, or the wear reaches a point where restorations will become technically difficult.

- At this point provide minimal restorations, normally directly bonded composite restorations.
- If the problem continues, provide crowns.



**Figure 1.3**

An attractive appearance spoiled by unsightly teeth.

### Hypoplastic conditions

These are divided into congenital and acquired defects. Examples of congenital defects are hypodontia (small teeth – see the peg-shaped lateral incisors in Figure 1.1d), amelogenesis imperfecta (Figure 1.1e) and dentinogenesis imperfecta (Figure 1.1f). Examples of acquired defects are fluorosis, tetracycline stain and enamel hypoplasia resulting from a major metabolic disturbance (usually a childhood illness) at the age when the enamel was developing (Figure 1.1g).

### To alter the shape, size or inclination of teeth

Major changes in the position of teeth can be made only by orthodontic treatment, although minor changes in appearance can be achieved by building up the tooth with composite or by composite or porcelain veneers (see pages 13–20). For example, a diastema between teeth which the patient finds unattractive can be closed or reduced by means of additions of composite or veneers following orthodontic treatment (Figure 1.2a and b). However, when the space is large, oversized crowns will produce a durable and attractive result (Figure 1.2c and d). This approach

is very destructive of tooth tissue and composite or veneers should always be attempted first before irreversibly preparing the teeth for crowns.

### To alter the occlusion

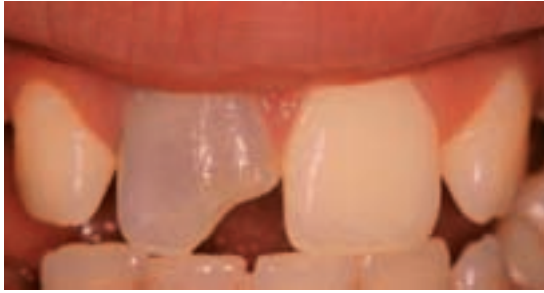Crowns may be used to alter the angulation or occlusal relationships of anterior and posterior teeth as part of an occlusal reconstruction either to solve an occlusal problem or to improve function (see Chapter 4).

### As part of another restoration

Crowns are made to support bridges and as components of fixed splints. They are also made to alter the alignment of teeth to produce guide planes for partial dentures or to carry precision attachments for precision attachment retained partial dentures (see Parts 2 and 3).

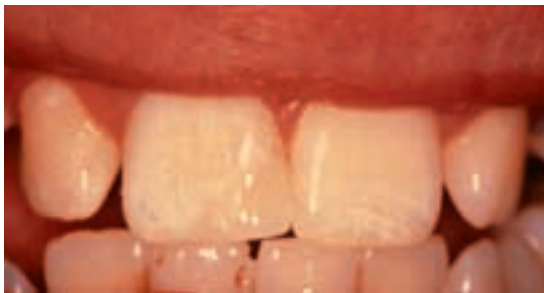### Combined indications

More than one of these indications may be present, so that, for example, a broken-down

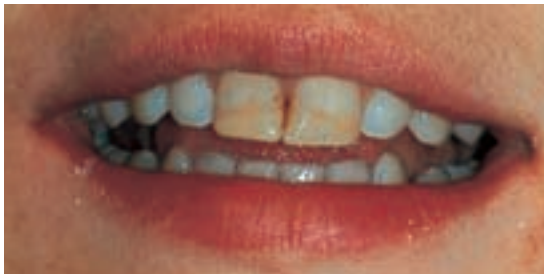**Figure 1.4**

The appearance of composite restorations.

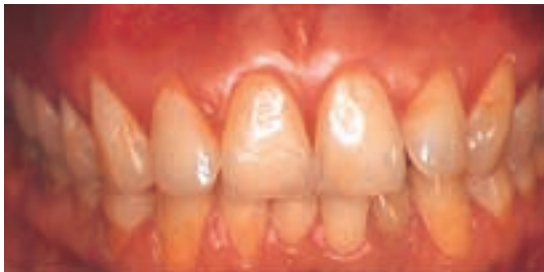*a* Following trauma the right central incisor tooth requires root canal treatment.



*b* The appearance of the tooth has been restored by internal bleaching and a composite repair to the mesial corner.



*c* The central incisors were fractured in a riding accident 8 years earlier. Composite restorations were placed by the patient's mother and then replaced by another dentist and again at a dental school. These restorations have been in place for 3 years and are discolouring again. The patient was 21 and refused further composites and crowns were made.

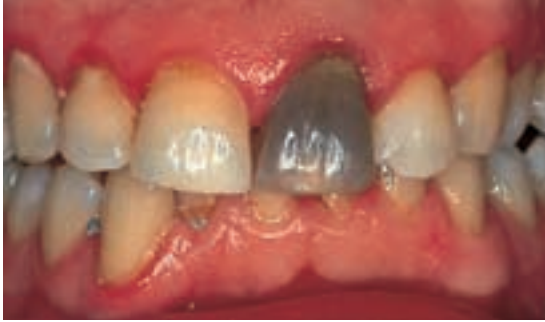

*d* Composite restorations at the necks of all the incisor teeth. They have been present for 18 months and are maintaining their appearance.

posterior tooth that is over-erupted and tilted may be crowned as a repair and at the same time to alter its occlusal relationships and its inclination, providing a guide plane and rest seat for a partial denture.

### Multiple crowns

With some of these indications, notably tooth wear and hypoplastic conditions, many or all of the teeth may need to be crowned.



**Figure 1.5**

The central incisor has a necrotic pulp and is grossly discoloured. This degree of discoloration could not be resolved by bleaching or veneering the tooth. The periodontal condition must be improved before a crown can be made successfully.

### Appearance

One of the principal reasons for patients seeking dental treatment is to maintain or improve their appearance. Relative prosperity, changing social attitudes and the success of modern dental materials mean that expectations of good dental appearance are rising. Fewer teeth are being extracted, and when they are it is at a later age. It is much less common now to see a mouth such as that shown in Figure 1.3) than it was in the mid-1960s, when this photograph was taken. As standards of appearance and expectations rise, some dental defects or types of restoration, which at one time would have been tolerated, are no longer acceptable to patients.

Much more can now be done to improve appearance with the current range of composite materials than was the case a few years ago. Composite has the advantage of being more adaptable than porcelain. It is applied, shaped and polished at the chair-side and later it can be repaired and resurfaced (Figure 1.4). This means that crowns are now less often indicated to improve appearance.

Many patients simply wish to lighten the colour of their teeth, which may have darkened with age or from smoking. If the teeth are substantially sound and their position and shape are acceptable to the patient, a significant improvement can be made by thorough cleaning and external bleaching (see Figure 1.7). However, sometimes the discolouration is so intense that bleaching alone will not provide a satisfactory result (Figure 1.5). Initial bleaching to lighten the tooth as much as possible helps because the crown then does not have to disguise too dark a preparation.

Appearance is important to the patient and is therefore important to the dentist. After the

relief and prevention of pain and infection it is probably the next most important reason for providing dental treatment.

### Function

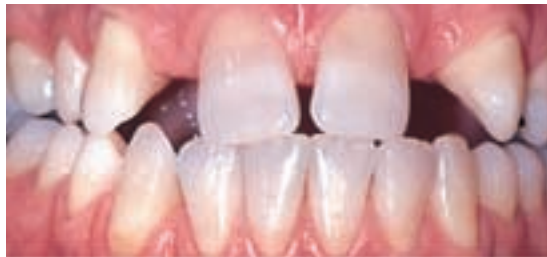It is possible to eat and speak without any teeth, or with complete dentures, but most patients (and probably all dentists) do not want to. As with appearance, this is a question of the quality of life. An occluding set of natural, or second best, restored teeth is better at coping with a full varied range of diet than dentures.

### Mechanical problems

Sometimes, although it would be possible to restore a tooth by means of a filling, the pattern of damage to the tooth gives rise to anxieties about the retention of the restoration, the strength of the remaining tooth tissue, or the strength of the restorative material. The degree to which a crown strengthens the remaining tooth structure compared to a bonded intra-coronal restoration is not clear. Usually, however much damage there is, some sound tooth tissue needs to be removed to prepare the tooth for a crown (see Figure 1.12).

Fillings fail because they fall out, because of secondary caries, or because part of the tooth or part of the restoration fractures. These failures are upsetting to the patient and embarrassing to the dentist, and it is therefore tempting to prescribe crowns when there is even a small possibility that one of these problems will arise.

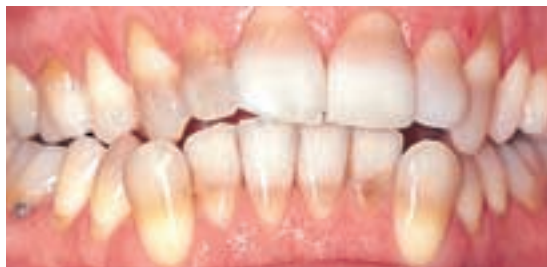However, crowns can also fail. If a filling fails, it is often possible to make a more extensive



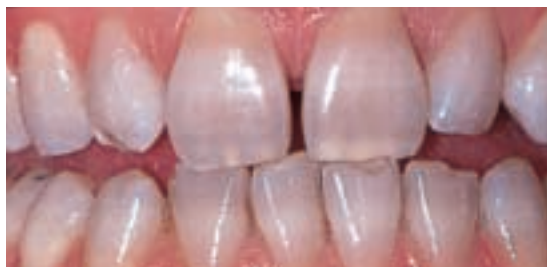**Figure 1.6**

Tetracycline stain.

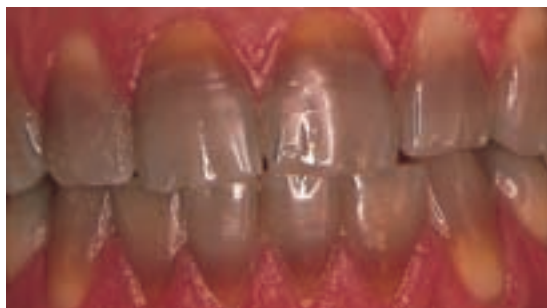*a* Mild, uniform staining. It is unlikely that treatment will be necessary other than to replace the missing lateral incisors.



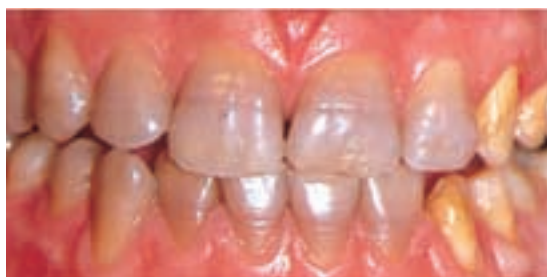*b* Tetracycline staining with severe banding. The extent of treatment depends on the lip line. In this case the lower lip covered the gingival half of the lower incisors, and therefore treatment for the lower teeth was not necessary.



*c* Darker but more uniform tetracycline staining. In this case a vital bleaching technique was used.



*d* Extreme tetracycline staining with banding.



*e* Darkly stained teeth with four teeth, the upper and lower left premolars, prepared for crowns.

restoration or a crown. If a crown fails, a further crown may not be possible and extraction may be all that is left.

In deciding between a crown and a filling there are two considerations to be weighed up. First, how real is the risk of mechanical failure of the filling or surrounding tooth and what can be done to minimize this risk? Second, how much more destruction of sound tooth tissue is necessary to make a crown?

In general, it is better to take the more conservative approach first, even if this involves some risk of the restoration failing. The alternative is to provide far more crowns than are strictly necessary and perhaps give rise to even greater problems for the patient later on.

## Indications for anterior crowns

### **Caries and trauma**

All the general indications listed above may apply to anterior crowns. Before the days of acid-etch retained composite restorations and composite and porcelain veneers, anterior crowns were indicated much more frequently for the restoration of carious or fractured incisors. Today many of these teeth can be restored without crowns, which are often not needed until the pulp is involved (Figure 1.1a and b).

### **Non-vital teeth**

When a pulp becomes necrotic the tooth often discolours due to the haemoglobin breakdown products. Internal bleaching (see Figure 1.7a and b) is the initial treatment of choice and will often produce a good initial result, although sometimes some of the discolouration returns. However, the discoloration may be such that it can only satisfactorily be obscured by a crown following initial bleaching to produce a lighter core for the crown (Figure 1.5).

### **Tooth wear**

The ideal approach to problems of tooth wear is to prevent the condition getting worse by identi-

fying the cause and eliminating it as early as possible. Crowns should be made only when the cause of the tooth wear cannot be identified or cannot be eliminated, and the damage is serious. Sometimes the rate of tooth wear slows down or stops with no obvious explanation and the teeth remain stable for some years. Crowns are not a good preventive measure except as a last resort.

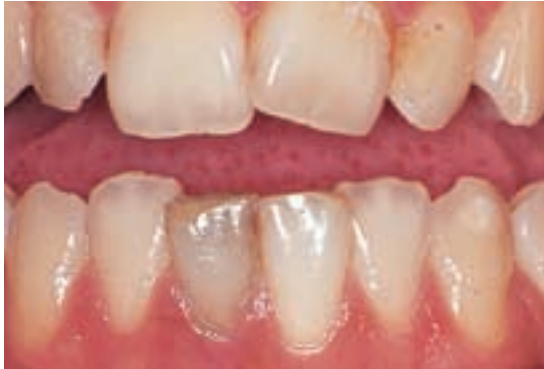### **Hypoplastic conditions**

In many of the hypoplastic conditions the patient (or parents) will seek treatment at an early age, often as soon as the permanent teeth erupt, and treatment may be carried out in conjunction with orthodontic treatment. In some of these cases large numbers of teeth are affected, and so the decision whether to crown them, offer some alternative form of treatment, or simply leave the condition alone, is a fairly momentous one. Figure 1.6 shows several cases of tetracycline staining affecting many teeth. Differences in the lip morphology, the depth of uniformity of the colour, and the patient's age and general attitude will all influence the decision.

Unfortunately tetracycline stain often does not respond well to bleaching, particularly when the staining is in bands. The success of veneers depends on the quality of the remaining enamel for bonding, but in suitable cases veneers are the ideal treatment. The option of multiple crowns is a considerable undertaking and should not be embarked upon lightly by either patient or dentist. In particular with young patients, the lifelong maintenance implications must be fully understood. It should be explained that crowns are very unlikely to last the whole of a natural lifetime and replacements will be costly if they are possible at all. If veneers are made first the teeth can still be crowned later but the opposite is not true.

However, if after proper consideration crowns are made, they can dramatically improve the patient's appearance in a way that is difficult or impossible by any other form of treatment.

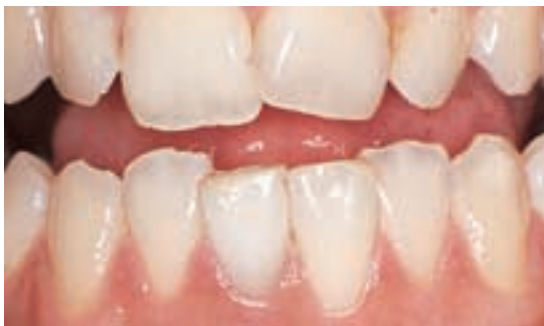The decision often has to be made while the patient is a teenager, when social development can be seriously affected by appearance including dental appearance. This is often an important factor in making decisions on whether, how and when to treat.



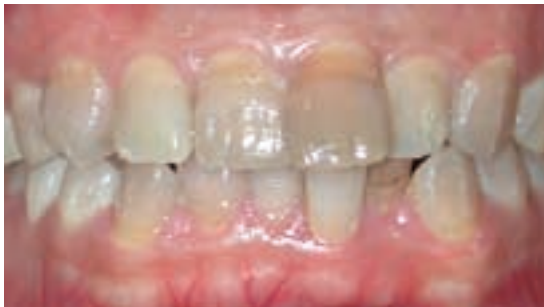**Figure 1.7**

Alternatives to crowns – bleaching.

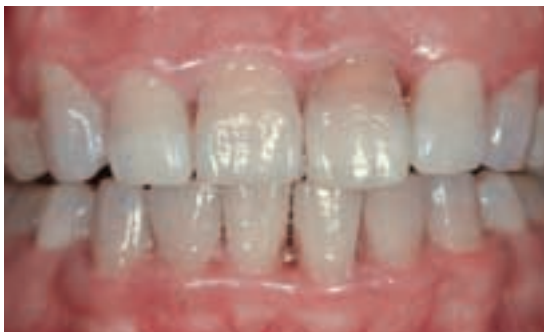*a* A discoloured, non-vital lower central incisor.



*b* The tooth shown in *a* has been root-filled and internally bleached to produce a satisfactory appearance.



*c* This young patient was unhappy with the appearance of their crowded discoloured teeth. The discoloration is due to tetracycline given when the patient was a child. Extensive and complex restorations could be considered but the simplest approach would be to undertake orthodontic treatment and then improve the colour of the teeth with external home bleaching.



*d* The resulting appearance following external vital bleaching – although not perfect the patient is happy with the result and extensive restorations have been avoided.

**As part of other restorations**

Sometimes crowns are needed to support partial dentures. Crowns as part of bridges and splints are dealt with in Parts 2 and 3.

**What are the alternatives to anterior crowns?****Internal and external bleaching**

Bleaching agents can be used to lighten the colour of teeth by internal or external application. Controversy over the legality of some bleaching materials and techniques in the UK has been resolved after much debate. Dentists should be aware of the regulations in their own countries before using some of the bleaching materials and techniques.

The advantage of tooth bleaching is that it offers simple and conservative improvements for patients who simply want whiter teeth or to reverse some of the effects of aging without damaging tooth structure. Tooth bleaching techniques cannot do anything other than improve colour and remove staining.

**Internal bleaching**

Discoloured non-vital teeth can be treated by removing the contents of the pulp chamber and sealing the root canal with a glass ionomer cement at or just below the gingival level to prevent leakage of the bleaching agent into the canal. Hydrogen peroxide gel or a slurry of hydrogen peroxide and sodium perborate is left sealed in the tooth for 24 hours and repeated until the desired shade is obtained (Figure 1.7a and b). The access cavity needs to be completely sealed to prevent future relapse. Internal bleaching will not improve the colour of teeth made grey by the corrosion of dental amalgam fillings in access cavities.

**External bleaching**

Vital teeth can be lightened by various techniques with the external application of carbamide peroxide or other bleaching agents (Figure 1.7c and d).

The home bleaching technique employs a 2% carbamide peroxide gel applied to the teeth within a customized tray that the patient wears overnight. Chair-side bleaching utilizes a more concentrated carbamide peroxide gel applied by the dentist and activated by heat or light to act in a short period of time. The colour changes achieved by both techniques are not permanent but can be repeated. Vital bleaching techniques applied over lengthy periods of time can treat even very severe discolouration such as some types of tetracycline staining.

**Composite restorations**

The appearance of modern composite restorations is excellent (Figure 1.4). With the rapid development of anterior restorative materials, it is better in many cases to replace and repair restorations until such time as even more durable materials are available, rather than make crowns.

It is clear that no absolute rules can be given on whether crowns or fillings are indicated other than to say that in general the more conservative procedures are to be preferred.

**Composite and porcelain veneers**

There has been a debate in the dental profession about the advantages and disadvantages of these two materials for veneers. Considerations in this debate are discussed below.

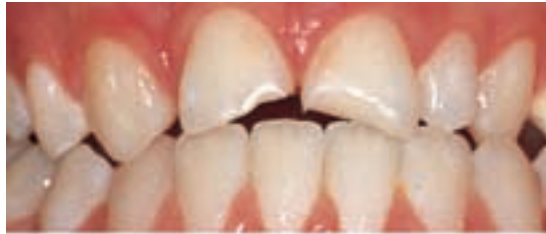**Appearance**

Both can have a very good appearance initially (Figure 1.8). Earlier composites tended to wear and discolour, losing the quality of their appearance. However, this is less of a problem with the improving current materials. When veneers are being made to mask intense discoloration porcelain veneers may be preferred because they can have an initial layer of opaque porcelain which helps to mask discoloration.

**Reversibility**

Composite veneers can be made very thin and so often do not need any tooth preparation. They

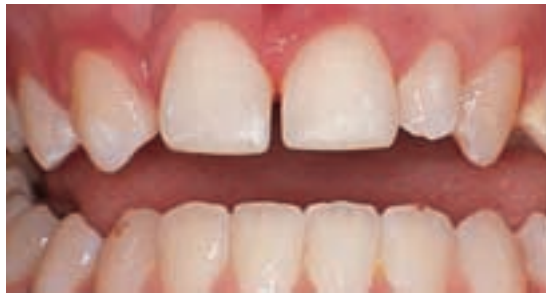



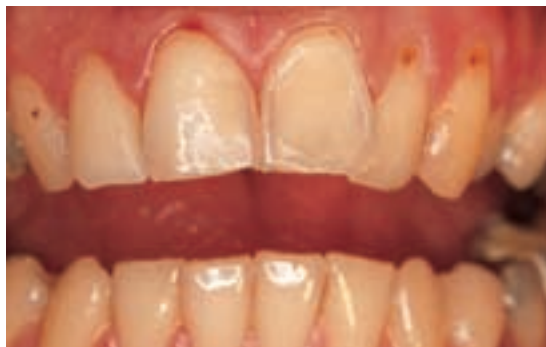**Figure 1.8**

Alternatives to crowns – veneers.

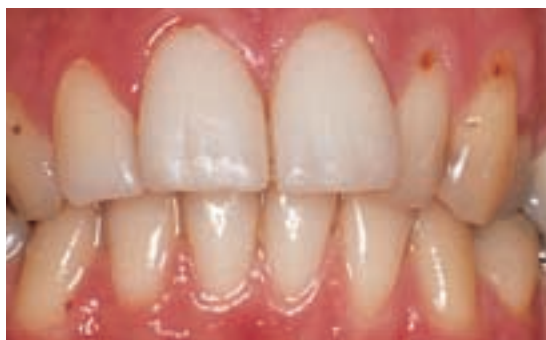*a* Broken and eroded incisor teeth.



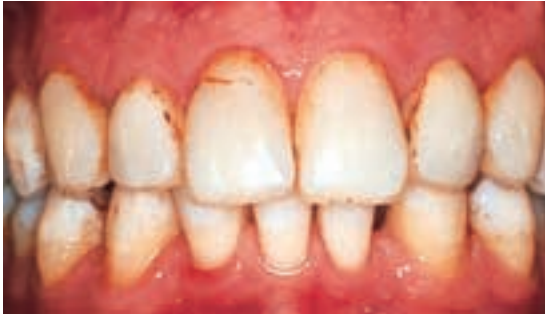*b* The same patient as shown in *a* with composite veneers 3 years after being placed.



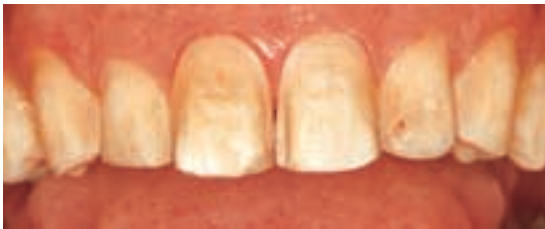*c* Eroded upper central incisors.



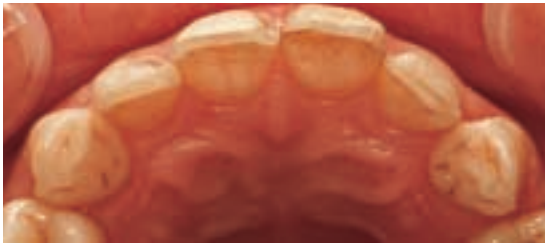*d* The same patient as shown in *c* with two porcelain veneers in place.



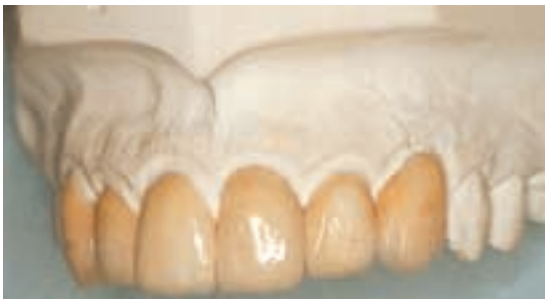e Polyacrylic veneers which have been in the mouth for several years. The margins are staining and chipping.



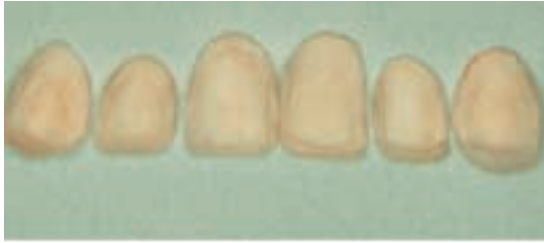f The same patient as e. The polyacrylic veneers have been removed and the six anterior teeth prepared for porcelain veneers.



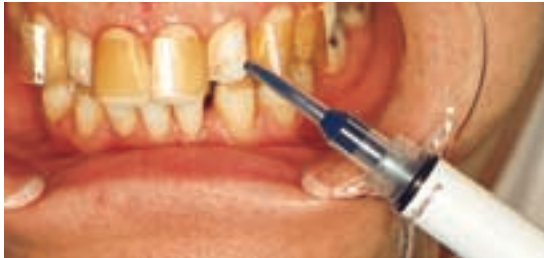g An incisal view of the prepared teeth.



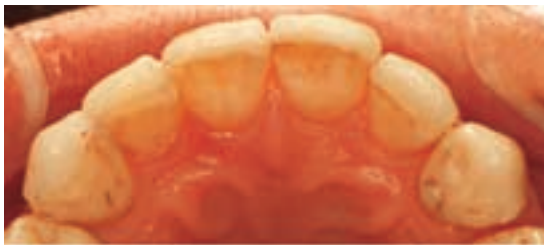h Porcelain veneers on the model for the patient shown in e and f.



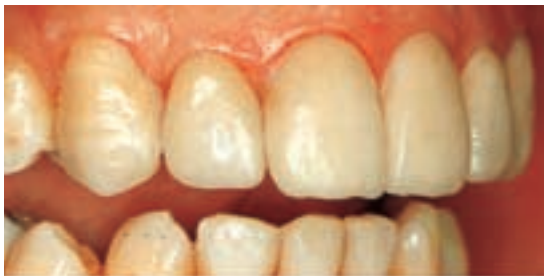*i* The etched fit surface of the porcelain veneers.



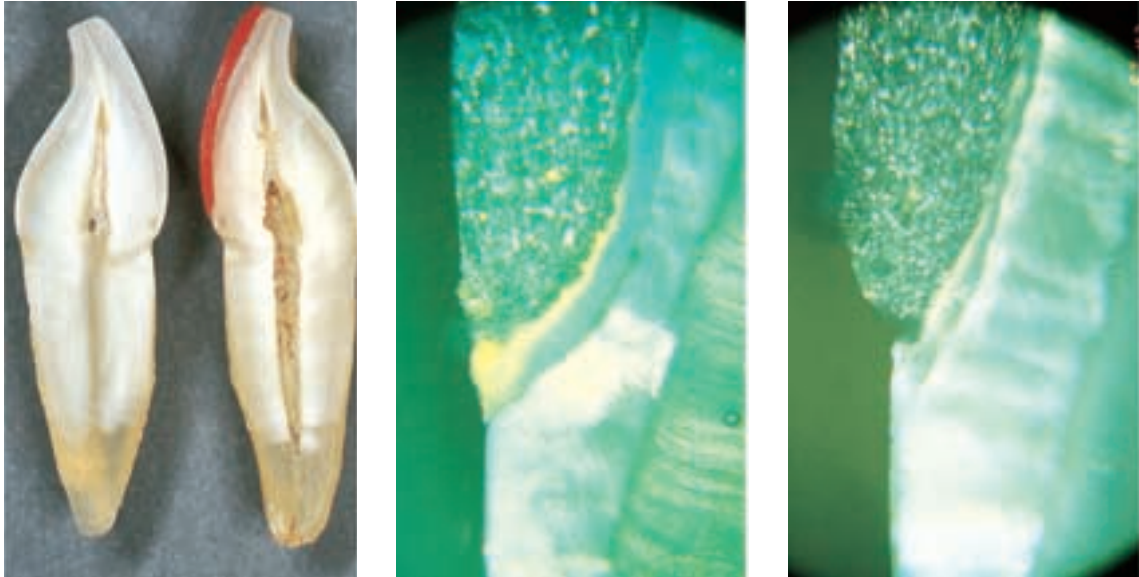
*j* The teeth have been isolated with acetate strip and are about to be etched with phosphoric acid gel.



*k* An incisal view of the porcelain veneers in place. In this case the porcelain was carried over the incisal edges



*l* The completed porcelain veneers.

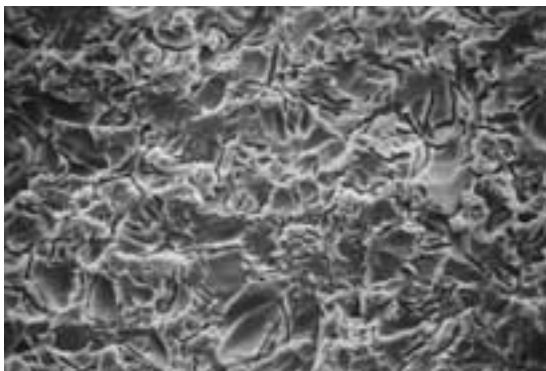


**Figure 1.9**


*a* A sectioned upper central incisor tooth. *Left* the intact tooth, *right* the tooth has been prepared for a porcelain veneer and the profile of the veneer is illustrated in wax. The features of this preparation are that the gingival margin is chamfered and is in enamel and the incisal edge preserves the bulk of the natural tooth. Had the incisal edge been more worn the veneer preparation could have been taken over it as in Figure 1.8k.

*b* A view through the confocal microscope of the margin of a porcelain veneer. From the *left* the veneer, the luting cement, enamel and dentine. This is a good fit.

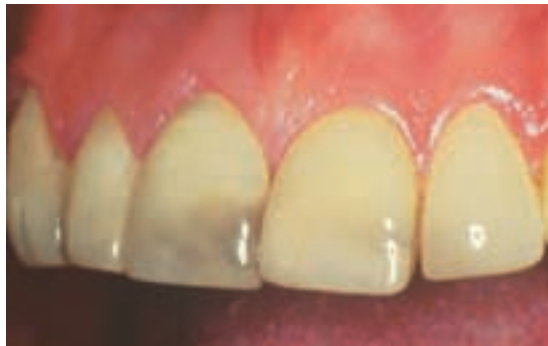*c* A porcelain veneer which has been grit-blasted too much in its construction, leaving the margin deficient.



*d* Porcelain surface etched with hydrofluoric acid. A grit-blasted surface looks similar.



*e* A high magnification confocal microscope image with a different contrast medium showing penetration of composite luting cement into dentine tubules on the left and etched porcelain on the right.



**Figure 1.10**

Failing veneers.

These porcelain veneers were made less than a year ago and are now leaking.

can therefore be removed if the result is not ideal. Porcelain veneers almost always need some tooth preparation because the margins cannot be made as thin as composite, which can be tapered down to nothing at the margin (Figure 1.9). This means that porcelain veneers are usually not reversible. Because the indications for veneers usually apply to young people the decision to prepare teeth for porcelain veneers must be considered very carefully. Tooth preparation is irreversible and it is often better to make, and when necessary refurbish, composite veneers, thus allowing the patient to keep their options open for the long term.

### Cost

Porcelain veneers are more costly because two appointments are necessary and considerable chair-side time is necessary for the delicate preparations and the bonding process. Laboratory charges add considerably to the cost. Composite veneers are placed at the chair side in one visit, the total clinical time is usually less than porcelain veneers and there is no laboratory cost.

### Surveys of success and failures of veneers

There have been a number of medium-term surveys that show that the life expectancy of porcelain veneers is commonly less than had been hoped. Fractures and debonding are not uncommon and a frequent type of failure is staining around the margins or even frank leakage (Figure 1.10).

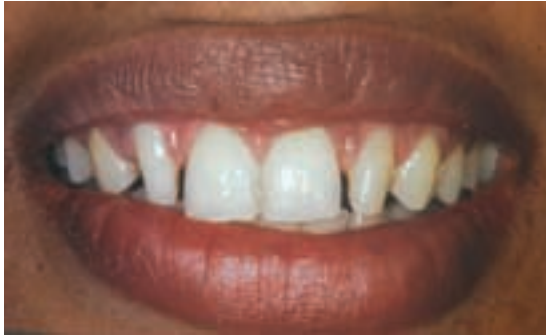Failures like this cannot be repaired and as the tooth has usually been prepared a new veneer or crown is necessary. In an attempt to reduce the effect of marginal staining some clinicians carry the preparations for veneers right through the mesial and distal contact points so that the margin is on the other lingual/palatal side. This is an even more destructive preparation. There have been no good long-term studies of the success and failure of composite veneers, partly because clinicians know that the materials are changing all the time and starting a medium- or long-term survey of a particular material will become redundant in a short time with the introduction of new, better materials. However, clinical experience suggests that composite veneers do have a good medium-term prognosis and also have the advantages that they can be repaired and polished.

See Chapter 14 for a more detailed discussion of the success and failure of restorations.

### Physical properties

The modulus of elasticity of porcelain is quite different to that of enamel. There is a view among some dental material scientists that this difference will inevitably lead to a breakdown of the bond at the margins of veneers in due course. Initially the estimate was about 10 years and some of the surveys confirm this approximate time. The coefficient of thermal expansion is also different between porcelain and enamel and this adds to the likelihood that marginal breakdown will occur.

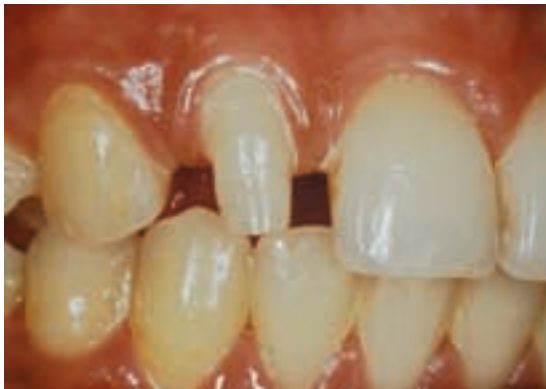Composite is nearer to enamel in terms of these physical properties and because the composite is bonded directly via a bonding resin



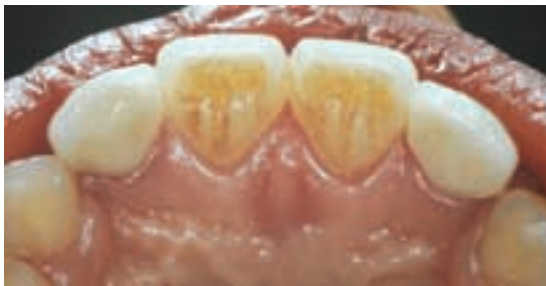**Figure 1.11**

Resin bonded ceramic crowns.

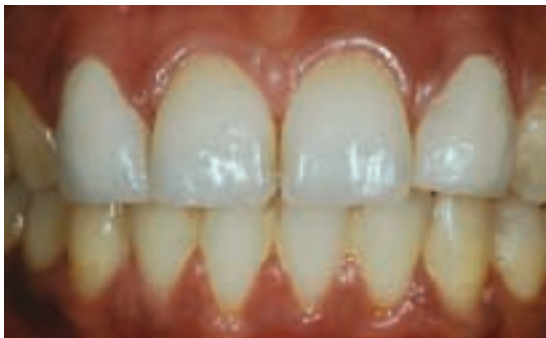*a* Peg-shaped lateral incisors.



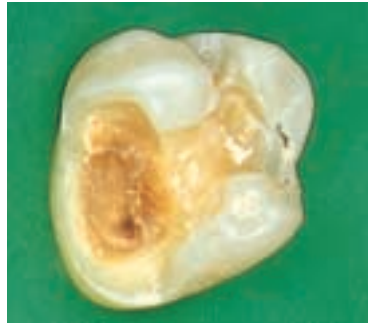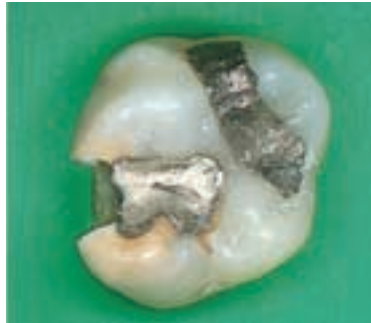*b* The upper right lateral incisor prepared for a resin bonded ceramic crown. The preparation is entirely within enamel. The neck of the tooth has been prepared all round with a chamfer finishing line, similar to the preparation for a veneer, and a small amount has been removed from the incisal edge. Nothing has been removed from the labial or proximal surfaces other than blending them into the gingival finishing line.



*c* Palatal view of the finished crowns.

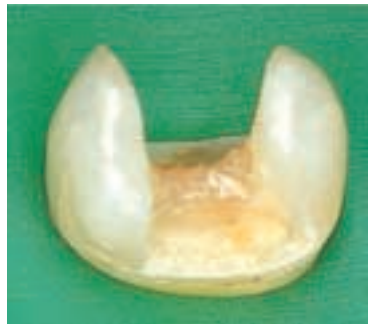
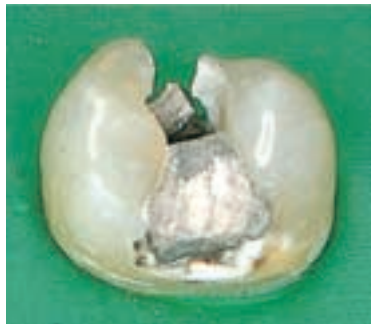
*d* The labial appearance.



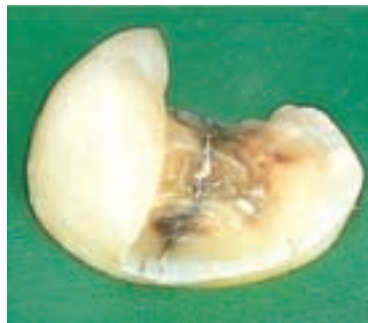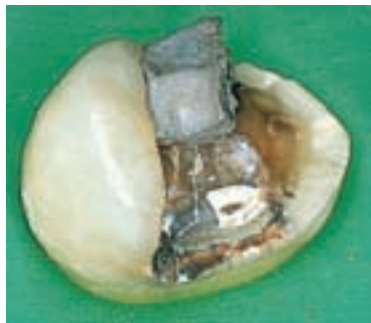**Figure 1.12**

Badly broken-down teeth, all of which were vital when they were extracted. *Left:* the tooth on presentation. *Right:* after removing old restorations, caries and grossly overhanging enamel. Only at this stage can a final decision be made on the most suitable restoration. These teeth could be treated with:



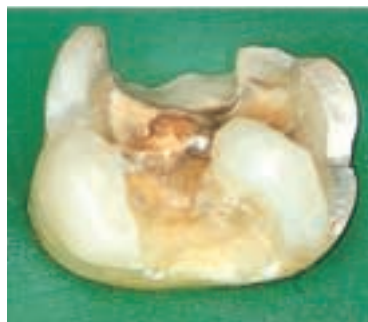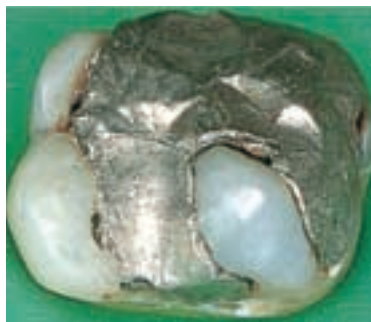*a* a bonded or pin-retained amalgam restoration;

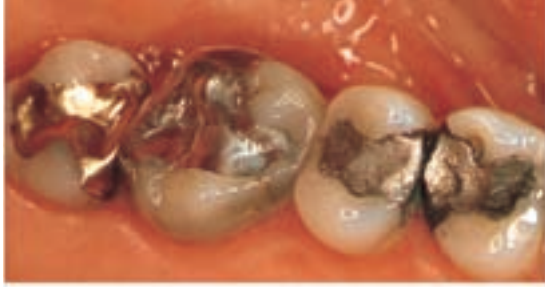*b* a gold inlay with cuspal protection or a glass ionomer/composite layered restoration to strengthen the cusps;



*c* a composite core or a bonded or pin-retained amalgam core and partial crown;

*d* a composite core or a bonded or pin-retained amalgam core and complete crown.



**Figure 1.13**

Amalgam and gold restorations.

The amalgam in the first molar, which has just been repolished, has been in place for 15 years. Less than half the natural crown is present and so a crown could have been considered when the treatment was first planned. The decision to place an amalgam was justified. The amalgam restorations in the premolar teeth are more recent, and less satisfactory. The inlay in the second molar has been present for 20 years.

to the etched enamel, marginal breakdown is less common. Porcelain veneers require two bonds, one to enamel and the other to the porcelain.

Taking all these considerations together the emphasis is now swinging towards composite veneers rather than porcelain. However, porcelain veneers still have an important role to play in some cases.

### ***An alternative to porcelain veneers – resin bonded ceramic crowns***

These are, in effect, a porcelain veneer that goes right round the tooth and therefore does not have the same problems with the differences in physical properties between porcelain and enamel as do porcelain veneers. They require the same amount of labial, incisal and approximal preparation as a porcelain veneer, usually entirely in enamel, together with equivalent preparation of the palatal or lingual surface (Figure 1.11).

### ***Restoration of badly broken-down teeth***

The most common indication for a posterior crown is a badly broken-down tooth usually resulting from repeated restorations, each of which fails in turn until finally a cusp or larger part of the tooth fractures off. In most cases it is necessary to build up a core of amalgam or composite before the crown is made. Two such teeth are shown in Figure 1.12c and d.

### ***Restoration of root-filled teeth***

There is a strong clinical impression and some scientific evidence that root-filled teeth are more likely to fracture than teeth with vital pulps. It follows that some thin and undermined cusps of root-filled teeth need to be protected or removed where similar cusps in vital teeth would be left. Together with the original damage that necessitated the root filling and the access cavity, this means that many, but by no means all, root-filled posterior teeth are crowned. The fact that a posterior tooth is root-filled is not in itself sufficient justification for a crown. When a crown is indicated it is almost always necessary to make a core.

### ***As part of another restoration***

In Parts 2 and 3 partial and complete crowns are discussed as retainers for bridges and fixed splints. In addition, they may be indicated in conjunction with conventional or precision-attachment retained partial dentures.

### ***What are the alternatives to posterior crowns?***

#### ***Bonded or pin-retained amalgam restorations***

The success of bonding amalgam to large unretentive cavities is improving. Some dentists now use bonded amalgam routinely while others are less



confident of the bond (and find the technique difficult) and use pins or a combination.

Figure 1.13 shows an amalgam restoration which has been present for 15 years. A crack is visible on the mesial palatal aspect of this tooth; this has also been present for some years. The tooth is symptomless and remains vital. It could be argued that all teeth with large lesions, such as this one, should be crowned in order to prevent such cracks occurring. However, it is impossible to predict which teeth will crack and what the effects will be. It is therefore not justified to crown all teeth with large cavities or restorations just as a preventive measure. To do so is overtreatment and is not cost-effective. It is better to apply a general policy of minimum intervention, with prophylactic restorations only when there is a clear risk of failure. When occasional failures, such as broken cusps, do occur, these problems can usually be solved without the need for extraction.

### **Tooth-coloured posterior restorations**

Composite materials suitable for posterior restorations have been developed intensively in recent times. One reason for this is increasing anxiety in some parts of the world and in some patients about the wisdom of continuing to use amalgam restorations in view of the possible risk of mercury toxicity or allergy. The subject has received much attention in the popular press and in the rest of the media. The scientific evidence is that mercury allergy does exist in a very small proportion of the population, although in some parts of the world, for example Japan, it appears to be greater, probably due to patients being sensitized by eating fish contaminated with mercury that has got into the marine food chain.

Mercury toxicity is a proper concern of dentists, and over the last 30 years or so considerable improvements have been made in mercury hygiene. Most amalgam used now is capsulated, avoiding the need for liquid mercury to be available in bulk in the dental surgery, and other precautions are also used to protect the staff in the dental surgery. It is the staff, who are likely to be exposed over a long period to mercury vapour should mercury hygiene not be adequate, who are at risk rather than individual patients. There is no reliable scientific evidence that the mercury from amalgam restorations is a serious

toxic hazard to patients, despite occasional flurries of media hype. It is also possible that the alternatives to amalgam may have equally low levels of toxic effect.

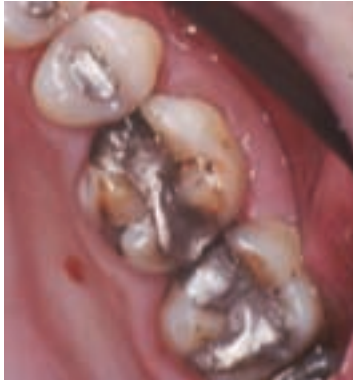Nevertheless there are some patients who refuse to have amalgam restorations, and hence there has been a drive to develop satisfactory, cost-effective alternatives for the restoration of posterior teeth. Some patients also have concerns about the appearance of amalgam restorations, even in areas of the mouth that show little, and request tooth-coloured restorations. The materials are improving year by year, but some dentists still feel that they are not yet comparable to amalgam for the larger posterior restoration. These dentists will therefore more commonly prescribe crowns than composite restorations in teeth that would otherwise be treated with an amalgam restoration, for example the tooth shown in Figure 1.12a. The tooth shown in Figure 1.12b still has substantial buccal and palatal cusps and a good ridge of dentine between them. However, if the tooth is subject to occlusal stress (and wear facets can be seen on the cusps) then a restoration either protecting or reinforcing the cusps is indicated with this amount of tooth loss.

There is good evidence that the layered restoration (a core of glass ionomer cement replacing the dentine, with an occlusal surface of composite replacing the enamel) is successful in binding weakened cusps together and producing a stronger tooth than one restored with amalgam alone. It is used when there is a large MOD cavity where a crown preparation would simply remove all or most of the remaining tooth tissue.

In order to increase wear resistance and to minimize the effects of polymerization contractions, which are complications of large directly placed composite restorations, systems have been developed to process composite inlays outside the mouth by a combination of heat, pressure and light. A non-undercut inlay cavity is prepared, an impression taken and the composite inlay (or onlay) made in the laboratory (Figure 1.14).

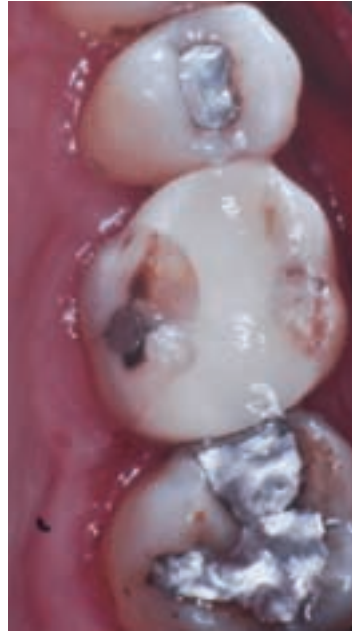### **Gold inlays and onlays protecting weak cusps**

The gold inlay shown in Figure 1.13 is an intracoronal restoration and is not an alternative to a crown. Figure 1.15a shows a tooth similar to

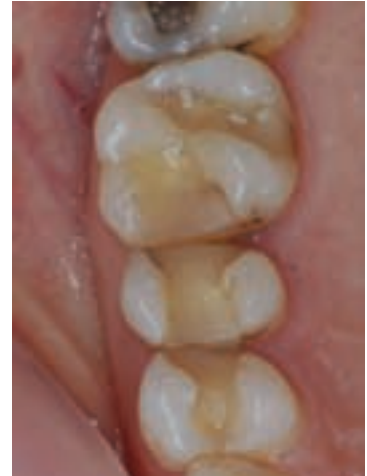

**Figure I.14**

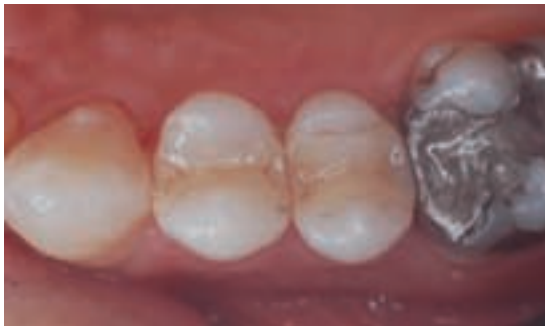a The large MOD amalgam restoration in the first molar tooth requires replacement.



b The restoration has been replaced with a direct composite restoration, significantly improving its appearance.



c Several extensive restorations in composite only 2 years after placement. They have worn badly with marginal staining, loss of occlusal contour and poor proximal contacts.

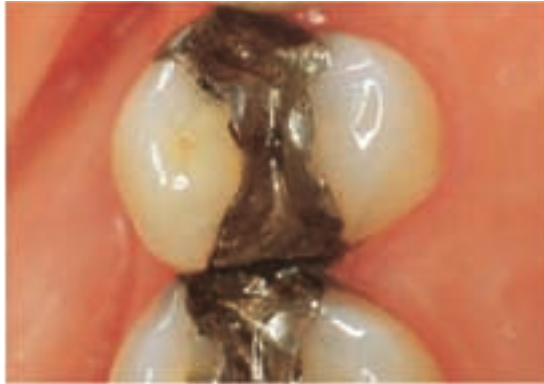

d Well placed MOD composite restorations which are 5 years old and continue to function well with a good appearance.

*continued*

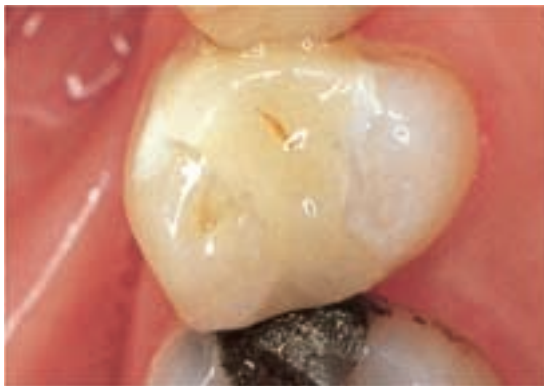Figure I.12b. It has been prepared for a cuspal coverage MOD gold inlay and Figure I.15b shows the sectioned tooth with a wax pattern for the inlay. The metal overlying and protecting the cusps must be thick enough to prevent distortion under occlusal forces.

This restoration is very conservative of tooth tissue and is retentive. Imagine on Figure I.15 how little of the buccal cusp would have remained had the tooth been restored with a core and then prepared for a metal-ceramic crown (see Chapter 2). The buccal cusp would have been

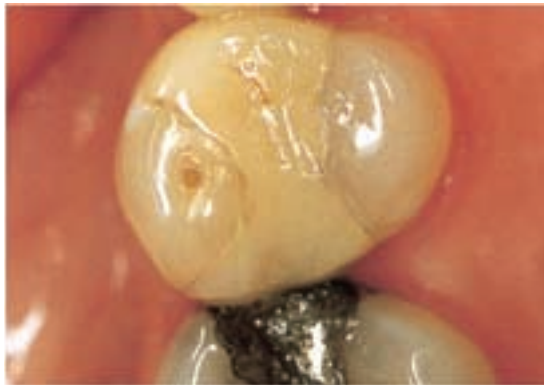

**Figure 1.14** *continued*

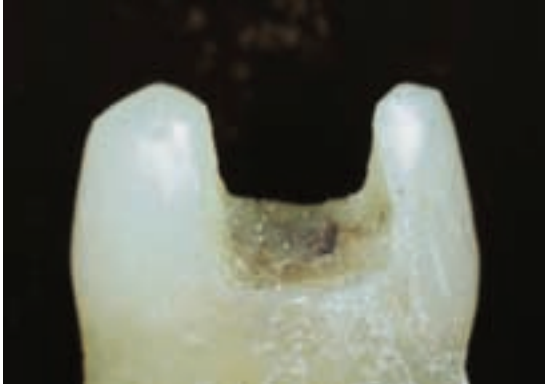e A failed MOD amalgam restoration with secondary caries beneath both the boxes. The mesial surface of the amalgam was also unsightly.



f A laboratory-processed composite inlay shortly after insertion.



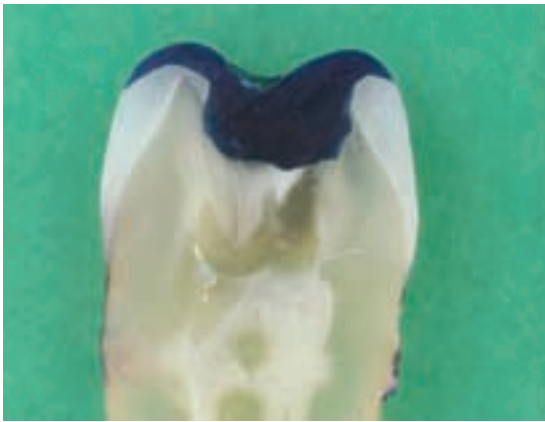
g The same composite inlay after 8 years.



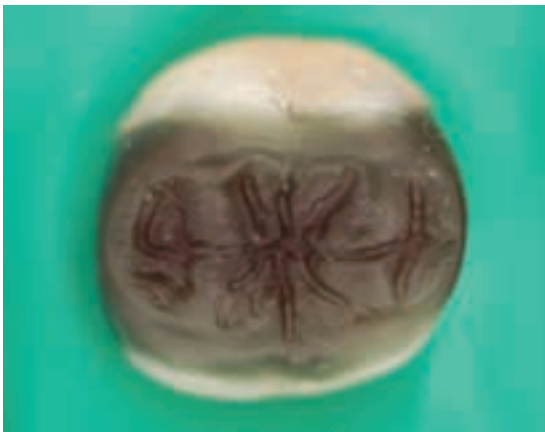**Figure 1.15**

MOD cuspal coverage inlay.

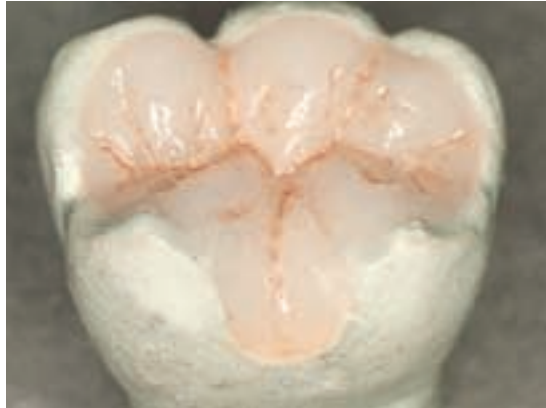*a* The prepared tooth. Note the bevels on the occlusal surface just down onto the buccal and lingual surfaces.



*b* Section of the prepared tooth with the wax pattern.



*c* Occlusal view of the completed wax-up.

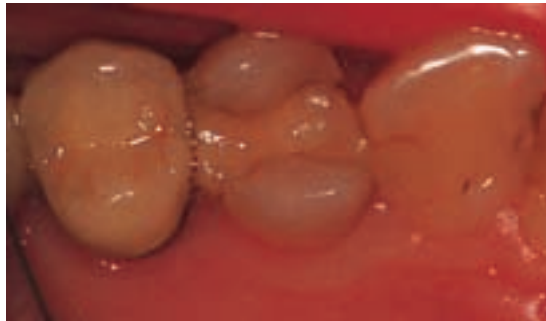
**Figure 1.16**

Ceramic inlays.

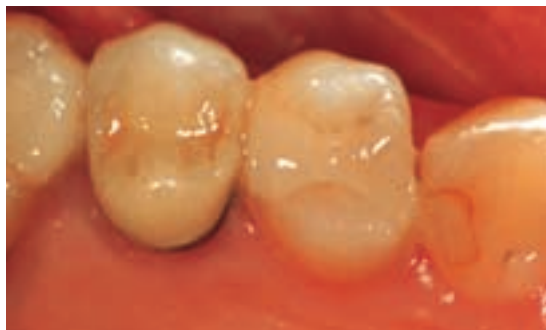*a* A laboratory-made ceramic inlay. The inlay is returned from the laboratory with a contoured occlusal surface and occlusal staining. It should only require cementation.



*b* A computer aided design/computer aided manufacture (CAD/CAM) machine for producing ceramic inlays at the chair side. This is an early version of the Cerec machine but there are several other makes available.



*c* A failed composite restoration in the first premolar tooth is to be replaced by a ceramic inlay.



*d* The completed ceramic inlay milled at the chair side in the Cerec machine. The machine produces a good fit and contact points that only require minor adjustment and polishing. However, the occlusal surface is not finished, and needs to be adjusted and polished in the mouth after cementation. The main advantage of the system is that the whole procedure is carried out in one visit at the chair side and there are no laboratory stages.

even more weakened. A disadvantage of this type of restoration is that often with premolars and some molar teeth there is a visible display of gold, which some patients do not like.

### **Ceramic inlays and onlays**

Posterior ceramic inlays have many of the advantages of posterior composite restorations in that, because they are bonded to the tooth, they strengthen weakened cusps, and they are tooth-coloured. In addition, the porcelain occlusal surface is more wear-resistant than composite and there is, of course, no polymerization contraction.

There are two systems: one that includes a laboratory stage and one that does not. With laboratory-made ceramic inlays, an impression of the prepared tooth is sent to the laboratory and a porcelain inlay is made by one of a variety of techniques similar to the production of porcelain crowns using the die of the tooth (Figure 1.16a).

The chair-side system consists in milling a porcelain inlay from a design produced in a computer from a three-dimensional video image of the prepared tooth. This, of course, requires a very complex, sophisticated and expensive piece of equipment (Figure 1.16b). It is too soon to say whether this approach to dental restorations (CAD/CAM or computer-aided design/computer aided manufacture) will be revolutionary or will stay on the fringes of dental treatment.

### **Choosing the right posterior restoration**

In some of the teeth shown in Figure 1.12 the failure is due to the restoration fracturing or becoming lost and in others it is the tooth itself that has failed. In some the problem is secondary caries. In all these cases decisions must be made between restoring or extracting the tooth, and if it is to be restored, whether the pulp is healthy or whether endodontic treatment is necessary. Leaving these considerations to be discussed in Chapter 3, and assuming that all these teeth will be restored, the next decision is whether the appropriate restoration is:

- An amalgam or composite restoration
- A layered restoration of glass ionomer and composite
- An amalgam with additional retention (for example bonding or pins)
- A ceramic or composite inlay
- A gold inlay
- A gold inlay with occlusal protection (an onlay)
- A partial crown
- A complete crown
- A core of material to replace the missing dentine followed by a partial crown
- A core and complete crown.

A further decision that must be made is whether, if a complete crown is to be used, it should be an all-metal or a metal-ceramic crown, or even in some cases an all-ceramic crown (see Chapter 2 for a description of these different types of crown).

These decisions cannot be made without further information, and some of this will be gathered from the history, examination of the rest of the mouth, radiographs, and so on (again, these matters will be discussed in Chapter 3). However, even with all this information it is usually also necessary to remove the existing restorations and caries before a final decision can be made. Figure 1.12 shows the same teeth before and after the caries and old restorations are removed.

The decision depends upon three factors:

- Appearance
- Problems of retention
- Problems of strength of the remaining tooth tissue and the restorative material.

As far as appearance is concerned, if the surface of the tooth to be restored is visible during common movements of the mouth, and if the patient is concerned about appearance, a ceramic inlay, composite restoration or crown will usually be indicated for large restorations.

When the problem is simply one of retention, an amalgam restoration with additional retentive features is usually chosen (Figure 1.12a).

When the remaining tooth tissue is weak, a layered restoration, a ceramic inlay or a cuspal coverage gold inlay will be the choice (Figure 1.12a).

A core and partial crown is a very satisfactory restoration where a tooth previously restored

with an MOD amalgam loses its lingual or palatal cusp. The partial crown protects the remaining buccal cusp against occlusal forces, and this cusp can still provide valuable retention, often in conjunction with bonding and/or pins, for the core, as well as having an acceptable appearance. If a metal–ceramic crown is made, then the whole or the majority of the buccal cusp will be cut off in the preparation of the tooth, and the core will need much more substantial auxiliary retention (Figure 1.12c).

A core and complete crown is the last resort. Figure 1.12d shows a case where there is no choice but to provide a core and complete crown.

These examples illustrate the importance of considering all the alternatives in each case. The temptation to look rather casually at the tooth and immediately decide upon a crown without proper investigation and consideration must be avoided as it may lead to more destructive over-treatment than necessary.

## 2

## Types of crown

This chapter gives a general description of the various crown types together with their main advantages and disadvantages in relation to:

- Physical properties
- Clinical considerations
- Appearance
- Cost.

Crowns are described under the following headings:

- Anterior complete crowns for vital teeth
- Anterior crowns for root-filled teeth
- Posterior complete crowns
- Posterior partial crowns.

### Anterior complete crowns for vital teeth

In the anterior part of the mouth appearance is of overriding importance, and so the only types of crown to be considered are those with a tooth-coloured labial or buccal surface. These fall into three groups:

- Ceramic crowns
- Metal-ceramic crowns
- Other types of crowns.

### Ceramic crowns

In recent years there have been several developments in the ceramics used for crowns. These can be classified as:

- Traditional fused porcelain jacket crowns (PJC's)
- Pressed ceramic crowns
- Milled ceramic crowns
- Cast crowns

- Reinforced crowns
- Ceramic resin bonded crowns.

### Traditional porcelain jacket crowns (PJC's)

This is the oldest type of tooth-coloured crown and has been in use for more than a century. It consists of a more or less even layer of porcelain, usually between 1 and 2 mm thick, covering the entire tooth. Figure 2.1a, b, c and d shows a selection of traditional feldspathic porcelain jacket crowns in place.

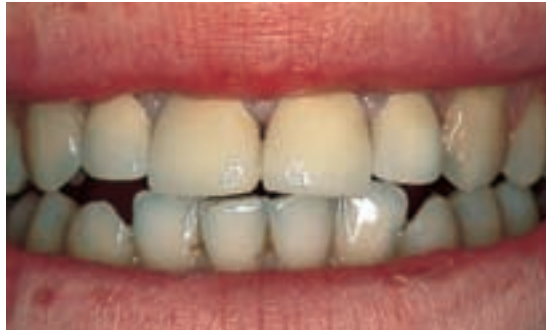The traditional feldspathic PJC is made by adapting a very thin platinum foil to a die made from an impression of the prepared tooth. Porcelain powder, mixed with water or a special fluid, is built onto the platinum foil and fired in the furnace. All PJC's made in this way are now strengthened by having alumina incorporated into the porcelain powder. A core of high-alumina porcelain is fired onto the platinum foil. This high-alumina core is opaque and needs to be covered by more translucent porcelain that contains less alumina.

Variations on fused ceramic crowns have been developed but most have now been replaced by the systems described later. Examples of these strengthened ceramic systems were Hi-Ceram (Figure 2.1e) and In-Ceram (Figure 2.1i).

An alternative approach is to fire an extra-strong core of ceramic material to a refractory die and then add further layers of conventional feldspathic porcelain. Once finished, the refractory die is grit-blasted away, leaving a fitting surface that is slightly rough, aiding retention. Both these systems can also be used to make porcelain veneers.

Conventional dental porcelain is physically more like glass than the porcelain used for domestic purposes. It is relatively brittle, and before a PJC is cemented it can be broken fairly easily. However, once it is cemented and supported by the dentine of the tooth, the force required to fracture it is of the same order of

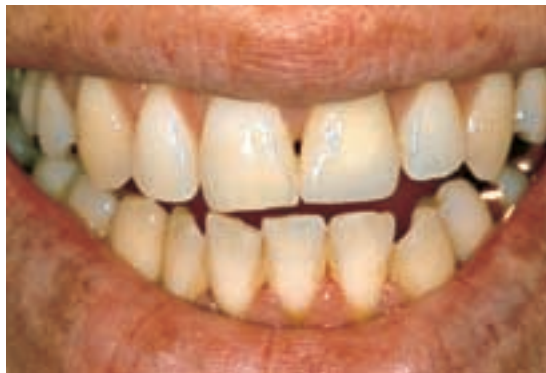



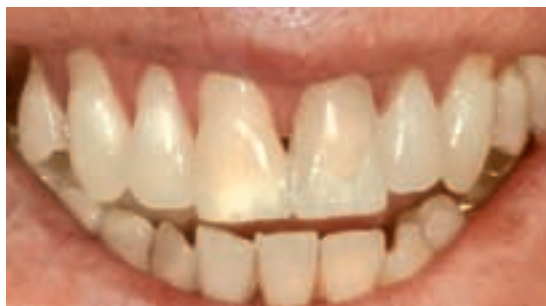**Figure 2.1**

Types of anterior crown.

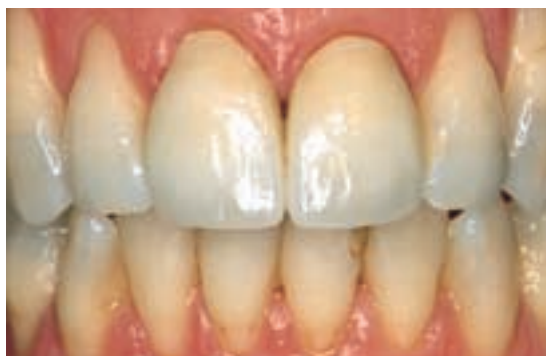*a* Traditional porcelain jacket crowns on all four upper incisors. The preparations for the crowns are shown in Figure 6.10.



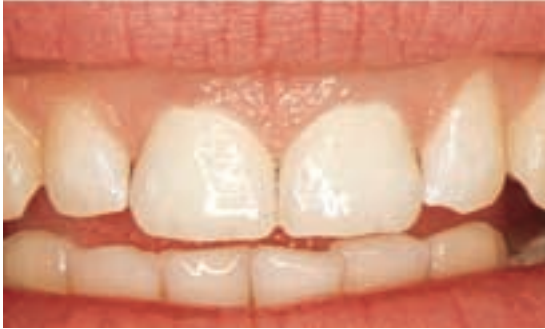*b* A single traditional PJC. The upper left central incisor is the crown, the other teeth are natural.



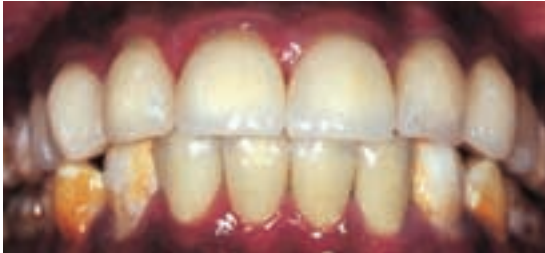*c* The same crown 25 years later. It has recently been fractured traumatically and repaired with composite. The appearance is not as good as the original crown but the patient is happy to accept this and does not want the crown, which has been so successful, replaced yet.



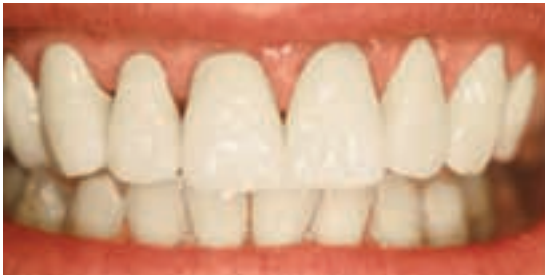*d* Both upper central incisors are traditional PJCs with supragingival margins. Despite this, there is some gingival inflammation. They had been present for about 5 years when this photograph was taken.



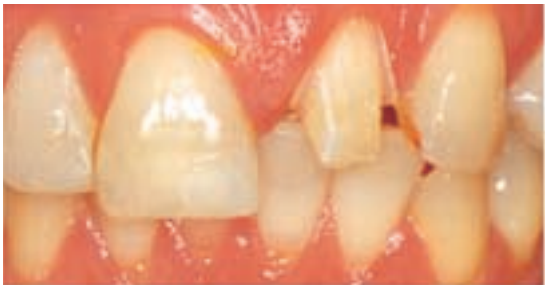e Strengthened porcelain crowns (Hi-Ceram) on both central incisor teeth.



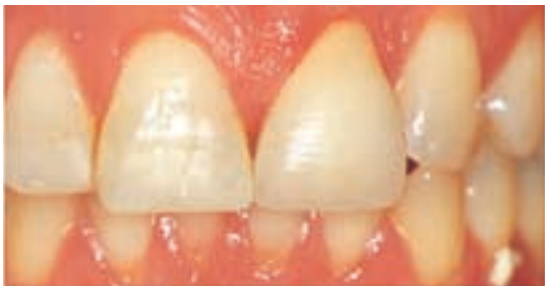f Pressed crowns on the upper and lower incisor teeth in a patient with mild amelogenesis imperfecta. This can be seen on the uncrowned teeth, particularly the lower right first premolar. The system used was Empress.

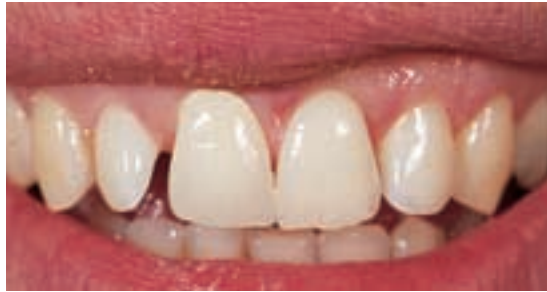

g Six pressed crowns made by another system – Metalor Stylepress – in which both the pressed and applied layers are the same material.

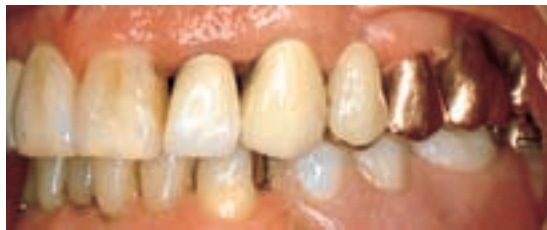

h and i The upper left lateral incisor tooth has been moved orthodontically into the position of the central incisor and crowned with an infiltrated, reinforced system (Inceram) to resemble the missing central incisor.





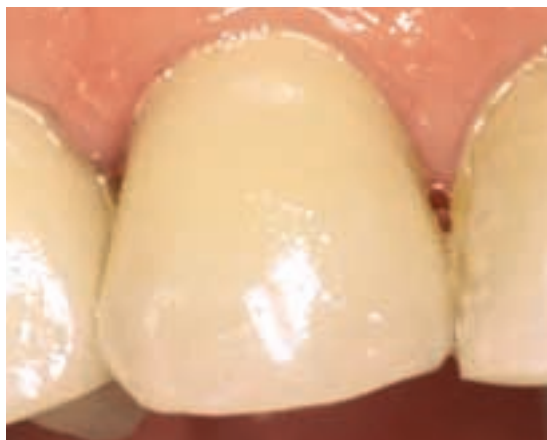*j* A cast ceramic crown (Dicor) on the upper right central incisor.



*k* A metal-ceramic crown on the upper lateral incisor. This is the patient shown in Figure 1.1a.



*l* A metal-ceramic crown with a buccal porcelain margin so that no metal is visible on the labial surface.



*m* The cemented crown shown in *l* has an excellent appearance and is indistinguishable from a porcelain crown.

magnitude as the force required to fracture the enamel of a natural tooth.

However, traditional PJs do fracture and so the other systems have all been developed to produce stronger all-ceramic crowns.

### Pressed ceramic crowns

There are a number of systems used to produce a strong ceramic core by pressing a ceramic material at high temperature and pressure onto a die and then building up layers of traditional porcelain to create the right contour and shade. Examples of crowns made by this process are shown in Figure 2.1f and g and an example of the equipment used is shown in Figure 2.2a.

### Laboratory milled cores and crowns

Several computer aided designs/computer aided manufacture (CAD-CAM) have been developed and more are in the pipeline. One example is a technique by which the die is scanned in a computer and the digital record is sent electronically to a central laboratory, often in another country, where a core is produced in a strong ceramic material. This is then returned to the original laboratory where additional porcelain is added to complete the crown. The system can also mill metal, in particular titanium (Procera). The computer equipment is shown in Figure 2.2d and crowns made by this process are shown in Figure 2.2e and f.

### Zirconia cores

Porcelain crowns can also be manufactured using complex laboratory techniques with a zirconia core onto which conventional porcelain is built. Zirconia is an extremely strong material comparable to metal and is dense white in appearance. The conventional porcelain therefore needs to be relatively thick for the translucent porcelain to mask the opaque core underneath. Zirconia-based crowns are proposed by the manufacturers for use on posterior as well as anterior teeth due to their great potential strength, but there is not yet sufficient evidence that they will survive for the long term in high stress situations.

### Chair-side milled restorations

Chair-side milling systems have been in development for some years. Although these systems do not yet produce reliable crowns it is anticipated that they will do so in the foreseeable future.

### Cast ceramic systems

One of the earliest developments in the 1970s was of a system to produce strong ceramic crowns by the Dicor process in which a wax pattern of the crown was made on a conventional die, invested and cast in a glass/ceramic material. The casting was then placed in a ceramming oven for several hours, during which it went through a crystallization conversion and became much stronger. At this stage the casting had a cloudy-clear appearance (similar to frosted glass). It was then stained and characterized using conventional feldspathic porcelains in a porcelain furnace. Although the commercially available Dicor system was developed by the same company that developed domestic Pyrex glassware, the manufacturers state that the material is not the same as Pyrex. A number of other castable ceramic or hot transfer-moulded glass ceramic systems have been developed (Figure 2.1j).

### Reinforced porcelains

One technique is to form an alumina substructure on a special plaster die and following sintering in a furnace the porous substructure is coated with glass fired powder and further fired for several hours. This infiltrates the pores and eliminates them as a source of weakness. Filling the pores also improves translucency and the final appearance when additional porcelain is added. A typical system is In-Ceram and an example is illustrated in Figure 2.1h and i.

### Thin ceramic resin bonded crowns (see also Chapter 1)

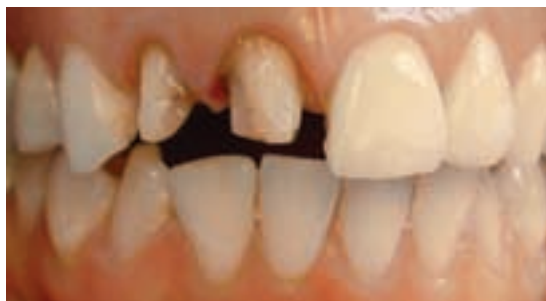All the previous crowns are usually cemented by conventional means (see later). However, a conservative technique is to prepare the tooth within enamel exposing the minimum amount of dentine and then making thin ceramic crowns, no



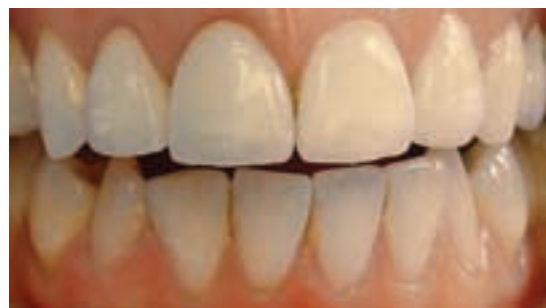**Figure 2.2**

Making pressed, milled and fibre re-inforced crowns.

*a* Equipment for construction of an Empress crown.




*b* and *c* Two Empress crowns restoring severely damaged incisor teeth.

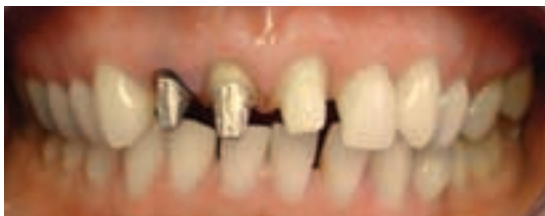



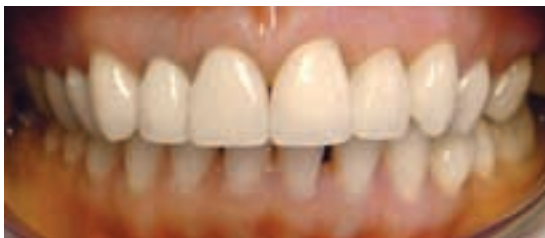d The scanner used in the process of making a Procera crown.



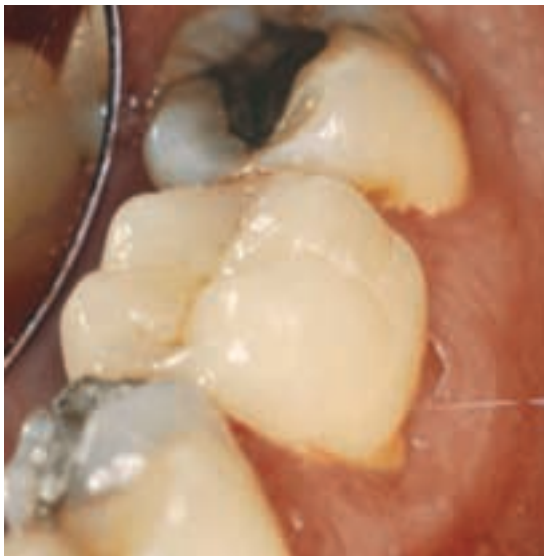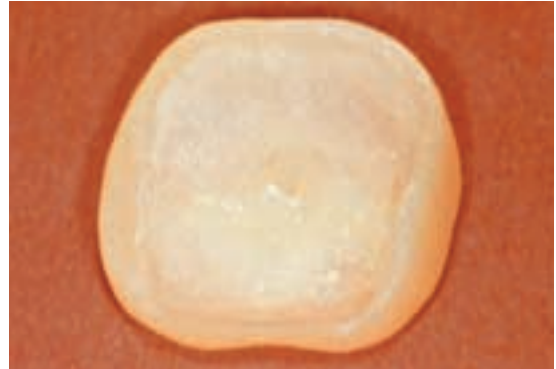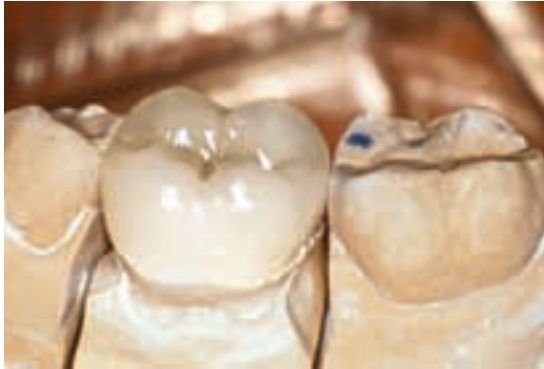e A Procera core of dense aluminous porcelain ready. The porcelain will be fired directly onto this.



f and g Procera crowns restoring three incisor teeth. Note how the crowns disguise the gold post and cores so the appearance is the same as the crown on the natural tooth.



*continued*



**Figure 2.2** continued

*h, i and j* A single molar crown made using a fibre reinforced system.

thicker than a porcelain veneer (see later) but covering the whole tooth. This is then bonded by etching the enamel surface, grit-blasting the fit surface of the crown and bonding with an adhesive resin material (Figure 1.11). These restorations are becoming more popular with some dentists, who believe that their prognosis may be better than ceramic veneers because they go right round the tooth, thereby reducing the effects of the difference in thermal expansion between porcelain and enamel, and also the risk of marginal leakage and staining is reduced.

### **Choosing between ceramic crowns**

In this fast developing field, a list of current (at the time of publication) materials and techniques would soon become out of date. Instead, when dentists look at an established or new system they should recognise which type it is and assess the manufacturer's descriptions and claims objectively. Not all dentists or technicians will use the full range. Most dentists gain experience in a limited range and choose the appropriate system for the patient's particular clinical circumstances.

## Advantages

The advantages of ceramic crowns are:

**Appearance** Because of their translucency and the range of techniques and shades available, they are better able to duplicate the appearance of a natural tooth than any other type of crown.

**Stability** Porcelain is dimensionally and colour stable and is insoluble in oral fluids.

**Cost** Some ceramic crowns are less expensive to produce in the laboratory than metal–ceramic crowns.

**Plaque** Ceramic materials resist plaque accumulation better than other crown materials.

**Brittleness** The relative brittleness of a conventional PJC can be regarded as an advantage, particularly if the tooth being crowned was originally fractured in an accident. Should such an accident recur (which is not at all uncommon among sports players, cyclists, children with Class II Division I incisor relationships, and others), the PJC is likely to fracture rather than the root of the tooth. This is still true, but to a lesser extent, with the newer types of ceramic crown. With metal–ceramic crowns, which are stronger than the remaining tooth tissue, more serious damage such as root fracture is likely to result from a further accident. Where possible, the weakest link in the chain should be the one easiest to repair. The principle is similar to the fuse in an electric circuit.

## Disadvantages

The disadvantages of ceramic crowns are:

**Marginal fit** Traditional porcelain jacket crowns made on a platinum foil matrix that is removed prior to cementation often had a less satisfactory marginal fit than cast metal and other crowns. However, the marginal fit of the newer types is comparable to cast-metal restorations; if shoulder porcelain (see later) is used the fit is improved.

**Brittleness** Although the brittleness of porcelain crowns was described earlier as a potential

advantage in some situations, in most it is a disadvantage. In some patients where the crown supports a partial denture or where the occlusal forces are excessive, ceramic crowns are not usually used.

**Removal of tooth tissue** To overcome the problem of the brittleness of porcelain, and to give the crown a natural appearance, there must be an adequate thickness of material, and so it is necessary to reduce the tooth fairly extensively, weakening it and threatening the pulp. This is especially true with small teeth, for example lower incisors. This problem is much less with resin bonded ceramic crowns.

## Metal–ceramic crowns (Figure 2.1k and l)

Dental porcelain can be bonded to a variety of metal alloys. The process is similar to the glazing of domestic cast iron and steel baths and basins. The alloys used in dentistry fall into three groups:

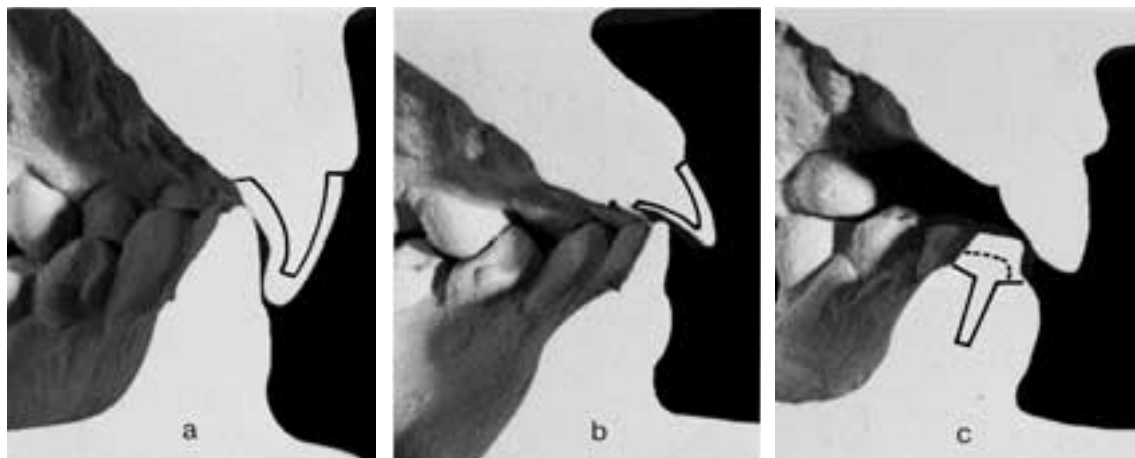
- Precious metal alloys containing a high proportion of platinum and gold. These can be high or low gold content (75% down to 25% gold)
- Semi-precious alloys containing a high proportion of palladium, sometimes with silver as well
- Base metal alloys containing a high proportion of nickel and chromium.

Although this classification is still used, at the time of writing palladium is more expensive than gold and so the term ‘semi-precious’ is not really accurate. Base metal alloys should only be used in patients with a confirmed tolerance of nickel as it is fairly common for patients to be sensitive to cheap jewellery or coins containing nickel.

There is a difference in cost between these alloys, but they all share the properties of a high melting temperature so that porcelain can be bonded to the surface. This is done by firing the porcelain to the metal at a temperature which does not melt or distort the metal.

The preparation for an anterior metal–ceramic crown differs from that for a posterior metal–ceramic crown in two ways; first rather more tooth tissue needs to be removed from the labial surface to allow for the thickness of the





metal as well as porcelain, and second rather less usually needs to be removed from the palatal or lingual surface since only metal will usually cover at least part of this surface.

### Advantages

The main advantages of metal–ceramic anterior crowns are:

**Strength** The metal–ceramic crown is a very strong restoration, which resists occlusal and other forces well.

**Minimum palatal reduction** Some teeth, particularly those severely worn by erosion and attrition that have then over-erupted back into occlusion, may not be sufficiently bulky for a porcelain jacket crown preparation with adequate palatal reduction, whereas a metal–ceramic crown preparation may be possible. Figure 2.3 illustrates this problem in comparison with a normal incisor tooth.

**Adaptability** The metal–ceramic crown can be adapted to any shape of tooth preparation, whereas the processes involved in making ceramic crowns require a smooth and uniform preparation. Additional retention can be gained in difficult preparations by the use of grooves or pins, which is not possible with ceramic crowns.

**Figure 2.3**

Sections through three sets of casts of patients in intercuspal position showing the profile of crown preparation.

*a* This is a Class I Division II incisor relationship with deep overbite and minimal overjet. It often appears, when looking at these patients from in front, that there will be insufficient clearance for ceramic crown preparations. In fact, the bucco-lingual thickness of the teeth is often normal and conventional preparations are possible.

*b* Gross erosion of the palatal surfaces of the upper incisor teeth due to recurrent vomiting. If crowns are to be made, there will not be room to provide a palatal porcelain surface without the occlusal vertical dimension being increased by techniques described later. However a metal–ceramic crown preparation is possible. Because the diagnosis is erosion (chemical damage) rather than attrition (physical damage), the additional strength of the metal is not particularly important.

*c* The lower incisors are worn to approximately one-half their original length. A conventional crown preparation would not be possible but a one-piece metal–ceramic post-retained crown is. The dotted line shows the metal–porcelain junction.

**Can be cast, soldered or laser welded** For bridges, metal–ceramic crowns can be attached to other crowns or bridge pontics by casting them together, soldering or laser welding. This cannot be done with ceramic crowns.

## Disadvantages

The disadvantages of metal–ceramic crowns are:

**Strength** An accidental blow may result in the tooth preparation or root fracturing because the crown is stronger than the natural dental tissues.

**Appearance** Because of the metal framework, it is sometimes more difficult to match the natural appearance of a tooth than with a ceramic crown, particularly at the cervical margin (Figure 2.1k). However, with all-ceramic margins this can be largely overcome.

**Destruction of tooth tissue** Metal–ceramic crowns require more tooth reduction labially than ceramic crowns and so the tooth preparation is more likely to endanger the pulp. If this tooth reduction is not sufficient – as is often the case – the eventual crown either has a poor, opaque appearance or is too bulky (see Chapter 3).

**Cost** Even if the relatively inexpensive base metal alloys are used, the laboratory time taken to construct a metal–ceramic crown is more than for a PJC and therefore the overall cost is usually greater. However, when compared to the costs for most of the other types of ceramic crown involving complex laboratory stages, the costs are similar. When precious metal alloys are used, the cost is naturally greater.

## Other types of anterior complete crowns

Although the majority of anterior crowns fall into one of the two previous groups, other alternatives exist:

- Cast metal crowns with acrylic or composite facings

- Fibre-reinforced composite crowns.

## Cast metal acrylic or composite faced crowns

These are mostly used as long-term provisional restorations. Laboratory-grade composite is cured by an intense light in a special light box, sometimes with the addition of heat or pressure. The cast metal framework needs to be mechanically retentive for the facing.

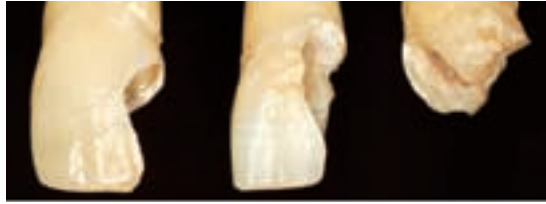## Fibre-reinforced composite crowns

A range of techniques have been developed to reinforce composite as a permanent crown material. However, after a few years in use, the results have been disappointing. Nevertheless, they do make good long-term provisional crowns and bridges. The techniques require a light box in the laboratory but this is less expensive and the process is quicker than firing porcelain. Figure 2.2h, i and j shows an example of this type of crown.

## Anterior crowns for root-filled teeth

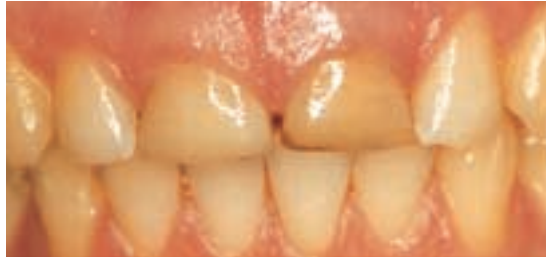Often the endodontic access cavity together with the crown preparation will leave insufficient dentine to support a crown. In this case retention is gained by means of a post fitted into the enlarged root canal. These posts are used only for retention, and the idea that they add strength to the tooth has now been discounted. For this reason, if it is possible to obtain retention for the crown without using a post, this is preferred. Figure 2.4a shows examples of teeth that would be restored by means of a simple composite restoration, a composite (or glass ionomer) core and crown or a post-retained crown. There are four groups of crowns for root-filled anterior teeth:

- Composite (or glass ionomer) core and crown
- Post and core and separate crown
- One-piece post crown
- Other types.

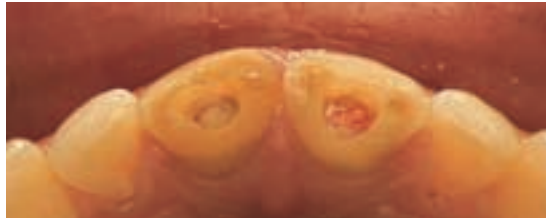**Figure 2.4**

Treatment of anterior root-filled teeth.

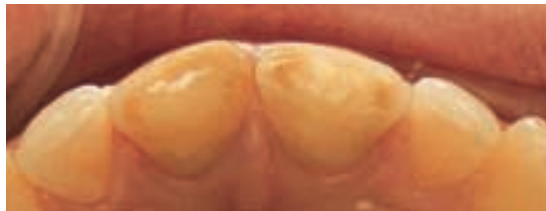*a* If these three teeth had not been extracted, they would have had to be root-filled. The caries and old restorations have been removed. The left-hand tooth could be restored by a simple composite restoration, the centre tooth has sufficient dentine remaining for a glass ionomer cement or composite core followed by a crown to be satisfactory, but the right-hand tooth does not have sufficient dentine, and retention by means of a post cemented into the root canal is necessary.



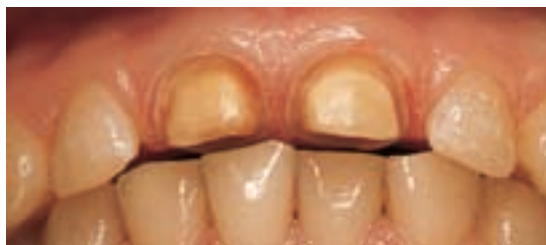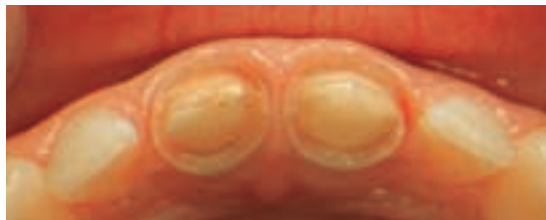*b* Both central incisors are fractured and have been root-filled.



*c* An incisal view of the teeth shown in *b* with the restorations removed from the access cavities.



*d* The access cavities restored with glass ionomer cement.



*e* and *f* The teeth prepared for ceramic crowns. The completed crowns are shown in Figure 2.1e.

### **Composite (or glass ionomer) core and crown**

When sufficient dentine remains, the endodontic access cavity can be filled and the missing dentine replaced with glass ionomer cement, which bonds directly to dentine. Alternatively, dentine bonding agents may be used to bond composite to the dentine.

Glass ionomer cement has the advantage that it does not contract significantly on setting. Composite is stronger and is rather easier to prepare, since it cuts with a similar 'feel' to dentine (Figure 2.4b, c, d and f).

### **Post and core and separate crown**

The crown will be either a ceramic or metal-ceramic crown as described previously.

Posts and cores may either be made in the laboratory from an impression of the post hole (indirect posts) or ready-made posts can be purchased and cemented into the post hole which is prepared with a matching drill of the same diameter as the post (direct posts). With an indirect post, the core (and sometimes a diaphragm) is usually cast with the post. With a direct post a composite core is built up directly onto it in the mouth after the post is cemented.

Direct posts have the advantage of normally being fitted at the same time as the tooth is prepared, thus avoiding the need for a temporary post crown. They are usually stronger and can be much more retentive than the laboratory-made posts and cores. There is evidence that the temporary cement used to cement temporary crowns can contaminate the walls of the post hole and reduce the retention of the permanent post.

When the clinical conditions are suitable direct posts are preferred to indirect for the reasons set out later.

Laboratory-made posts have the advantage of adaptability and can be used in very tapered root canals that have suffered caries in the coronal part of the root canal, in root canals with an oval cross-section, and in two rooted teeth where the roots are parallel.

Direct posts are available in precious metal, non-precious metals, carbon-fibre, quartz-fibre or

titanium. Some of the advantages and disadvantages of these are:

- Precious metal: These can have a gold core and diaphragm cast onto them and are stronger than a cast gold post. Unless a diaphragm is needed they have little advantage over non-precious posts.
- Non-precious metal: These are the most commonly used and are usually stainless-steel. They are stronger for the same cross-section than cast posts and so a smaller diameter post hole is needed, leaving more root dentine. They are available from several manufacturers and in a wide range of diameters.
- Carbon-fibre: These were the first of the fibre-based posts to be introduced and there has been more research on them than the other types. They have the advantage of being slightly flexible and so are a nearer match to root dentine. However, they are black and are difficult to disguise beneath a composite core and ceramic crown.
- Quartz-fibre: These are white and may have similar advantages to the carbon-fibre posts. However, they have only been available for a relatively short time with little research to support them. Some dentists are optimistic that they will prove to be a useful addition to the range of posts.
- Titanium: These have been available for even less time and little is known about their advantages and disadvantages at the time of writing.

Although it may take longer to fit a direct post and build up a core at the chair side than to take an impression for an indirect post, this can be done in one visit rather than two and so, overall, there is a saving of surgery time together with a saving of laboratory charges compared with indirect posts.

### **Post shapes**

There are four shapes of post (Figure 2.5):

- Parallel: smooth or serrated
- Tapered: smooth or serrated
- Parallel: threaded
- Tapered: threaded.



a



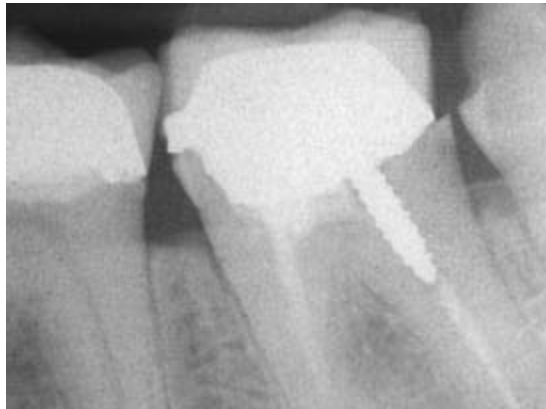
b



c



d



e

**Figure 2.5**

Post shapes.

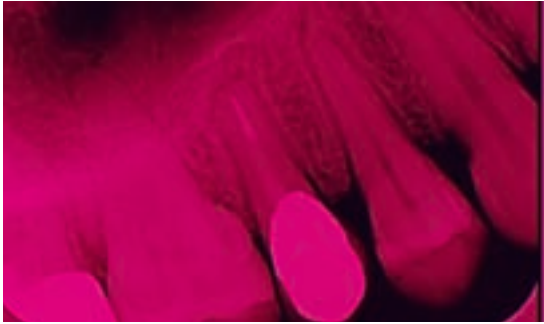a Cast gold post and core (tapered-smooth shape). The surface has been grit-blasted to improve retention.

b A parallel-sided, serrated post system. This manufacturer produces five diameters ranging from 0.9 to 1.75 mm. This is the middle of the range, 1.25 mm diameter. From the left: a twist drill with a rubber disc which can be moved up and down to set the length, a smooth plastic impression post, a stainless steel serrated post which can be used in the direct technique (see Chapter 6), an aluminium post with a small head used for making temporary post crowns and a serrated plastic burn-out post used in the laboratory as part of the pattern for the indirect system.


c A post system from a different manufacturer with the same five diameters. This is 1.5 mm diameter. From the left: the twist drill has three permanent marks to measure the length of the post hole, two impression posts (separated before use), serrated burn-out posts and a stainless steel post for use in the direct, chair-side technique.

d *Left:* A parallel, coarsely threaded post with attached head which will be prepared as the core after the post hole is threaded and the post is cemented. *Right:* a tapered, coarsely threaded post which is no longer recommended (see text).

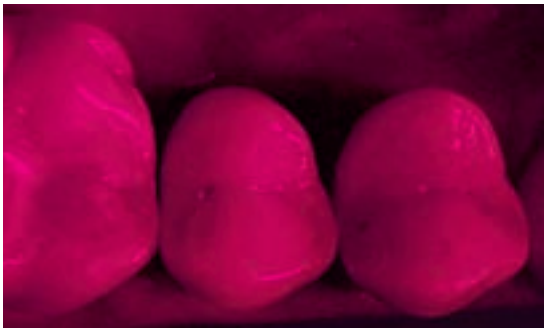
e Radiograph of a tapered-threaded (Dentatus) screw in the distal canal of a lower molar tooth. The crown needs to be replaced. On removal of the crown the post should be removed from the tooth by unscrewing it and it can be replaced with a new post of a different design.



f Radiograph of a quartz-fibre post in the second premolar tooth. Note that it is radiolucent and would be easy to miss.



g The same post in place with a composite core.



h The completed crown.

### Comparisons of post shapes

**Parallel: smooth or serrated** (Figure 2.5b and c)

- Either preformed metal to which a composite core is added, or made with a preformed plastic post, which is incorporated into a pattern for a cast post and core.
- More retentive than tapered-smooth posts, and serrations further increase retention.

- Greater risk of lateral perforation of the root (see Figure 6.15b).

### Tapered: smooth or serrated

- Laboratory-made in cast gold or other alloy.
- Least retentive design, but if long enough and a good fit, the retention is sufficient in most clinical circumstances (serrations increase retention but weaken the post).

- Easy to prepare and easy to follow the root canal.
- Similar to the shape of the root and therefore less likely to perforate through to the periodontal membrane.
- Adaptable technique and therefore can be used with oval, irregular-shaped or multiple-root canals.
- A diaphragm may be added to cover the root face and extended as a bevel around the margin. This reduces the risk of root fracture and may also replace areas of dentine lost through caries or trauma. This is the most common indication for a cast post.
- Cast posts are not as strong as direct posts, which are factory made and are strengthened by processes that are common in engineering.
- Cuts its own thread as it is inserted (like a wood screw) and therefore introduces considerable stresses into the dentine.
- Roots liable to split either as the post is being inserted or subsequently.
- Because of the difficulty of inserting without root fractures, retention is unreliable.
- Should not be used for permanent posts, but many were used in the past and their radiographic appearance should be recognised (Figure 2.5e). Removal is difficult and risks splitting the root.

### Choosing between post systems

Many successful posts of all types have been made, and although each dentist has his or her own preference, and certain sets of clinical circumstances dictate that one type or another is preferable, there is no one type that is uniformly superior to the others.

However, in most cases with sufficiently long roots where the coronal part of the root canal has not been excessively tapered, the first choice is usually either a preformed serrated or a cast parallel-serrated post.

A preformed post is preferable for single, uncomplicated crowns, since it avoids the need for a temporary post crown and also avoids the risk of a casting failure. A relatively common cause of such casting failures is porosity in the cast metal at the junction of the post and the core. As the metal cools, after being cast, it contracts and the more rapid cooling of the relatively thin post compared with the bulkier core can produce porosity at the junction between them. This porosity is within the casting and is not visible.

Cast parallel-serrated posts and cores are preferred when the core needs to be extended as a diaphragm to cover part or all of the root surface or when a stronger core is needed.

The next best choice is usually the tapered-smooth cast post and core, which is used when the root canal is particularly tapered or oval or when the root is very tapered so that there is a greater risk of lateral perforation.

Parallel coarsely threaded posts are used when the available root canal is very short due to an obstruction or when particularly robust retention is necessary. The technique for inserting them is

#### Parallel: threaded

There are two types:

- A very fine thread which can be self-tapped into the walls of a parallel-sided post hole. It is claimed that the threads are sufficiently fine as not to produce too much stress in the dentine and therefore risk fracture. The cemented post is very retentive.

And

- An older and now seldom used system with a much coarser thread. A thread is cut into the walls of the prepared root canal with an engineer's tap. The post is then cemented and screwed in with minimal force (like assembling a nut and bolt) so that stresses are not introduced into the dentine. Many patients had this type of post fitted and so it is important to recognise their radiographic appearance. Because of the very retentive thread, they cannot be removed by the techniques used to remove other types of post – see Chapter 14. Attempting to do so will almost invariably fracture the root (Figure 2.5d left).

#### Tapered-threaded (Figure 2.5d right)

- Made of base metal.

rather precise and time-consuming, particularly if it is only used occasionally, and so it is not employed as frequently as the other types.

The tapered-threaded type should not be used. The post material is relatively weak and the technique often introduces excessive stress into the dentine, which may then fracture. If the self-threading characteristics of the post are not used in order to avoid these stresses then the post is not as retentive as other systems.

### One-piece post crown

In some cases, for example with very short clinical crowns or with lower incisors, there is insufficient space within the crown of the tooth to make both a retentive core and a separate crown. Then, a crown made of metal–ceramic material with the post cast as part of the crown is often the solution (Figure 2.3c).

### Other types of crown for root-filled teeth

Occasionally the root canal is obliterated by a fractured post that cannot be dislodged, or the root canal is completely closed with secondary dentine. A crown can still be made by building up a core, usually in composite retained by pins: alternatively a metal–ceramic crown retained by pins cast together with the base of the crown can be used.

Neither of these two techniques is likely to be as retentive as a post crown, and particular attention must be paid to avoiding excessive occlusal forces.

### Posterior complete crowns

#### Cast metal crowns

Although traditionally a gold alloy is used for complete metal posterior crowns, the cost of gold and the considerable improvements that have been made in the alternative alloys have resulted in a rapid increase in the number of

crowns made with alloys containing less gold, and in some cases none. The term ‘metal’ is therefore used as more accurate than ‘gold’ in most cases.

The British Standard BS 4425 for dental casting alloys has been replaced by BS EN ISO Standards to reflect these improvements and the wide range of alloys now available. The American Dental Association (ADA) classification has also largely been replaced by BS EN ISO Standards.

This is now a complicated and confusing area and so for everyday clinical decisions it is best to revert to the original classification of dental casting alloys. All modern dental casting alloys fit into one or other of these groups.

1 (or I or A)	soft	used for small inlays
2 (or II or B)	medium	used for large inlays
3 (or III or C)	hard	used for crowns and bridges
4 (or IV or D)	extra hard	used for larger bridges, implant frameworks and denture clasps

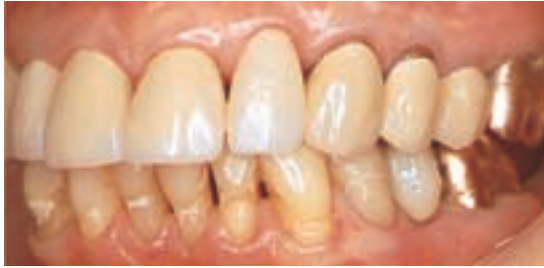However, some of the low-gold alloys are produced in a gold colour, which can be confusing.

Metal crowns are used either when the patient does not mind the appearance of metal or when the tooth does not show during the normal movements of the patient’s mouth. When a complete crown is necessary, it is the restoration of choice since it requires the minimum reduction of tooth tissue, the margins are uncomplicated by the presence of facing material, the occlusal surface is readily adjusted and polished, and the time taken to produce the restoration in the laboratory is less than other types of crown so the cost should be less. It is the most convenient restoration for providing rest seats, guide planes, reciprocal ledges and undercuts in conjunction with partial dentures. It can be soldered to other structures to make bridges and splints, and solder can be added to it to reshape its surface. The only significant disadvantage of the cast metal posterior crown is its appearance (Figure 2.6a and b) but not all patients object to this and some even like it.

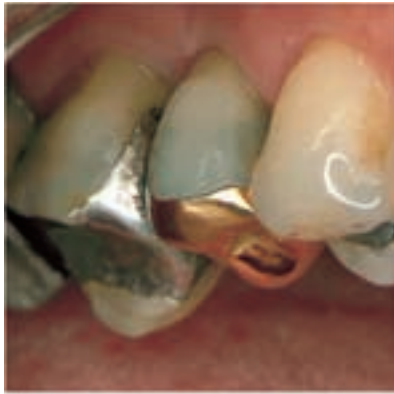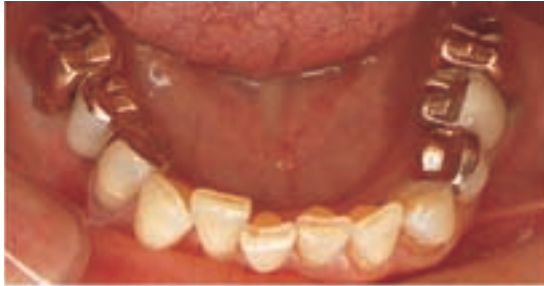#### Metal–ceramic crowns

The principal advantage of metal–ceramic crowns over metal crowns is their appearance (Figure



**Figure 2.6**

*a* and *b* Gold crowns on the first molar teeth which, with this patient's lip morphology, were aesthetically acceptable. There are metal–ceramic crowns on the upper canine and premolar teeth and ceramic crowns on the upper incisor teeth.



*c* A partial crown (three-quarter crown). The tooth is vital: the grey colour comes from the amalgam core. A composite core would have been better.

2.6). Porcelain can be used on the most commonly seen buccal and occlusal surfaces. With many patients the occlusal surfaces of the lower teeth show more than the buccal surfaces and the reverse is true in the upper jaw. Therefore these surfaces are the ones which most commonly need ceramic material for an ideal appearance. Any or all of the other surfaces may also be covered with porcelain.

The disadvantages of the metal–ceramic crown for posterior teeth are that more tooth tissue needs to be removed to allow for the thickness

of porcelain, and when this is on the occlusal surface of a tooth with a short clinical crown there may be difficulty with retention because of the reduced length of the preparation. When this is the case, additional retention by means of pins or grooves is necessary.

With an amalgam core retained by pins, a preparation for a metal–ceramic crown is more likely to give rise to trouble than one for a metal crown, because the greater reduction of the core material may expose the pins and thus jeopardize the retention of the core (Figure 2.7).

## Ceramic crowns

It is sometimes reasonable to use a ceramic crown on a posterior tooth, for example in conjunction with a post and core on a single-rooted premolar tooth. Care needs to be taken in assessing the occlusion, but if this is favourable a modern ceramic crown often has a better appearance than a metal–ceramic crown. However, they should not be used in patients who grind their teeth at night (bruxists). Several manufacturers claim that modern ceramic crowns – particularly those with a zirconia base – are comparable to metal–ceramic crowns, but more tooth preparation is required to allow for crowns of adequate thickness.

## Posterior partial crowns

### 'Three-quarter' crowns

'Three-quarter' posterior crowns actually cover four-fifths of the tooth's surface – mesial, distal, occlusal, lingual or palatal and so 'three-quarter' is not a very good name.

They are retained by grooves on the mesial, distal and occlusal surfaces that effectively perform the same function as the buccal surface of a complete crown (see Chapter 5). They are always made of cast metal, and are used when the buccal surface of a tooth is intact and reducing it as part of a complete crown preparation would either produce an unsightly and unnecessary display of metal or where reducing the buccal cusp would weaken it, reducing the strength of the preparation. An example of a tooth where a three-quarter crown is needed is shown in Figure 1.12c and clinical examples are shown in Figure 2.6.

The advantages of posterior partial crowns are that they are more conservative of tooth tissue than complete crowns, and the margin of the crown does not approach the gingival margin buccally. It is still possible to test the vitality of the tooth via the buccal surface, and the appearance is preferable to a complete metal crown, without there being the need for the extra tooth destruction.

Some dentists find the preparation difficult, but they would do well to learn the skill involved since the posterior partial crown is very conservative of tooth tissue, falling between the minimum preparation and the complete crown preparation. It is still a useful part of the dentist's repertoire.

## Other types of posterior partial crowns

There are a variety of alternative posterior crowns. The 'seven-eighths' crown covers all but the mesial buccal cusp of an upper molar tooth, the 'half' crown covers the mesial half and occlusal surface of a lower posterior tooth where the distal wall is very short, and other variations leaving various odd bits of the tooth surface exposed are also made. Principles governing the design of all these partial restorations are the same and are covered in Chapter 5. It is for the dentist to use these principles to plan the detailed design of each restoration to solve its particular problems. It is not good practice to follow classic cookery book-type preparation designs, none of which may be suitable.

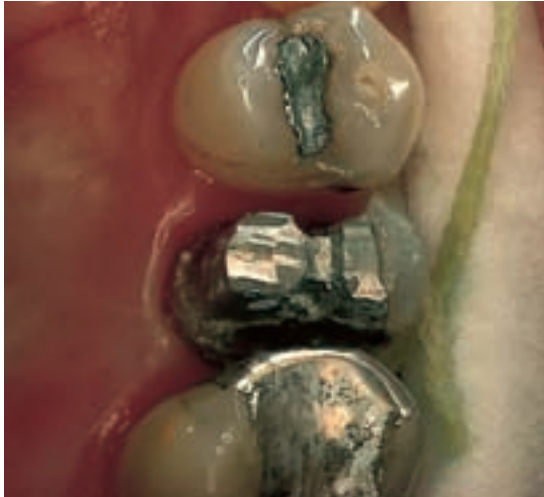A further variation of the posterior partial crown is the occlusal onlay, made to alter the shape of the occlusal surface or the occlusal vertical dimension but without necessarily covering any of the axial walls. It is retained by intra-coronal features or adhesive techniques, and sometimes whole quadrants of opposing teeth are restored by these means (Figure 1.15).

## Cores for posterior crowns

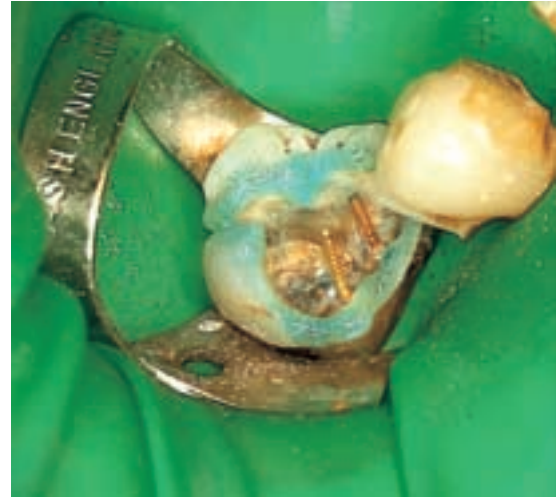Badly broken-down posterior teeth are rebuilt to the general shape of the tooth using amalgam, composite, glass ionomer cement or cast metal before preparing them for crowns. These cores are retained by one of the techniques described below.

### Cores of amalgam, composite or glass ionomer cement

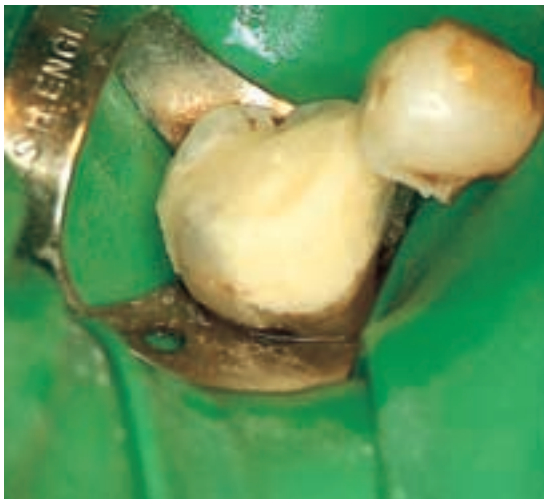The commonest type of posterior core is made of amalgam. In vital teeth the amalgam may be bonded to the remaining dentine or retained by pins or a combination of both. With the success of bonding when there is enough dentine remaining, pins are now only used with very broken down, but vital teeth. The pins are usually threaded self-tapping pins screwed into dentine.



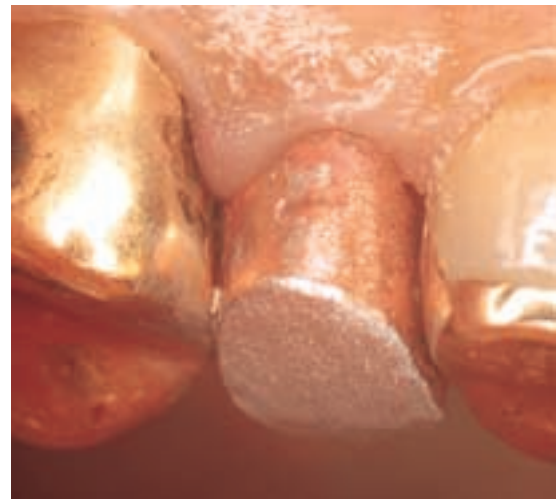*a* A vital tooth with a pin-retained amalgam core for the partial crown shown in Figure 2.6c. Pins must be sited with a view to the eventual preparation design – in this case avoiding the mesial and distal surfaces, where grooves are to be prepared. The alternative, a complete metal–ceramic crown, would have relied entirely on pin retention, the remaining cusp having been removed during preparation. Elective endodontic therapy and a post-retained crown would have been less conservative.



*b* A vital tooth prepared with pins for a pin-retained composite core. The enamel margin is being etched with gel. Once the gel is washed off, the deep part of the cavity will be lined. An alternative would be to use the 'total-etch' technique, avoiding pins.



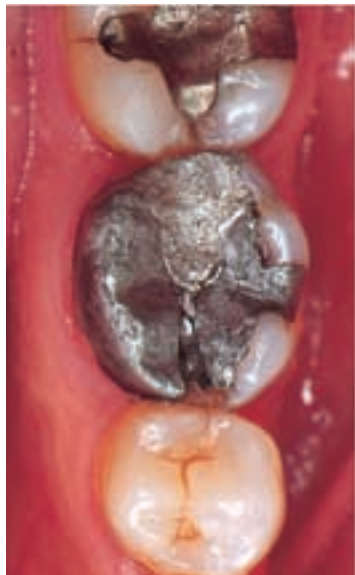*c* The composite core in place, having been built up in several increments of light cured composite. This can now be prepared at the same visit and a temporary crown placed.



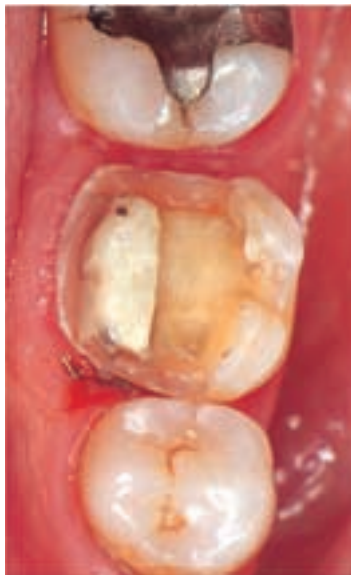*d* An amalgam core retained by a copper ring. The patient was unable to return for the crown preparation until 8 months after the core was placed. There is some gingival inflammation distally, but apart from this the gingival inflammation has been minimal. The core is intact. A large core like this placed with a matrix band would be vulnerable to fracture until it is prepared and protected with a temporary crown.

**Figure 2.7**

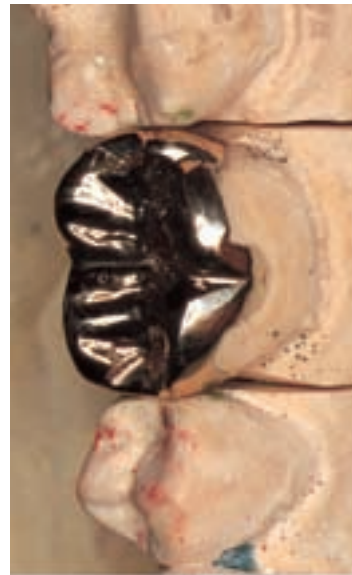Cores for posterior crowns.



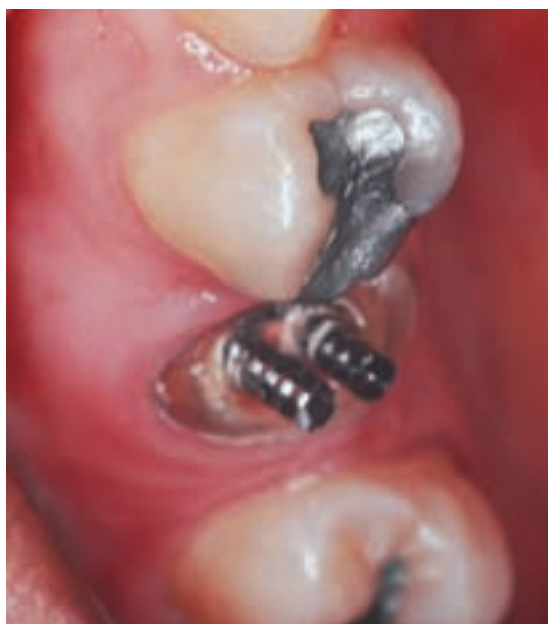e A large failed amalgam restoration.



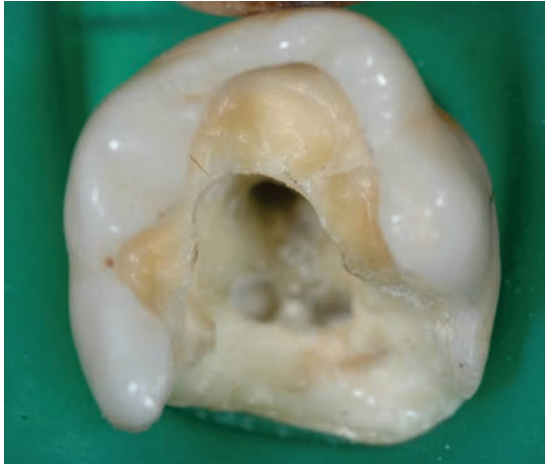f The amalgam removed and a composite core placed, retained by two pins. The heads of the pins can be seen. They are sited within the composite core, away from the periodontal membrane and pulp and will resist lingual displacement of the core.



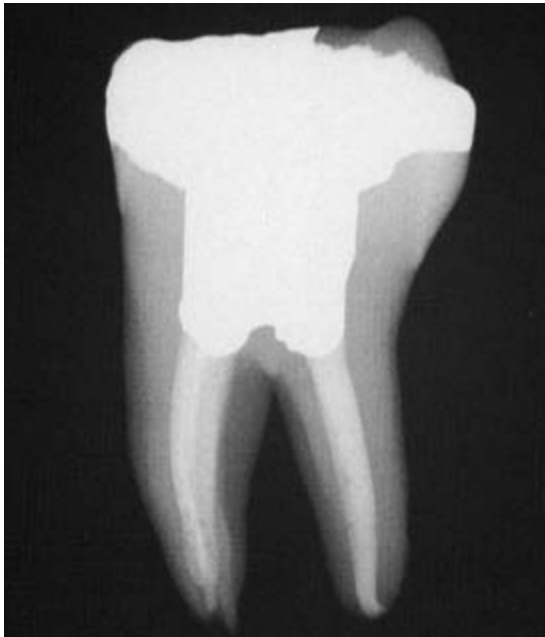g The partial (three quarter) crown on the die.



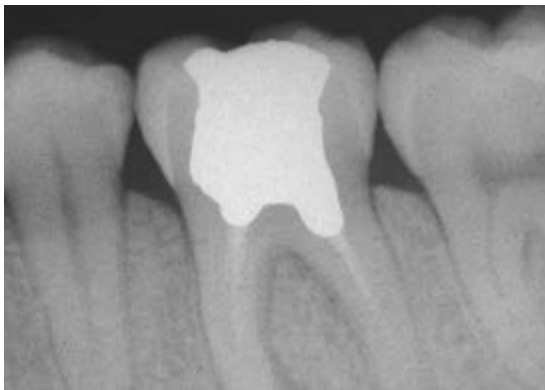h A premolar tooth prepared with two preformed parallel-sided posts for a post-retained core.



*i* Tooth prepared for a Nayyar core.



*j* A radiograph of the core in place.



*k* A clinical example of a Nayyar core.

When pins are used in a vital tooth, it is important to choose the correct number of pins and to site them properly. In deciding the number and location of pins, the final design of the preparation must be anticipated. For example, pins should not be placed too close to the buccal margin when a metal–ceramic crown is planned, they risk being exposed when the shoulder is prepared. Similarly they should not be placed in the middle of the mesial or distal surfaces of a core when the tooth is going to be restored by means of a partial crown. If they are, the grooves in the mesial and distal surfaces of the preparation may expose the pins (Figure 2.7a). If a substantial cusp remains, the pins should be set at an angle relative to the inner surface of this cusp so that there is a retentive undercut between the pins and the cusp.

When the final restoration is to be a metal–ceramic crown, the pins must be kept well clear of the buccal shoulder area so that they are not exposed during the preparation of the tooth. Also when a metal–ceramic crown is planned, any remaining buccal cusp will usually be severely weakened by the preparation, and cannot be relied upon to retain the core. Sufficient pins must therefore be placed to retain the core without this cusp, and it is sometimes good practice to remove the cusp completely before the core is placed.

Pins should not be used with root-filled teeth. The dentine of root-filled teeth is thought to be more brittle than vital teeth, and so the stress introduced by self-tapping pins may produce a greater risk of the tooth fracturing. In any case it seems commonsense to use the relatively large holes that already exist down the root canals rather than drill yet more holes into the tooth for pins. An amalgam core in a root-filled tooth can be retained by posts in the root canals (Figure 2.7h) or by the Nayyer technique (Figure 2.7i, j and k).

With amalgam cores for both vital and non-vital teeth, a conventional amalgam matrix may be used to retain the amalgam while it is being

condensed, but when considerable tooth tissue loss has occurred it is often better to use a copper or orthodontic band that can be left in situ until the crown preparation is started. This supports the amalgam while it is setting, and reduces the risk of the amalgam core fracturing before preparation (Figure 2.7d).

Composite cores can be used in the same way as amalgam cores, and they have the advantage that they can be prepared at the same visit that they are inserted (Figure 2.7b and c). A suitable dentine bonding agent should be used and the composite built up in increments, light curing each increment to reduce the effects of polymerization contraction. Despite these precautions, there is some concern about the risks of microleakage between the composite core and the dentine surface.

When posts are used to retain posterior amalgam or composite cores, the commonest type is the parallel-serrated preformed metal post (Figure 2.7h). If a substantial cusp remains and the post is placed in one of the root canals at an angle to the inner surface of the cusp, this will produce an undercut and therefore retention for the core. In other situations where more of the enamel and dentine have been lost or will be removed in the crown preparation, two or even three posts should be used. Where the pulp chamber is intact the retention of the core using the Nayyer technique is preferable to the use of posts, which are sometimes difficult to place in the roots of molar teeth.

### **Cast posterior cores**

With the Nayyer system, bonding and modern posts to retain amalgam and composite posterior cores, there is little need for cast metal posts and cores in multi-rooted posterior teeth. However, cast posts and cores are still useful for single-rooted premolars when the post hole is tapered and when a diaphragm is needed.

[WWW.HIGHDENT.IR](http://WWW.HIGHDENT.IR)

همیار دندانسازان و دندانپزشکان

## 3

# Designing crown preparations

Teeth vary so much in their general shape and in the effects upon them of caries, trauma, tooth wear and previous restorations that it is less helpful to describe classic 'ideal' preparation designs than it is to give the principles determining the design and then show how these should be applied.

## The principles of crown preparation design

The following factors need to be considered:

- Materials
- Function
- Appearance
- Adjacent teeth
- Periodontal tissues
- Pulp
- Retention of the crown to the tooth.

## Related to materials

### Metal crowns

Dental casting metal is strong in thin sections and can be used to overlay and protect weakened cusps against the occlusal forces. It is, however, ductile, and can be distorted if it is too thin or if it is subjected to excessive forces. Normally no metal surface should be less than 0.5 mm thick and occlusal surfaces should be more. This usually means that an equivalent amount of tooth tissue has to be removed. When distorting forces are anticipated, the design can be modified either by reducing the tooth more, and producing a thicker metal layer, or by introducing grooves or boxes into the preparation to stiffen the metal by producing ridges on the fit surfaces.

### Ceramic crowns

Porcelain is brittle when subjected to impact forces, and must be in sufficiently thick sections to withstand normal occlusal and other forces. Most of the reinforced ceramic systems (see Chapter 2) produce cores which are opaque but not as opaque as the metal of metal–ceramic crowns. Therefore it is necessary to provide a sufficient thickness of more translucent porcelain on the labial/buccal surface of the crown to simulate the appearance of a natural tooth. It follows that the minimum reduction for a ceramic crown, made by any of the techniques, is much greater than for a metal crown.

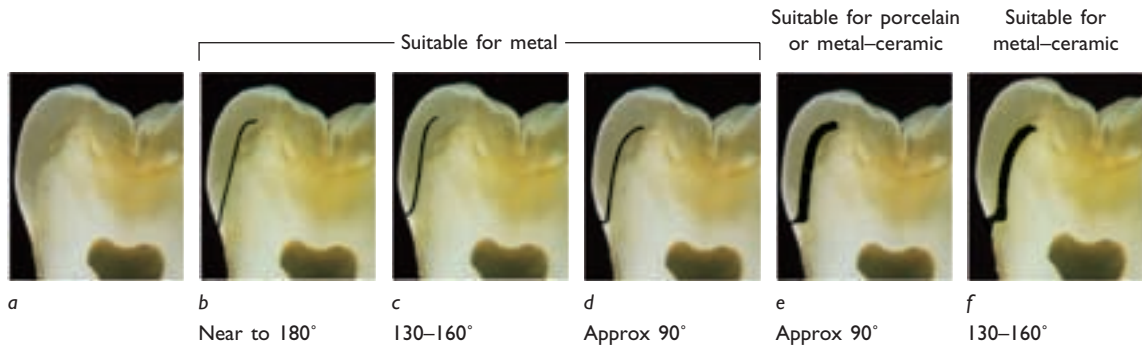
The edge strength of porcelain is low, and therefore the compromise at the cavosurface angle between brittle enamel and brittle porcelain is a 90° butt joint (Figure 3.1e).

### Metal–ceramic materials

Even greater reduction of tooth tissue is necessary for metal–ceramic crowns on the visible surfaces, because the metal layer will need to be covered by an opaque layer of porcelain, and this in turn will need to be covered by translucent porcelain. A thickness of 2 mm is ideal, but in many situations, for example lower incisor crowns, this is impossible because of the smallness of the tooth. Where part of the crown is all metal, for example on the lingual side, the preparation is as it would be for a metal crown.

The margin of the crown may be constructed in porcelain or metal, or the two materials may join at the periphery. The cavosurface angle will depend upon this decision. Figure 3.1e and f shows shoulder and bevelled shoulder finishing lines. An alternative, preferred by many dentists and technicians, is a deep chamfer. Figure 3.1c shows a narrow chamfer suitable for a metal crown and this can be deepened into dentine for a metal–ceramic crown.



**Figure 3.1**

Margin configurations for crown preparations.

*a* A section of a molar tooth.

*b* A knife-edge margin with a cavosurface angle approaching  $180^\circ$ .

*c* A chamfer margin with a cavosurface angle of  $130^\circ$ – $160^\circ$ . This is the most commonly used margin for metal finishing lines. It can be deepened for metal–ceramic margins.

*d* A finishing line with minimal tooth reduction but with a sharp step, prepared with a square-ended instrument producing a cavosurface angle of approximately  $90^\circ$ .

*e* A full shoulder with a  $90^\circ$  cavosurface angle which is used for ceramic crowns. When used for a metal–ceramic crown, the metal is either brought to the margin or finished short, leaving a porcelain margin.

*f* A full shoulder with bevelled margin for a metal–ceramic crown when the margin cannot be seen, for example at the buccal margin of lower molar teeth. A metal margin may be easier to finish and be less plaque retentive than porcelain. It is also easier to make in the laboratory.

tooth which has tilted forward into the space of an extracted first molar will usually have occlusal contact with its distal cusps but not its mesial cusps. In preparing the tooth for a crown more occlusal enamel needs to be removed distally than

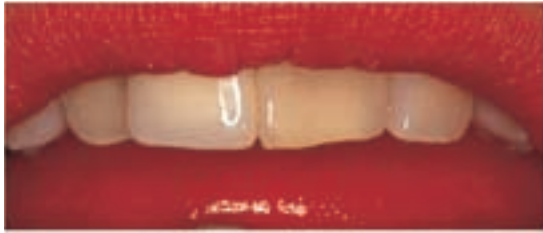## Related to function

### Occlusion

The occlusal relationships of the tooth to be crowned will influence the design of the preparation. Those areas of the crown subjected to heavy occlusal loading in the intercuspal position (see Chapter 4) or in one of the excursions of the mandible should be sufficiently thick to withstand these forces without distortion if the crown is metal, and without fracture if the crown is ceramic or metal–ceramic. This means that in an Angles Class I occlusion there should be adequate reduction of the occlusal surfaces of the posterior teeth, the palatal surfaces of upper incisor teeth and the incisal edges of lower incisor teeth. Other surfaces may also be involved in different occlusal relationships.

When there is posterior group function, that is, several pairs of posterior teeth slide against each other as the jaw moves to the working side (see Chapter 4), the result of applying this principle is that the cusps that function against each other in this way should be reduced more than other parts of the preparation. This is often referred to as ‘beveling the functional cusp’. Before this is done, the actual relationships of the cusps in question should be studied during the full range of movements. In the majority of patients the posterior teeth are discluded in lateral excursion by the canine teeth. These ‘functional’ cusps therefore only function in the intercuspal position and are less vulnerable to wear and to lateral forces. There is therefore less need to reduce them any more than the rest of the occlusal surface.

With tilted teeth the occlusal reduction is often not uniform, for example a lower second molar



**Figure 3.2**

Inadequate reduction of the labial incisal area of the preparation so that the core shows through the ceramic crown on the upper right central incisor.

mesially and the crown built up mesially to re-establish occlusal contact.

In some cases the crown is being made to alter the occlusal relationship, and it may be necessary to reduce the occlusal surface less than usual if the intention is to increase the occlusal vertical dimension.

### Future wear

All restorative materials wear in use, and the rate is determined by the occlusion, the diet and parafunctional (bruxing) habits. Where the tooth surface is intact before crown preparation is started, careful note should be made of any wear facets, and these areas of the tooth surface should be prepared sufficiently to allow for an adequate thickness of crown material so that future wear will not produce a perforation of the crown.

### Related to appearance

#### Labial, buccal, incisal and proximal reduction

Adequate reduction of the tooth surface must be carried out on those surfaces where the appearance of the crown will be important. Insufficient labial or incisal reductions for ceramic crowns results in the core material showing through (Figure 3.2) or the crown being too prominent. Proximal reduction is important to achieve translucency at the mesial and distal surfaces of the crown. Further back in the mouth it is more important to reduce the preparation mesio-buccally than disto-buccally since this is the more important surface aesthetically.

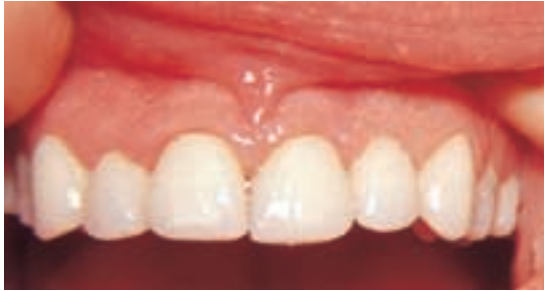### Occlusal reduction of posterior teeth

In most patients the occlusal surfaces of the lower premolar and molar teeth are more visible than the buccal surfaces in normal speech and laughter. If metal-ceramic crowns are made for lower posterior teeth, it is usually necessary to reduce the occlusal surface sufficiently for porcelain to be carried over it.

In the upper jaw the occlusal surfaces are far less visible, the buccal surfaces being more important aesthetically. It follows that it may be necessary only to reduce the occlusal surfaces of upper posterior teeth sufficiently for a thickness of metal. The decision whether to place porcelain on the occlusal surface of posterior teeth is based on the balance between the patient's wishes and the advisability of undertaking the extra tooth reduction. Patients who grind their teeth will be more at risk of porcelain fracture, especially if there is a group function in lateral movement (see Chapter 4).

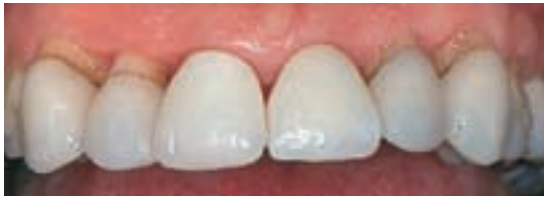### Crown margins

The position of the crown margin in relation to the gingival margin affects the appearance. Subgingival margins may have a better appearance initially but will sometimes produce a degree of gingival inflammation that, apart from possibly leading to more serious periodontal disease, is itself unattractive. Crown margins at the gingival margin or slightly supragingival need not be obvious and will be less likely to produce gingival inflammation (Figures 2.6a and 3.3). It is also easier to take impressions of supragingival margins, to assess the fit and to maintain them. The intention to make visible margins supragingival should be discussed with the patient, explaining the reasons, before the teeth are prepared.

**Figure 3.3**

Crown margins.

*a* Six crowns made with subgingival margins.



*b* The same crowns, except for the central incisors, which have been replaced, photographed 9 years later. There has been extensive periodontal disease and surgery throughout the mouth. The crowns were replaced with slightly supragingival margins, and the gingival tissues have remained stable.

Metal–ceramic crowns with a metal margin will be more obvious if the patient's smile line shows the gingival margins. The metal margin can be cut back and the margin produced in porcelain reducing this problem, but there is often still a greying of the margin and adjacent soft tissues with metal–ceramic crowns. Patients with high expectations and those with high lip lines may be better served with ceramic restoration when restoring teeth in visible areas. If metal–ceramic crowns are indicated, for example if the patient has a heavy wear pattern, it will be necessary to place the labial gingival margins in a more subgingival position than normal, requiring great care in tooth preparation, impressions and checking the marginal fit of the crown. With subgingival margins, the patient's level of oral hygiene must be very good.

### **Related to adjacent teeth**

#### **Clearance to avoid damage to adjacent teeth**

If only one tooth is being prepared for a crown, it is clearly important to avoid damage to the adjacent teeth. This is much easier said than done, and a number of studies have shown that slight damage to adjacent teeth during crown prepara-

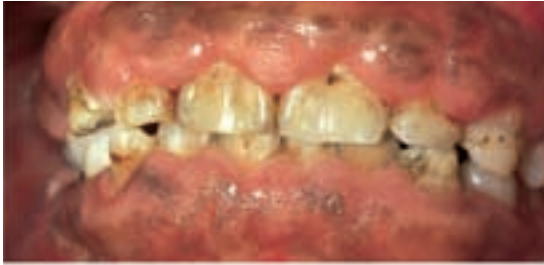tion is extremely common. In preparing the approximal surface of a tooth with burs, the tooth surface must be reduced sufficiently to allow the full thickness of the bur to pass across the contact area within the contour of the tooth being prepared, leaving a tiny fragment of enamel or amalgam core in contact with the adjacent tooth. This falls away once the bur emerges at the other side of the tooth. This means that extensive reduction is often inevitable at the approximal surface (see Figures 3.11 and 6.10b).

#### **Path of insertion**

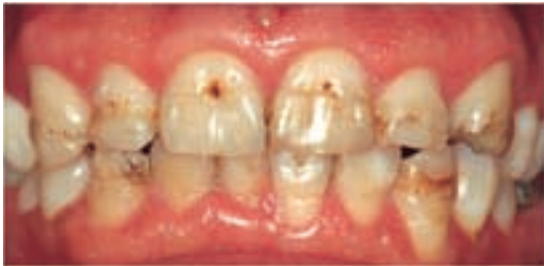When teeth are unevenly aligned, although a crown preparation can be made and an impression taken, the finished crown sometimes cannot be seated because the overlapping adjacent teeth prevent its insertion. Adjustment of the crown to allow seating results in an open contact point. The solution is either to reshape the adjacent teeth or to design the preparation at an angle that permits the insertion of the crown.

#### **Oral hygiene and technical considerations**

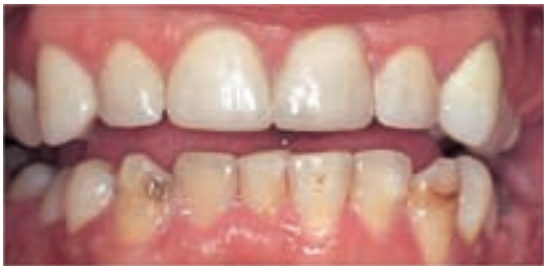Proximal reduction should preferably be continued to allow clearance between the gingival margins and the adjacent tooth sufficient for a fine

**Figure 3.4**

a Gross gingival hyperplasia and enamel hypoplasia.



b The hyperplastic gingival tissue has been removed surgically.



c Crowns on the upper incisor teeth for the same patient.

saw blade to be passed between the dies, so that they may be separated in the laboratory. This also facilitates cleaning the margins once the crown is fitted (see Figure 3.17c). This may involve placing the margin deeper if the teeth are close together and this should be assessed radiographically prior to starting the preparation. With convergent roots of adjacent teeth this may not be possible.

Figure 3.17c shows the minimum space which should be left between the distal surface of the prepared canine and the premolar tooth.

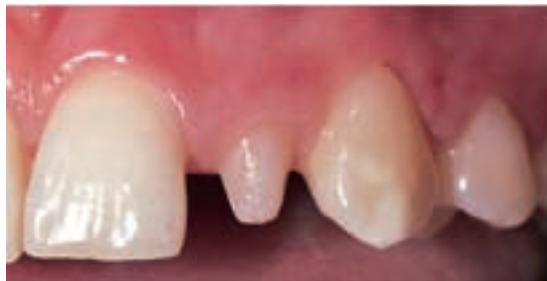### **Related to periodontal tissues**

The importance of supra- or subgingival crown margins to periodontal health has already been

discussed. The shape of the crown margin (the cavosurface angle) should be designed so that the crown surface can conveniently be made in line with the tooth surface. Insufficient reduction at the margin can result in an overbuilt crown, which in turn produces a plaque retention area at the margin (Figure 3.1b).

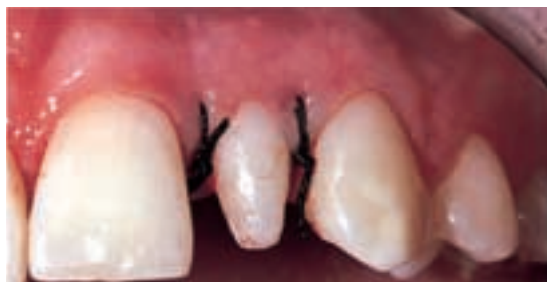It is not always possible to keep crown margins supragingival at the proximal surface. Where the gingival tissues are normal and healthy when crown preparation starts, the interdental papilla fills the space beneath the contact point. Therefore if the crown margin is to include the contact point, it will usually be necessary to make the crown margin subgingival or to remove healthy gingival tissue surgically.

When the gingival tissues are inflamed, as they often are around teeth to be crowned, because

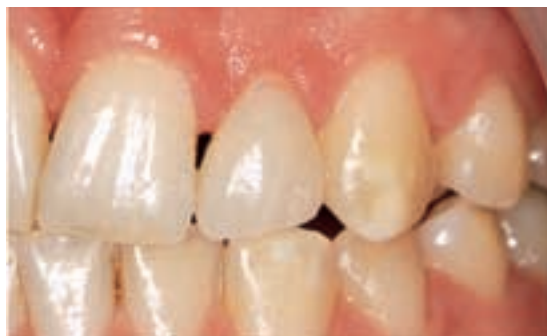

**Figure 3.5**

*a* A peg-shaped lateral incisor with a low gingival margin.



*b* Elective crown lengthening. This photograph was taken a week after the surgery and the sutures are about to be removed.



*c* The upper lateral incisor crowned with a conventional ceramic crown. A similar case treated with a resin bonded ceramic crown is shown in Figure 1.11.

of plaque retention around existing unsatisfactory restorations, it may be necessary to modify the restoration and encourage better cleaning, or to make a well-fitting provisional crown, provide periodontal treatment and then adjust the margins of the preparation.

When periodontal pockets are present that are so deep that they cannot be maintained by improved oral hygiene, periodontal surgery may be necessary, and this will usually have the effect of moving the gingival margin apically so that more of the clinical crown (and root) is visible. This makes crown preparation with supragingival margins easier, but the appearance may be poor,

with large triangular spaces between the necks of the teeth (Figure 7.5). This surgical procedure is often justified where there has been alveolar bone loss through periodontal disease or in other periodontal conditions (Figures 3.4 and 3.5). It is essential that the gingival condition is stabilized prior to the final cementation of the crown, if need be by the medium-term use of well fitting provisional crowns and re-inforcement of oral hygiene procedures, otherwise later recession of the gingival margin due to further progression of the periodontal disease is likely to occur.

A similar procedure, 'crown lengthening', is also sometimes carried out where there is a normal

level of alveolar bone and healthy gingival tissues but where the clinical crown height is reduced and it is perceived that there is a problem with retention. Crown lengthening usually involves the removal of healthy alveolar bone, and is therefore destructive, and is quite uncomfortable for the patient. Alternative means of improving retention should therefore be used whenever possible, and crown lengthening should be reserved for those cases where part of the purpose is to move the gingival margin apically for aesthetic reasons or where alternative means of retention are considered to have a poor prognosis.

### **Related to the pulp**

When a vital pulp is to be retained within the crown preparation, a minimal thickness of dentine must be preserved to protect it. The thickness of this layer will depend upon the age of the patient, the condition of the dentine (i.e. the amount of peritubular and secondary dentine) and the type of preparation. Only an approximate estimate can be made of the size of the pulp in a given case, even with good radiographs. So, confusingly, the design of the crown preparation is partly determined by the need to preserve the pulp undamaged without really knowing in detail where it is within the tooth.

As with all tooth preparation it is essential that preparation is carried out with copious water cooling, sharp burs and gentle techniques to limit potential damage to the pulp. Even with care being taken and the preparation not exposing the pulp there is a small risk that the pulp may die after tooth preparation. There is a view that all patients should be warned of this potential risk, which may not present until long after the crown is placed. There is a contrary view that warning every patient of every possible complication of treatment is not in their interest because with some patients the effect may be to frighten them to the extent that they refuse treatment that would be in their interest. Warnings must, of course, be given of serious risks and frequent complications. Dentists should assess the patient as a whole, the clinical circumstances and the specific risk of pulp death in deciding whether a warning is appropriate.

The size of the pulp will also be determined by the condition that has necessitated the crown

preparation. If this has been a slowly progressing condition such as caries or tooth wear then the probability is that the pulp will have laid down a substantial amount of secondary dentine and will therefore be much less vulnerable than if the tooth has been fractured in an accident. If the natural crown of the tooth is small (microdontia) and the purpose of making a crown is to increase the size then very little tooth preparation is necessary and the pulp is not significantly jeopardized even with young patients (Figure 3.5).

This need to protect the pulp often conflicts with the need for an adequate thickness of crown material, particularly in extreme cases such as metal–ceramic crown preparations on lower incisor teeth. Here the ideal thickness of crown material commonly has to be compromised in favour of the need to protect the pulp.

A good way to gain experience that should help avoid too many dead pulps or failed crowns is to make preparations on a variety of extracted teeth and then section them to see how much dentine is in fact remaining (Figures 3.6 and 3.7).

### **Retention**


There are two principal systems used to retain restorations in crowns and bridge retainers.

#### **Mechanical retention**

The conventional method, which has been used for many years, involves preparing the tooth to a retentive shape and then cementing the crown or bridge retainer with a luting cement, which is not usually chemically adhesive to either the tooth surface or the fit surface of the crown. The crown is retained by a combination of the mechanical design features to be discussed shortly.

#### **‘Adhesive’ retention**

The second system is to use an adhesive luting or bonding cement that bonds either chemically or micromechanically to both the tooth surface and the restoration. Restorations cemented in this way therefore do not need to rely primarily on



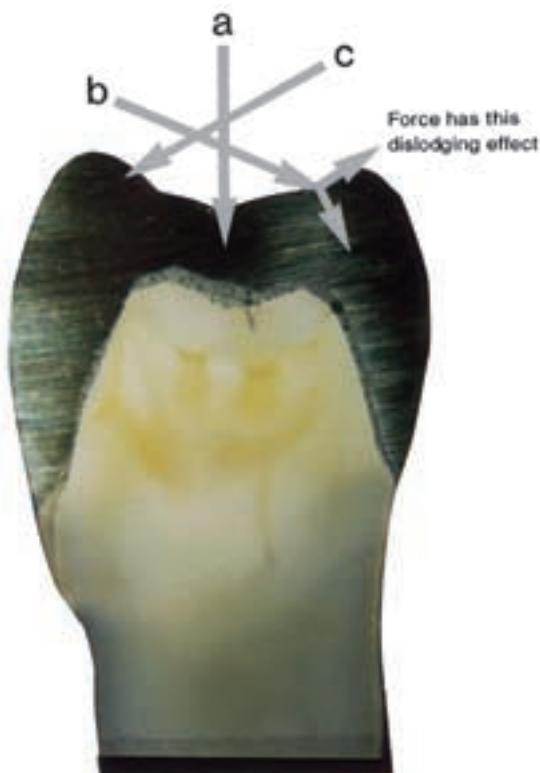**Figure 3.6**

A metal–ceramic crown preparation on a lower incisor.

*a* An extracted tooth. The bucco-lingual width at the cement–enamel junction is 7 mm.

*b* Prepared for a metal–ceramic crown. The width of the buccal shoulder is 1.2 mm and the lingual chamfer is 0.5 mm wide.

*c* Sectioned and the pulp filled with wax. The closest point of the preparation to the pulp is 1 mm.



**Figure 3.7**

This extracted molar tooth has been prepared with a taper of  $35^\circ$ . This is more than the recommended figure (page 63). An occlusal force, *a*, will not dislodge a crown, however unretentive the preparation. A force directed at an inclined cusp plane, *b*, occurring in lateral excursions of the mandible will, though, have a dislodging effect if the crown preparation is unretentive as in this case. Loss of retention is unlikely to occur as a result of a single contact of this sort. It is more likely to result from small repeated forces in alternate directions, *b* and *c*.



**Figure 3.8**

A confocal microscope image showing composite luting cement penetrating the dentine tubules and producing a very strong bond to the dentine.

the shape of the tooth preparation to retain the restoration. Examples of these restorations are porcelain veneers (Chapter 1) and minimum-preparation bridges and splints (Chapter 8). At present there is a range of such adhesive bonding cements:

- Chemically active resin-based cements, which chemically bond to a freshly grit-blasted precious or ideally non-precious cast metal surface and which lock micromechanically into an etched enamel surface and also bond to it. These cements normally also include a dentine bonding agent.
- Glass ionomer luting cements, which adhere chemically to both enamel and dentine but not to cast metal surfaces or other restorative materials. They rely on a mechanical bond to the restoration surface.
- Composite luting cement consisting of a lightly filled resin that retains restorations by physically locking into micromechanical retentive features on both the tooth surface, etched enamel and dentinal tubules and the restoration (Figure 3.8).
- Resin modified glass ionomer cements which combine the chemical bonding attributes of glass ionomers with the strength and command set of a lightly filled composite resin. These cements work by chemical bonding to enamel

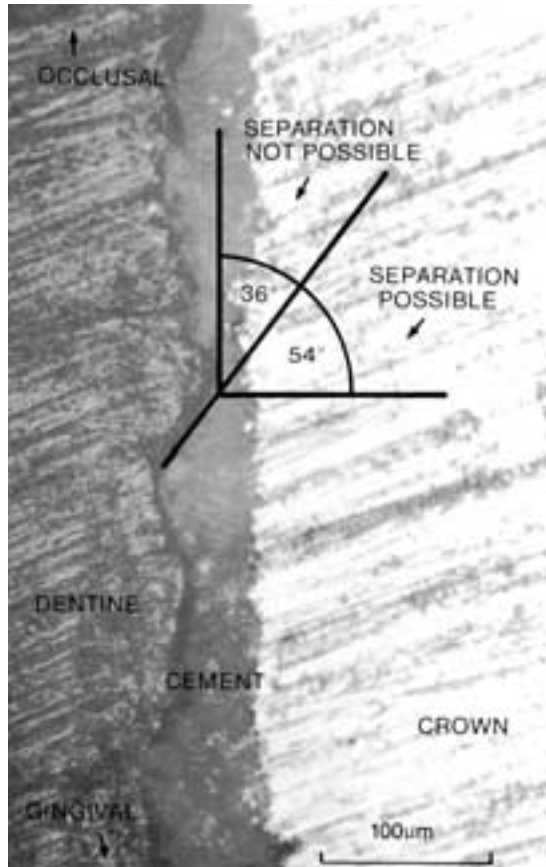
and dentine and micro-mechanical bonding to both the tooth and restoration.

These adhesive systems have improved significantly since the last edition of this book and are still being developed. They have had an influence over the principles of retention used with crowns and bridges as well as allowing the development of new techniques. The design of preparations for porcelain veneers and minimum-preparation bridge retainers is given in Chapters 1 and 8. The design for a resin bonded crown is that the preparation should, as far as possible, be confined to enamel to obtain the optimum bond and retention. Figure 1.11 shows the preparation of two peg shaped lateral incisors for resin bonded crowns. Figure 3.6 shows the preparation for a lower incisor for a metal–ceramic crown. It shows the balance which must be struck between the need to protect the pulp and the need for sufficient preparation of the labial surface to produce a satisfactory appearance.

### **Retention for conventional crowns**

Despite the important developments with adhesive cements described above, only a limited number of teeth can be treated in this way. The





**Figure 3.9**

A section through a typical dentine/cement/crown interface showing the irregularity of the two surfaces and the angle at which separation must occur unless the cement is to be crushed.

majority of crowns are still made by conventional techniques and so the following paragraphs relate to these.

### **Retention against vertical loss**

A crown inserted from an occlusal or incisal direction can be lost in the reverse direction. Axial forces unseating crowns in this direction fall into three categories.

First, there can be a direct pull on the crown such as that exerted by biting into a sticky toffee and the jaw then being opened sharply. Other direct unseating forces are the removal of partial dentures and leverage in some bridge designs.

Second, there are forces arising as a component of lateral force against an inclined plane (Figure 3.7).

Third, there are forces exerted by the dentist in a deliberate attempt to remove the crown. Apart from the force exerted by the dentist, these vertical unseating forces are less than the forces applied in normal function, which are in directions that seat the crown onto the preparation.

The path of insertion may be inclined away from the long axis if an anterior crown is being constructed to give the appearance of proclination or retroclination, or if a large amount of tooth tissue has been lost on one or other side of the tooth due to caries or trauma so that inclining the path of insertion would allow more of the remaining tooth tissue to be preserved.

### Interlocking minor undercuts

Figure 3.9 shows a section through a dentine/cement/crown interface. The surface irregularities of the dentine are typical of those produced by fine diamond burs. The irregularities of the cast metal surface are typical of a surface that has been cleaned by light grit-blasting. Even without an adhesive cement, it would not be possible to detach the crown from the tooth by sliding it away parallel to the tooth surface or at an angle from the tooth surface, until an angle of more than  $36^\circ$  was reached, without crushing and shearing the cement within the minor undercuts on the two surfaces.

### Taper of the preparation

Depending upon the size of these minor undercuts and the compressive strength of the cement used, the taper of the preparation (the angle between opposing walls) and its length determine the degree of retention against axial unseating forces. A parallel preparation is impractical, since cement cannot be extruded from the crown during cementation leaving an excessive thickness of cement occlusally and at the margin. Once the taper of the preparation exceeds  $30^\circ$  or so, failure through loss of retention becomes common. Under 'ideal', artificial, laboratory conditions and using artificial materials rather than natural teeth, a taper of  $7^\circ$  has been shown to be the optimum with minimum cement film thickness and maximum retention. However, in the mouth it is impossible to achieve consistently a uniform  $7^\circ$  taper without producing some undercut preparations and damaging many adjacent teeth. The human eye cannot, in the clinical situation, detect the difference between a parallel preparation and one of  $10^\circ$  or so. Several studies have shown that the average taper for posterior crown preparations that have been clinically successful in a large number of cases is approximately  $20^\circ$  (Figure 3.10).

Most clinicians do not have a protractor among their instruments and so rather than aiming to achieve a taper of 'x' – which cannot be conveniently measured and which will vary around the tooth – the object should be to produce a preparation that is as conservative of tooth tissue as possible (including adjacent teeth), but where an absence of undercut can clearly be seen. In most

cases this will produce an acceptable taper of between  $10^\circ$  and  $20^\circ$ .

### Length of the preparation

The greater the length of the preparation, the more retentive the crown will be. The minimum acceptable length will depend on other circumstances, including the nature of the occlusal forces, the number of other teeth and whether the crown will be subjected to withdrawing forces from a partial denture or bridge.

The relationship between length and taper is important. The shorter the clinical crown, the more parallel should be the taper attempted.

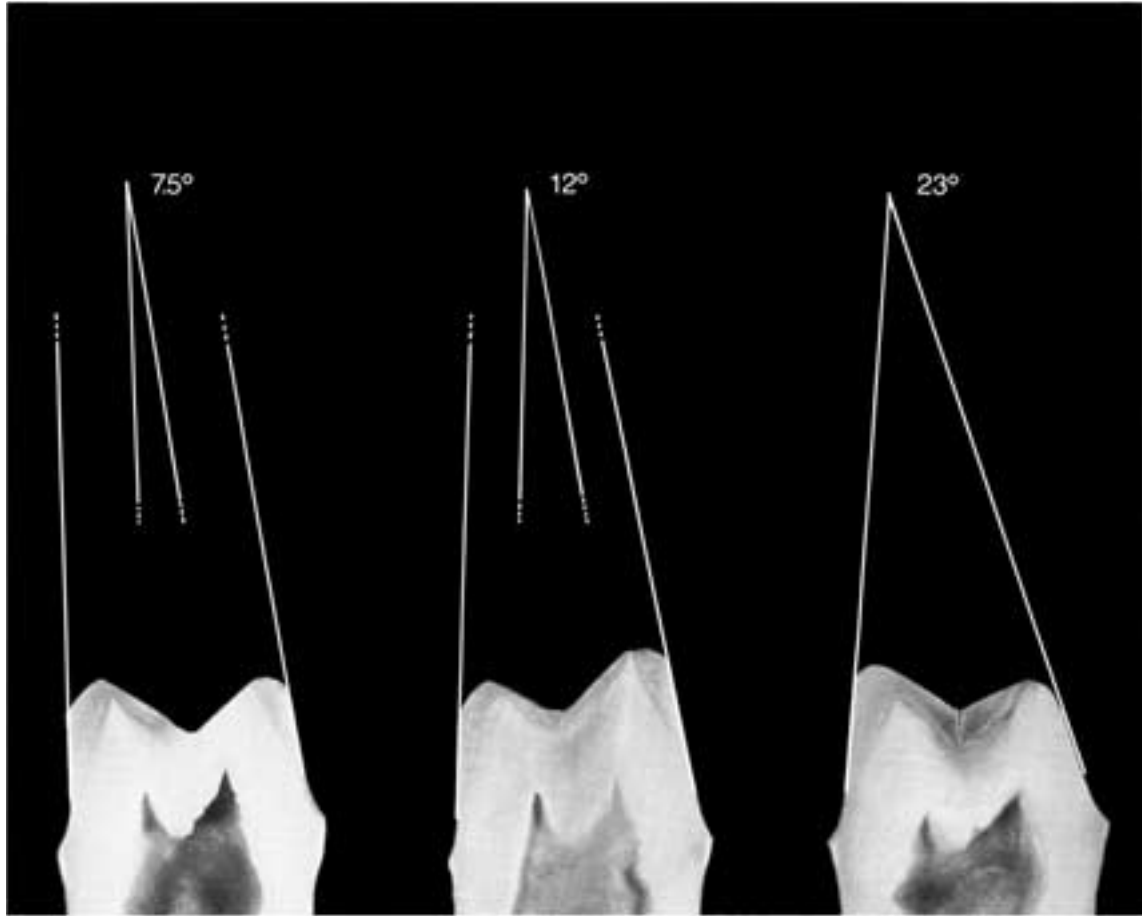
When the clinical crown is assessed as being too short for adequate retention it must be built up with a core (if there is sufficient occlusal clearance), or a surgical crown lengthening procedure may be carried out (Figure 3.5) or additional retention may be achieved by means of grooves or pins. Adhesive cement will also help to retain a crown on a short tooth and the combination of optimal tooth preparation with minimal taper and adhesive cement may limit the need for further more drastic action.

### Retention against other displacing forces

Provided that the taper of a complete crown preparation is uniform between all the opposing surfaces, the only way the crown can be lost is along the path of insertion. However, some crowns cannot be made with uniform taper. Incisor teeth, for example, can be prepared with a small angle of taper between the mesial and distal surfaces, but it is impossible to produce a narrow angle of taper bucco-lingually – similarly with some molar teeth (Figure 3.11). Partial crowns must also be designed to prevent loss in directions other than axial – see later.

In all these cases it is helpful to envisage the crown as potentially being dislodged from the preparation in one of five directions:

- occlusally
- buccally
- lingually
- mesially
- distally

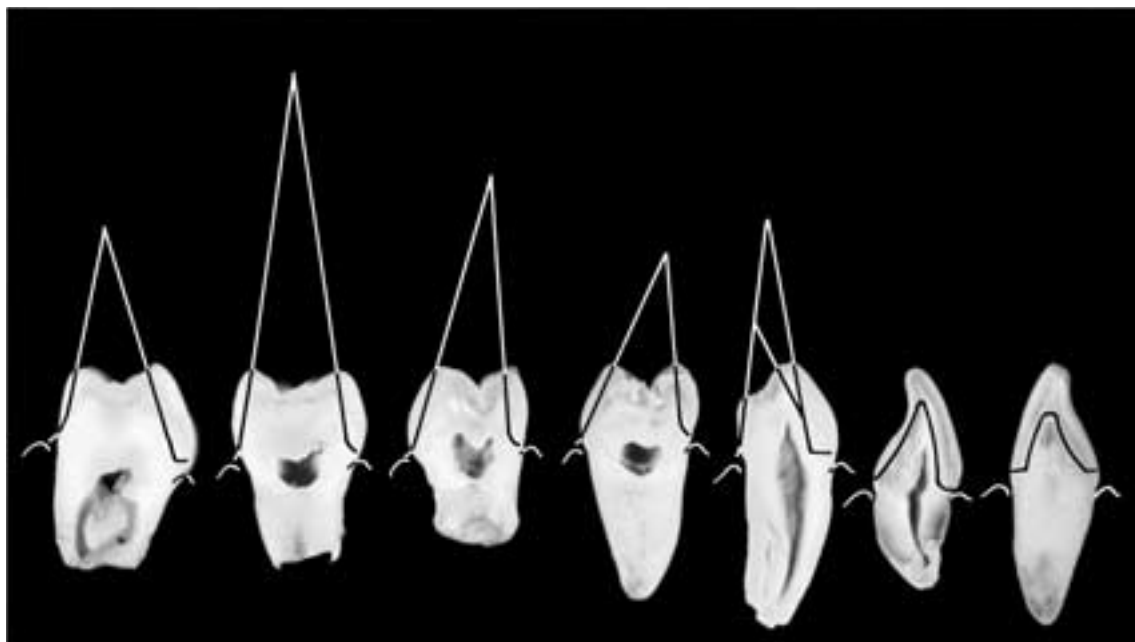


or at any angle between these directions. The preparation needs features that prevent loss in all these directions. These features also need to be distributed around the preparation so that the complex (and not fully understood) forces applied to the crown do not dislodge it. All crown materials, and certainly dentine, have a degree of flexibility, and unless the crown preparation has these retentive features, this flexibility may eventually lead to a breakdown in the cement lute, leakage and either caries or loss of retention.

These additional retentive features are usually either grooves or pinholes. Both have the potential not only to resist loss of the crown in a direction other than in the long axis, but also to reduce the angle of the path of insertion. For example, a crown preparation with an excessive

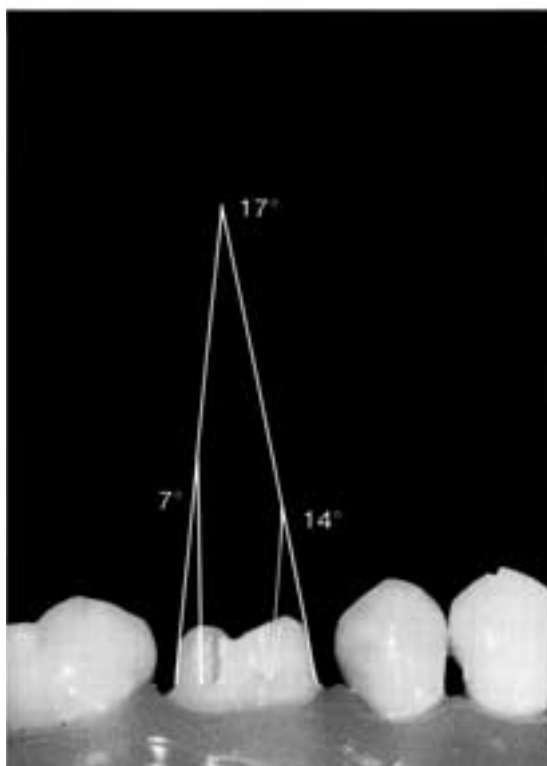
**Figure 3.10**

Bucco-lingual sections through crown preparations on three premolar teeth. The taper of the preparations is shown. The 7.5° and 12° preparations would be sufficiently retentive in virtually any clinical situation. The 23° preparation would probably be satisfactory in most clinical situations unless subjected to undue lateral or axial withdrawing forces. Note that in the 7.5° preparation both buccal and lingual enamel is hardly reduced at all towards the occlusal surface. This is also true of the 12° preparation. This would result in an overbuilt, bulbous crown in this region.



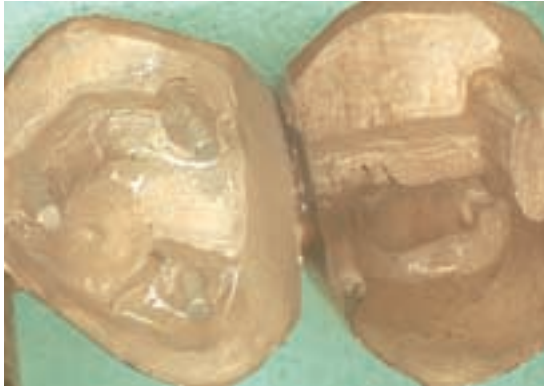**Figure 3.11**

Sections through several teeth showing the difficulty of preparing opposing walls nearly parallel.



**Figure 3.12**

A complete crown preparation that is inevitably tapered mesio-distally because of the relationship with the adjacent teeth. For an individual crown this preparation with a  $17^\circ$  taper and good length would be sufficiently retentive without additional retentive features. However, as an illustration the taper has been reduced by adding buccal and lingual grooves. Grooves should not be used unless they are judged to be necessary, as they bring the preparation closer to the pulp.

**Figure 3.13**

Rigidity in partial crowns.

*a* The fit surface of a premolar partial crown showing the ridge of metal running across the occlusal surface and connected to the mesial and distal ridges. The partial crown for the canine is retained by three pins rather than grooves. Although the premolar preparation is still used, the canine preparation is no longer used, being superceded by bonded restorations. However, there are still many patients with successful bridges retained by partial crowns and so dentists need to recognise them and know how to deal with them if they need maintenance or repair.



*b* The fit surface of another design of an anterior partial crown using pin retention.

mesio-distal taper may be improved with buccal and lingual grooves (Figure 3.12).

where a rim of tooth tissue is left around the post hole and with partial crowns.

### ***Avoiding failure from other causes***

#### **Fracture or distortion of tooth tissue**

The remaining tooth tissue, once the crown preparation is completed, must be sufficiently robust to withstand not only the forces to which it is subjected when the crown is completed and cemented, but also the forces that it will encounter during impression taking, while a temporary crown is in place, and during try-in and cementation of the final crown. This may be a problem in preparations for anterior post crowns

#### **Fracture of ceramic crowns**

Stresses are developed within ceramic crowns as a result of contraction on cooling after the firing cycle. These stresses produce minute cracks, some of which originate at the fit surface and propagate to produce failure if the crown is subjected to sufficient force. These stresses are concentrated around sharp internal angles of the fit surface, so the external angles of ceramic crown preparations should be rounded to reduce these stresses (Chapter 6).

Rounded angles have other advantages: it is easier to lay down a platinum foil matrix without tearing it, sharp corners on a refractory die might



**Figure 3.14**

*a* The fit surface of a full gold crown. Small 'blips' in the casting are common and prevent the casting seating completely. Castings need to be inspected routinely in the laboratory. Look in the lower right part of the occlusal surface.



*b* After careful trimming under magnification the fit surface is accurate.

be damaged, and during cementation the flow is improved, producing a thinner film of cement.

### Distortion of metal

A common cause of failure of anterior partial crowns was leakage producing discoloration and caries behind the incisal tip, and caries starting at the approximal gingival margin. This is one of the main reasons that anterior partial crowns are no longer made.

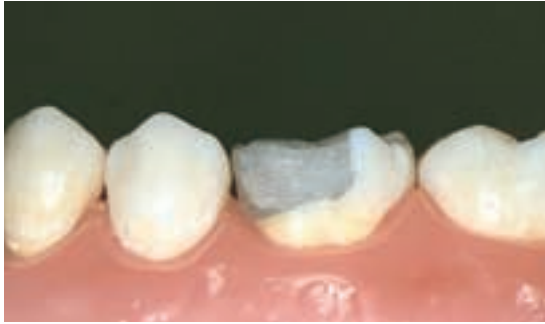For posterior partial crowns the design must include features which stiffen the casting and resist distortion. The traditional posterior partial crown preparation incorporated internal mesial and distal ridges connected to an internal occlusal ridge producing a stiff U-shaped bar (Figure

3.13a). In less classic preparations the principle should be for a ridge of metal to run all the way round the periphery of the preparation to prevent distortion (Figure 3.13b).

### Casting difficulties

The external angles of complete crown preparations for metal castings should also be rounded to prevent one of the faults that may occur in the following chain of events:

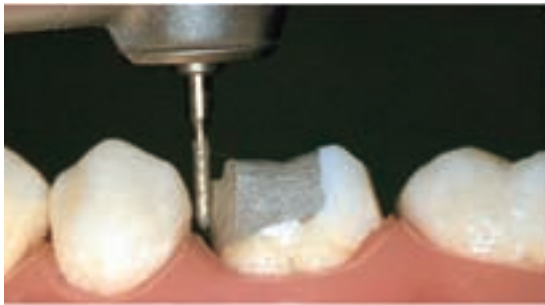- Stone die material may not flow into the impression adequately, trapping air bubbles in the sharp angles of the impression. If this happens and the impression material is suitable, a new stone die can be poured.



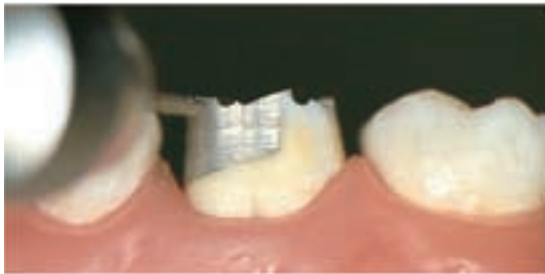**Figure 3.15**

Posterior crown preparations.

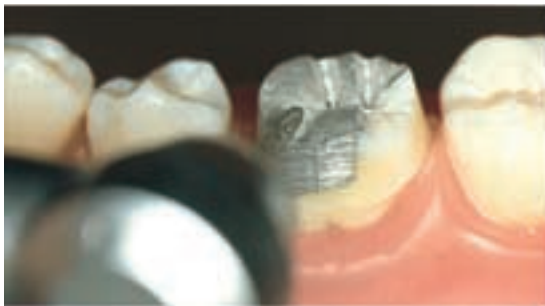*a* Preoperative preparation for a full metal crown.



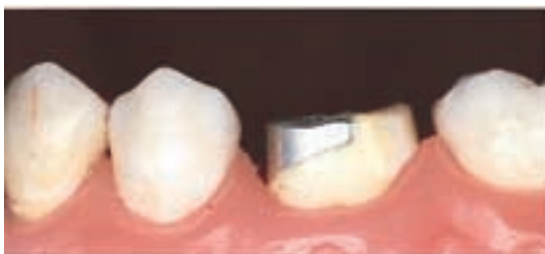
*b* Mesial and distal preparation with a thin diamond instrument with pointed tip to produce a chamfer finishing line.



*c* The axial preparation has been carried round the buccal and lingual surfaces, and grooves are now being placed in the occlusal surface to ensure uniform reduction.



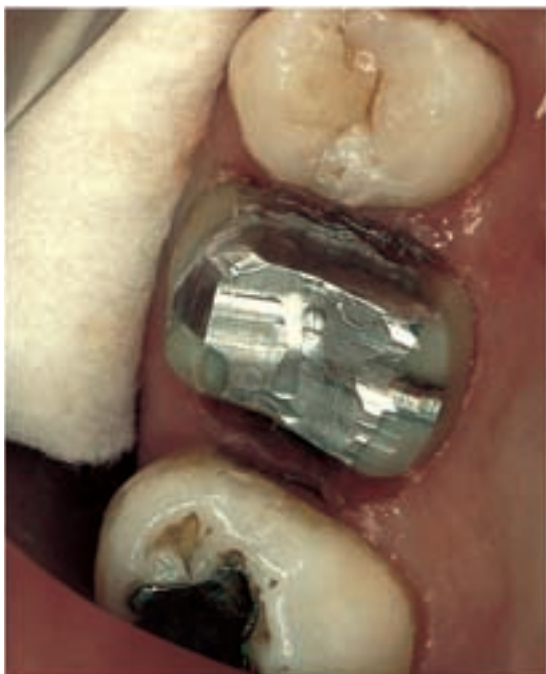*d* Reduction of the occlusal surface. The distal chamfer finishing line can be seen.



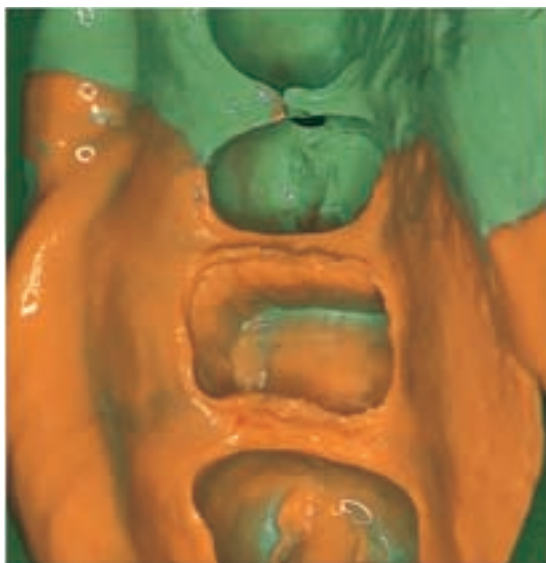
*e* The axial walls of the preparation finished with plain-cut tungsten carbide burs. The axial-occlusal angle will now be rounded.



*f* A mesio-distal section of a cast of the finished preparation with the diamond and tungsten carbide burs used to prepare the tooth. The relationship between these burs and the adjacent teeth can be seen, and it is clear that this is the minimum achievable taper avoiding damage to the adjacent teeth and an excessive shoulder preparation mesially and distally. The mesio-distal taper is 14°.

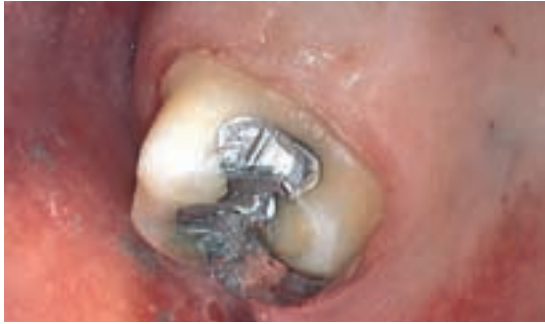

*g* Occlusal view of typical complete gold crown preparation on an upper first molar tooth with an amalgam core.



*h* Impression of the preparation in *g* showing the chamfer finishing line.

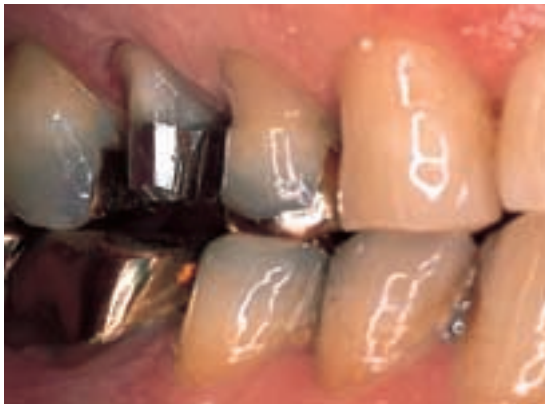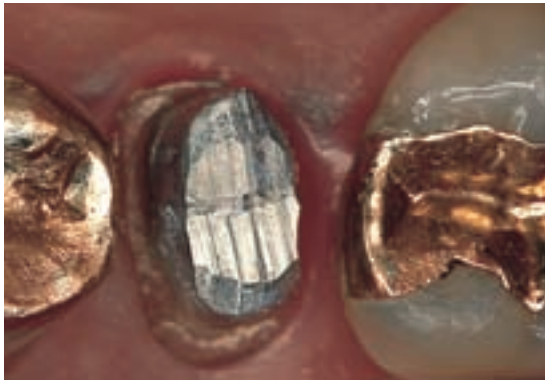




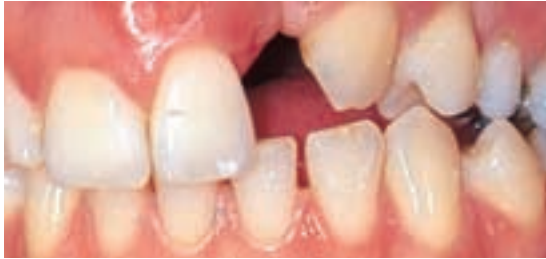**Figure 3.16**

Posterior metal–ceramic crown preparations.

*a* A tooth prepared as a bridge abutment. Only a small amalgam restoration was present. The buccal margin is a bevelled shoulder, the palatal margin is a chamfer finishing line and the entire margin is supragingival.

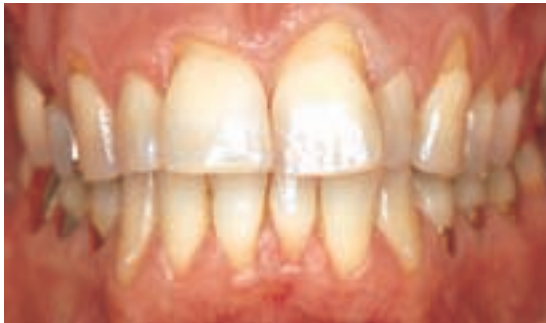
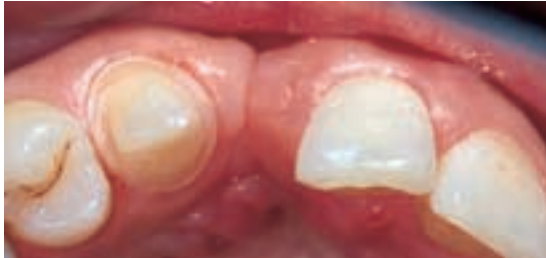
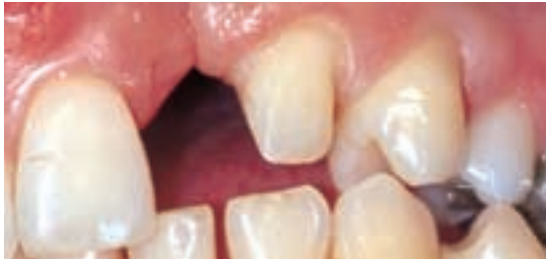*b* and *c* A typical metal–ceramic crown preparation on a root-filled tooth with a post-retained amalgam core. Note the amount of occlusal clearance. The axial wall has been finished smooth but the occlusal surface has not. This is of little significance, except that the mesial and distal corners of the occlusal surface should have been rounded.

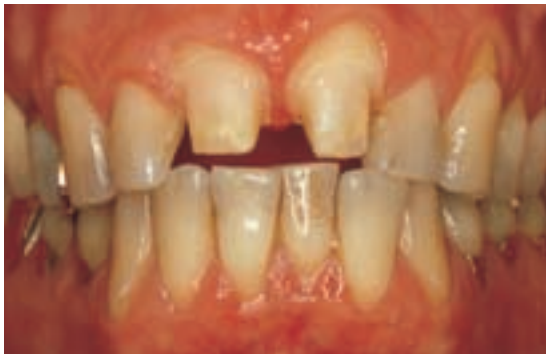**Figure 3 17**

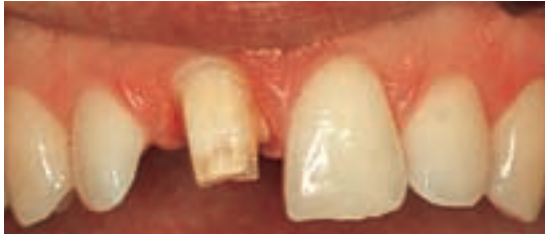Anterior crown preparations.

*a, b and c* Ceramic crown preparation on an incompletely erupted tilted upper canine tooth in a patient with a repaired cleft palate. The final crown will be a retainer for an all ceramic cantilever bridge. The crown will have a very different alignment and appearance to the unprepared tooth. There has been almost no enamel removed from the incisal edge and the adjacent buccal surface. A trial preparation on a study cast is essential with this type of problem (see later).

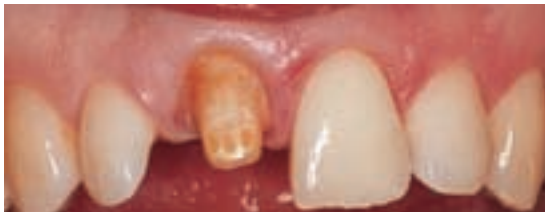

*d and e* The objective is to reduce the size of the upper central incisors. Preparations in *c* are as extensive as possible, allowing ceramic crowns to be constructed that are narrower and less prominent than the natural teeth, except at the neck.

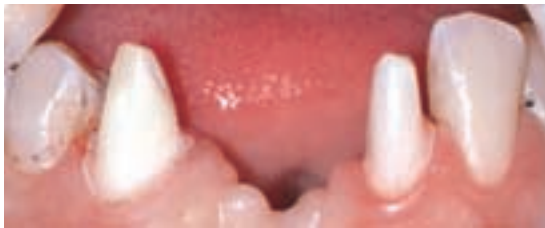



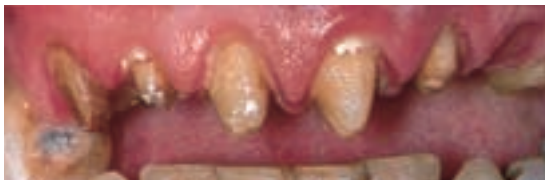*f* An inadequate ceramic crown preparation. The previous crown had broken. The angles of the preparation are too sharp and there is insufficient reduction for an adequate thickness of porcelain for strength and appearance.



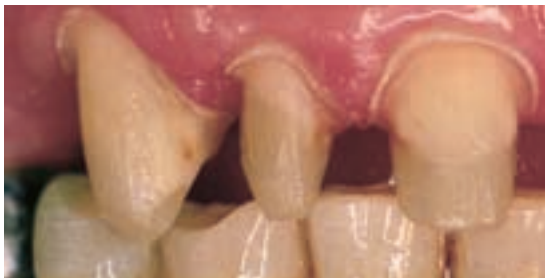*g* The preparation shown in *f* modified for a ceramic crown. Note the rounded external and internal angles and the greater reduction.



*h* Metal-ceramic crown preparations to retain a bridge on the lower incisor and canine teeth. Although retentive, these preparations are very destructive and a minimum-preparation design would normally be used.



*i* Totally inadequate preparations on a number of upper anterior teeth. The preparations are over-tapered, all except the central incisors are far too short, and the surfaces are too rough. All these restorations failed with disastrous consequences.

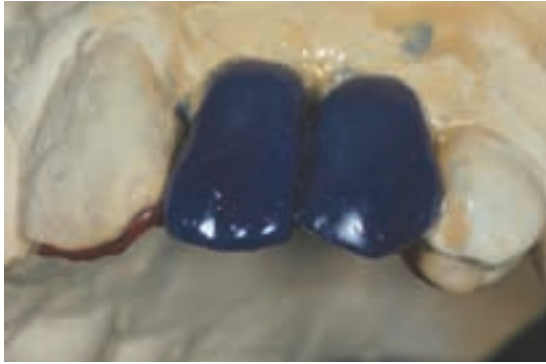


*j* Metal-ceramic crown preparations on badly worn incisors that have been built up with composite cores (the same patient as in Figure 5.6).

- The sharp edges of the die may be damaged at the wax-up stage.
- Investment material may not flow adequately into the wax pattern, producing air bubbles in the internal angles of the wax pattern which

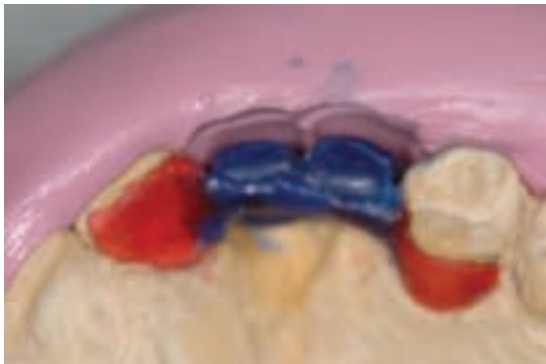
produce blobs of metal in the casting, preventing it from seating fully (Figure 3.14).

- Cement will flow less readily around sharp angles, increasing the likelihood of an unnecessary thick cement layer at the margins.



**Figure 3.18**

*a* A full contour wax-up of a minimum-preparation bridge on the master cast.



*b* A silicone putty mask has been made from the wax-up which is then cut back to allow space for the porcelain to be placed. Once cast this ensures that the porcelain will be properly supported by the metal frame.

## Designing specific crown preparations

The principles outlined above are common to all preparations. Some are more important than others, however, with different types of crown.

### Posterior complete crown preparations

#### All-metal crowns

Whether the preparation is on a natural tooth or an artificial core, application of the principles will usually result in preparations as shown in Figure 3.15.

Variations include additional axial grooves or pinholes to limit the path of insertion when a pair of opposing walls are more tapered than is desirable.

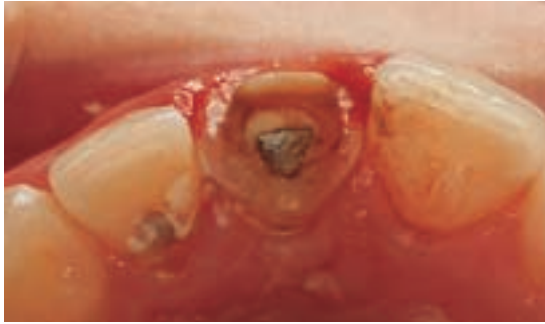#### Metal–ceramic crowns

Posterior metal–ceramic crown preparations will usually have an all-metal lingual surface and a porcelain buccal surface, and may have a porcelain occlusal surface. The decision where to finish the porcelain will influence the preparation. The margin may be a deep chamfer or a bevelled shoulder to allow a small line of metal to show, simplifying the finishing of the crown margin (Figure 3.1f). In the posterior part of the mouth this appearance is usually acceptable. Figure 3.16 shows typical posterior metal–ceramic preparations.

### Anterior crown preparations: crowns for vital teeth

#### Ceramic crowns

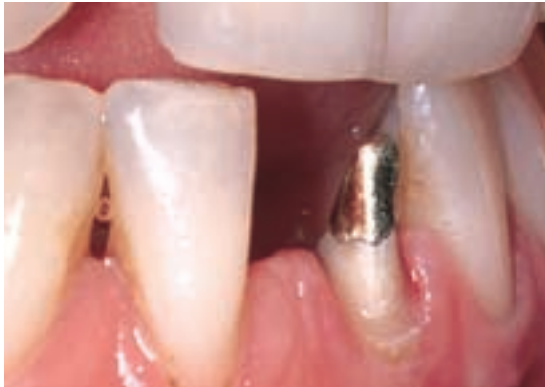A series of ceramic crown preparations is shown in Figure 3.17, demonstrating the application of



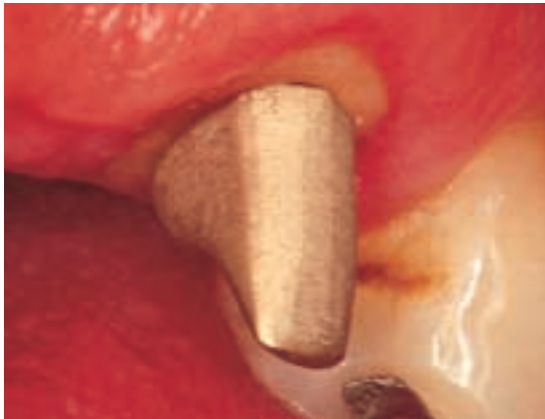**Figure 3.19**

Posts and cores.

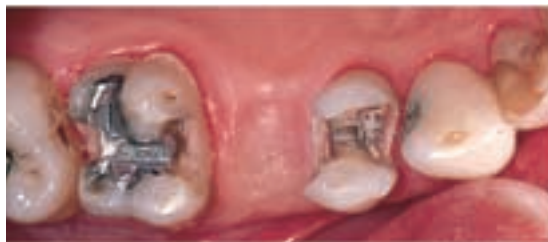*a* A stainless-steel post has been cemented and cut off flush with the palatal surface of the preparation, preserving as much dentine as possible. See also Figure 6.14.



*b* A cast post and core with a substantial amount of dentine remaining as part of the preparation.



*c* A cast post and core with no coronal dentine.

**Figure 3.20**

A posterior partial crown preparation for an upper first molar tooth. Mesial and distal boxes have been prepared rather than grooves since there was a previous MOD amalgam. The occlusal groove has been prepared through the remaining amalgam. The stained dentine is firm, and further removal is unnecessary. The tooth has been prepared as an abutment tooth for a bridge, which will be fixed-movable (see Chapter 8).

the principles in a variety of cases, including lower incisor teeth. In all but Figure 3.17i, the crowns will be retentive and there is sufficient tooth reduction to enable a crown to be made of adequate thickness for strength and appearance.

### Metal–ceramic crowns

Figure 3.17 also shows preparations for metal–ceramic crowns. Compared with ceramic crown preparations, the buccal reduction is greater and lingual reduction less where possible. A deep chamfer margin is required on the labial aspect extending into the proximal areas merging into a shallow chamfer margin palatally where only metal is to be placed. This is more important mesially where the porcelain will show than distally where it will not.

The metal should also support the porcelain so that excessive thickness of porcelain is avoided. Ideally a metal–ceramic crown or bridge should be waxed up to a full contour and then cut back to allow optimal porcelain thickness for an ideal appearance and yet preserving sufficient metal for strength (Figure 3.18).

### Post-retained crowns

The shapes of post holes were described in Chapter 2. The margin of the crown preparation will be similar to that for a vital crown of the same material but the difference is that in the case of a post crown there is no pulp to protect, and therefore the shoulders can be wider and the

core thinner than for an equivalent vital tooth preparation. This is possible not only because of the absence of a pulp but also because the core material is either reinforced by a preformed metal post or the whole post and core is cast (Figure 3.19) and is therefore stronger than dentine. Besides, a laboratory-produced core can be made more parallel-sided and retentive than a clinical preparation.

The dentine remaining between the post hole and the shoulder, or other margin, may be retained or removed, depending upon its thickness. With a preformed post and composite core, virtually all the dentine can be saved (Figure 3.19a and b). The advantage in retaining a collar of dentine around the post hole when a cast post and a core is to be made is to guide the technician in the dimensions of the core required. The rim of dentine also slightly lengthens the post and improves the retention of the whole restoration (Figure 3.19b).

### Posterior partial crown preparation

A typical posterior partial crown is much like a complete gold crown except that the buccal wall of the tooth is left unprepared. This means that the crown can be inserted or lost not only from the occlusal direction but also lingually. A posterior partial crown must therefore incorporate features that will prevent lingual loss, usually mesial and distal grooves connected by an occlusal groove, the important area being the lingual wall of the groove (see Figure 2.7 and Figure 3.20). With other types of posterior partial crowns, similar grooves or pins are used.

**WWW.HIGHDENT.IR**

همیار دندانسازان و دندانپزشکان

## 4

# Occlusal considerations

There are excellent textbooks on occlusion, and the reader who has studied these will be forgiven for skimming this chapter. For those who are not yet conversant with the principles of occlusion, this short explanation together with the practical techniques for recording and reproducing occlusal relationships is intended as an introduction to the subject. It will be sufficient for making crowns and bridges for patients with no functional disturbances or pathological changes in the temporomandibular joint or the oro-facial musculature and no major occlusal abnormalities, i.e. most patients. For more difficult occlusal problems the reader is referred to the comprehensive texts.

For many years there has been considerable interest in normal and abnormal occlusions and in the effects of abnormality. There is a rapidly expanding literature, both research-based and empirical. An unfortunate side-effect of this enthusiasm is that the whole subject seems to be confused in some dentists' minds with the use of complex articulators, recording devices and expensive full mouth 'rehabilitations'. The 'all or nothing' law seems to apply, with some dentists apparently blaming most of the human race's ills, and all of its dental ones, on the odd aberrant cusp, while some others remain unconvinced, throwing the baby out with the bath water – paying little or no attention to occlusal relationships other than when a filling or crown is 'high in the bite'.

An understanding of a few simple principles of occlusion related to natural teeth and in particular how to examine occlusions encourages a middle course between these extremes and will be of great value in preventing some of the failures that occur with restorations that replace occlusal surfaces.

Elaborate equipment is unnecessary for the application of these principles to the restoration of small groups of teeth; equipment should be seen simply as a means to an end. In fact, the

principles determining the design of articulators and recording devices are fairly simple, but their conversion into three-dimensional reality leads to the complexity of the equipment.

## A functional approach to occlusion

The most useful way for a restorative dentist to look at occlusion is from the functional point of view; the morphological details of the occlusion are less important. The fact that an occlusion is Angles Class I, II or III is less important than the way the teeth move across each other in various movements of the mandible. For example, in lateral excursions in some patients, the canines are the only teeth in occlusion, and in others several of the teeth are in occlusion (Figure 4.1).

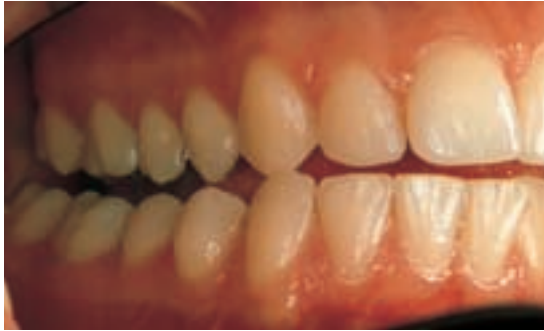The restorative dentist should also recognise that crowns, bridges or any restorations involving the occlusal surface will often affect the way the occlusion functions. This effect should be deliberately planned rather than be allowed to influence the occlusal movements by accident.

## The functional compared with the orthodontic approach

Orthodontic treatment is aimed primarily at improving the patient's appearance and producing a stable posterior occlusion in a single static position. Some forms of orthodontic treatment go further and establish deliberate patterns of contact between the teeth in various movements of the mandible.

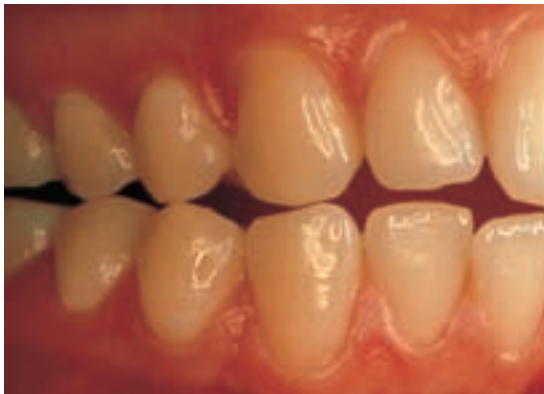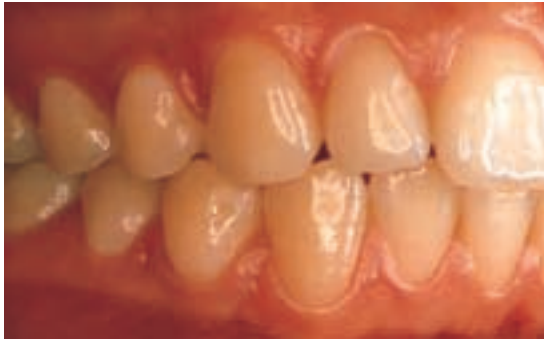Most orthodontic treatment is carried out on young people who have not yet developed rigid patterns of involuntary neuromuscular control of their mandibular movements. They are therefore



**Figure 4.1**

Lateral guidance.

*a* Canine guidance in right lateral excursion with the posterior and incisor teeth completely disclusing. Contact in this position is sometimes shared between the canine, lateral and central incisor teeth – incisor or anterior guidance.



*b* and *c* Group function. The patient is shown, *b*, in intercuspation position, and when she moves to the working side, *c*, contact is shared between the posterior teeth. The lateral and central incisors disclude.

capable of adaptation to fairly drastic changes in their occlusal relationships in a way that some older patients find difficult.

From the functional point of view there should be no difference in the objectives of the orthodontist and restorative dentist – only different means of achieving them.

### ***Fixed compared with removable prosthetic approaches***

The main purpose of designing the occlusion for complete dentures is to produce stability of the denture bases. This is an entirely different concept from the restoration of natural teeth with intact

roots and periodontal membranes. Occlusal considerations for partial dentures fall somewhere between these two positions. In complete denture construction, consideration of where the occlusal surfaces of the artificial teeth should be in relation to the ridge, the presence of balancing contacts on the non-working side, and the angulation of cusps or absence of cusps altogether, are important. None of these applies in the same way to the construction of fixed restorations.

The methods of recording and reproducing mandibular movement are similar whether fixed or removable appliances are being made. However, the principles governing the design of the occlusal relationships, although similar in some respects, are different in others.

### **Mandibular movements and definition of terms**

The movements that the mandible can make and the names of the important positions within this range of movements are shown in Figure 4.2.

#### ***Terminal hinge axis (THA) and the retruded arc of movement (or closure)***

This is an axis which passes through both condyles and about which the mandible rotates in its most retruded (comfortable) position of the condyles – the retruded arc of closure. This is a clinically reproducible movement and recording it is often useful in making crowns and bridges and essential in making complete dentures. The THA can be measured in individual patients but it is sufficient for most applications to use an average THA such as that recorded by an ear-bow, as shown later in Figure 4.10.

#### ***Intercuspal position (ICP)***

This is the position of maximum contact and maximum intercuspatation between the teeth. It is therefore the most cranial position that the mandible can reach. The term ‘centric occlusion’

has been used to describe this position, but this is confused with ‘centric relation’ (see below) and may also imply centricity of the condyles in their fossae, centricity of the midline of the mandible with the midline of the face, or centricity of the cusps within the fossae of the opposing teeth, none of which may be the case. The term ‘centric occlusion’ is therefore better not used.

#### ***Retruded contact position (RCP)***

This is the most retruded position of the mandible with the teeth together. It is a clinically reproducible position in the normal conscious patient. Patients with conditioned patterns of muscle activity may not be able to manipulate the jaw into it, even with assistance by the dentist. In less than 10% of the dentate population the RCP coincides with the ICP. In the remainder the RCP is up to 2 mm or more posterior to the ICP. The term ‘centric relation’ has been used to describe this position, but it has the same disadvantages as the term ‘centric occlusion’ and will not be used. ‘Centric occlusion’ (CO) and ‘centric relation’ (CR) are terms sometimes used in complete denture construction where they mean different things to ICP and RCP.

#### ***Mandibular movements***

Those patients who have a discrepancy between the RCP and ICP usually close straight into the ICP from the postural or rest position when the movement is made subconsciously. Patients sitting in dental chairs making voluntary, conscious movements when asked to do so by the dentist often make bizarre movements rather than closing into the ICP directly. These aberrant movements and contacts are the result of patients trying too hard to help and not understanding what is required. Students have been heard to ask non-dental or medical patients to bite on their ‘posterior’ teeth!

However, contact does occur in the range between the ICP and RCP during empty swallowing (particularly nocturnal swallowing), during the mastication of a tough bolus and during parafunctional activity. Thus the mandible can slide from

the ICP in four main directions with the teeth in contact, or in an infinite number of directions at angles between these main pathways. The four excursions are:

- retrusive
- protrusive
- left lateral
- right lateral.

### Retrusive movements

Movements between the ICP and RCP are usually guided by a limited number of opposing pairs of cusps of posterior teeth. Figure 4.3a, b and c illus-

### Figure 4.2

Border movements of the mandible.

*a* The maximum possible movement of the tip of a lower central incisor. The teeth are in occlusion from RCP to the fully protruded position (P). In opening from RCP to X, the mandible rotates in a pure arc of a circle around an axis (the terminal hinge axis, THA), which passes through the condyles. X is the maximum opening that can be made without the condyles moving forwards and O is the maximum opening with the condyles fully protruded.

*b* The view from above, showing RCP and ICP. The movements are not pure arcs of circles, because when the mandible moves to the side the condyle on the working side shifts laterally (Bennett movement) and the condyle on the non-working side moves forwards and medially (Bennett angle).

*c* The border movements viewed from in front. The movement from ICP to the cusp-to-cusp contact (C) is guided either by canines, all the anterior teeth or a group of posterior teeth (see Figure 4.1). From C to the maximum lateral position, L, the guidance is irregular and usually controlled by the anterior teeth or teeth on the non-working side. This is a non-functional range not usually involved in parafunctional activity, and is therefore of little importance.

*d* Changes in the lateral guidance will either expand the

trates the occlusal contacts produced in RCP and other excursions in a typical natural dentition. The angle of the slide between RCP and ICP, its length and the individual pairs of teeth that produce it are important and should be examined. Of even greater importance is any unevenness of the movement producing bulges or lumps in the path of movement. These disturbances to the smooth movement of the mandible are one form of occlusal interference (see page 83).

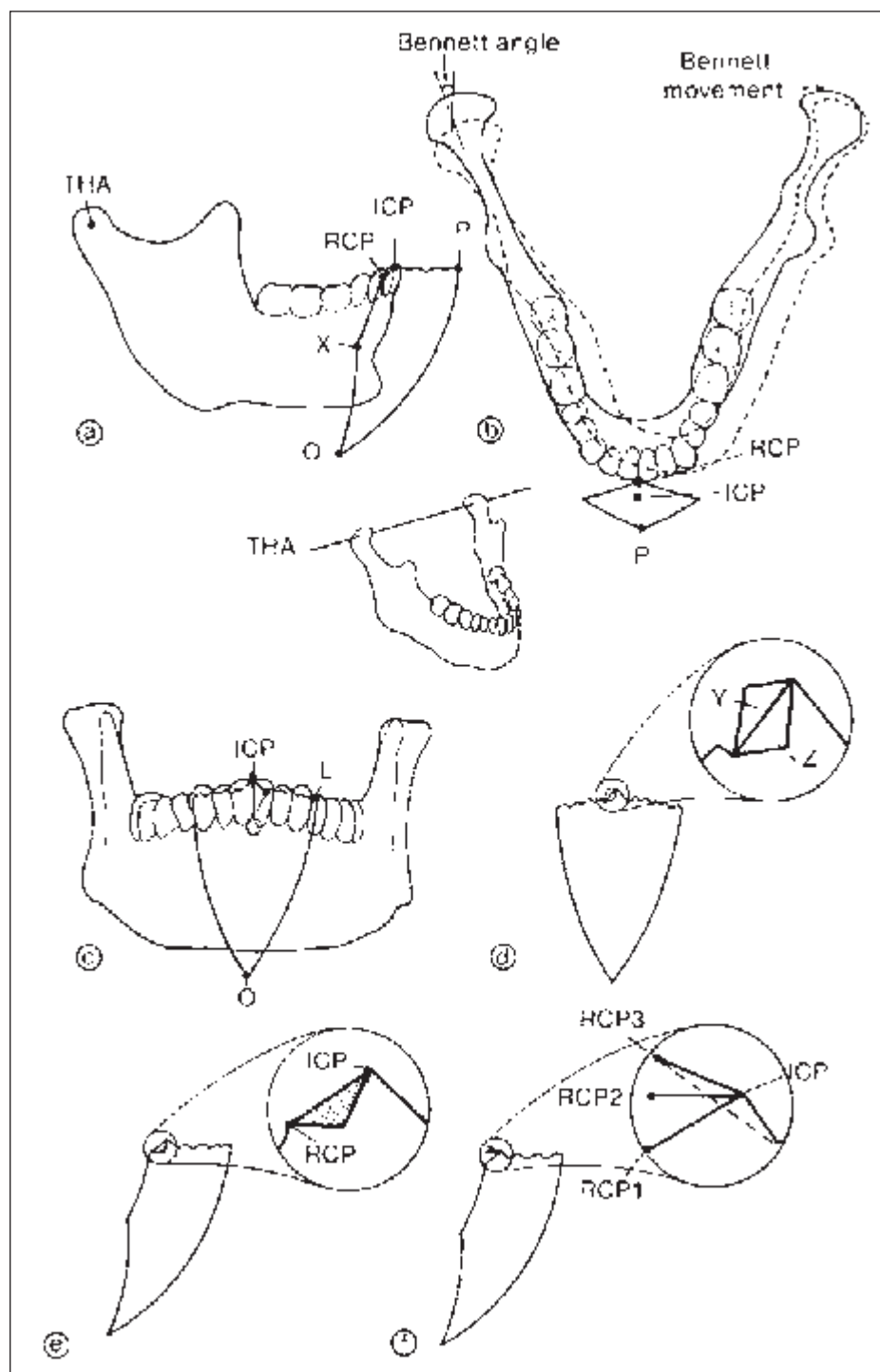
### Protrusive excursion

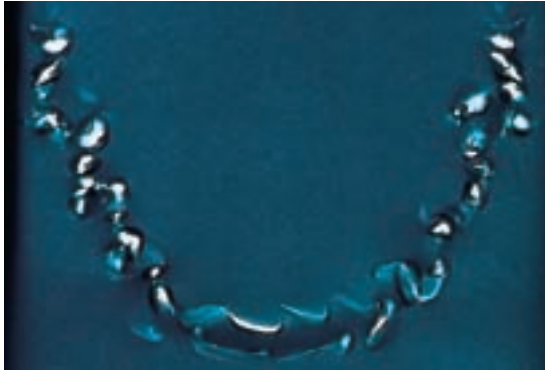
In forward movement of the mandible with the teeth together. It is usually the incisor teeth that

original border movement – Y, or encroach upon it – Z. Both changes constitute occlusal interferences. The change, Y, would result, for example, from the fracture or extraction of a canine tooth that previously governed lateral guidance. The change, Z, might result from overbuilding the cusps of a posterior crown in a group function occlusion or from the development of non-working side contacts.

*e* This occlusal interference, an irregularity developing in the smooth movement from ICP to RCP, may also result from crowns. An example of extraction and over-eruption causing this change is shown in Figure 4.4.

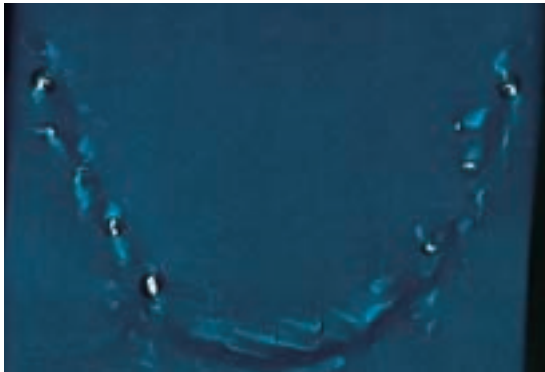
*f* An expansion of the border movement is often an objective of occlusal adjustment in the range from ICP to RCP. For example, if the original movement was from ICP to RCPI, with large vertical and horizontal components to the movement, an adjustment could be carried out to produce a 'long centric', so that the movement was flat from ICP to RCP2. This would not change the horizontal component of the movement, but would reduce the vertical component to zero. The alternative of making ICP and RCP coincident (RCP3) usually involves multiple crowns or other restorations as well as occlusal adjustment. This is because either the border movement space needs to be encroached upon (the dashed line) or a substantial amount of tooth tissue must be removed. When this is done the process is known as 'reorganizing' the occlusion. If ICP is left undisturbed, the occlusal plan is known as 'conformative'.



**Figure 4.3**

Occlusal contacts.

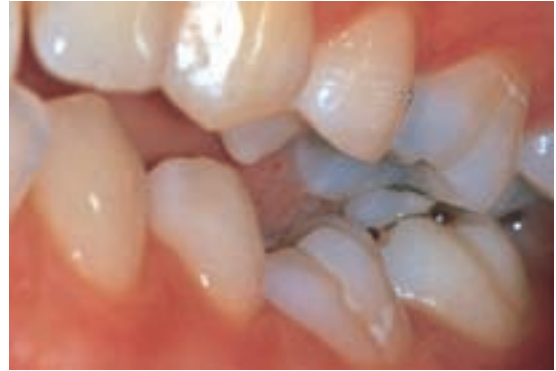*a* Perforations in a 0.5-mm-thick sheet of soft wax produced by the patient closing in ICP.



*b* The same patient contacting in RCP. There are of course fewer contacts, but they are evenly distributed, both antero-posteriorly and between left and right.



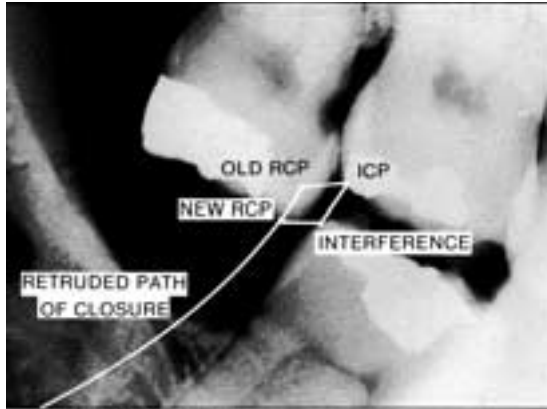
*c* The same patient making contact in right lateral excursion, mainly on the canine teeth, although a contact is also present posteriorly.



*d* A different patient making a right lateral excursion. The left (non-working) side is shown, and there is contact between the lower second molar and the first upper molar. This is a non-working-side occlusal interference.



*e* A wax occlusal record of the patient shown in *d* in the same right lateral excursion, showing this interference to be the only contact at this point.

**Figure 4.4**

Since the lower third molar has been extracted, the upper third molar has over-erupted, changing the RCP. Previously the mandible could slide smoothly back from ICP to RCP, but it now has to make a detour to the new RCP to circumnavigate the mesial surface of the upper third molar. This is an occlusal interference. This patient presented with pain diagnosed as mandibular dysfunction, which disappeared once the upper third molar had been extracted. Caries, although present in the mesial surface of the upper third molar well below the original contact point, was not the cause of the pain.

guide the movement. This will not be the case in anterior open bites or in Class III incisor relationships.

The angle and length of movements will be determined by the incisor relationship so that, for example, in a Class II Division II incisor relationship with an increased overbite and reduced overjet, the movement of the mandible has to be almost vertically downwards before it can move forwards. Anterior guidance is important when making anterior crowns or bridges. Sometimes, when the teeth are a normal shape, it is helpful to reproduce the patient's existing guidance as accurately as possible; on other occasions, for example, with worn teeth, it is unnecessary or undesirable to do so, and in fact the purpose of the treatment may be partly to alter the incisor guidance.

### Left and right lateral excursions

In lateral excursions the side that the mandible is moving to is known as the working side and the opposite side the non-working side. The term 'balancing side' has been used to refer to the non-working side, but since it implies a balanced occlusion, balancing or stabilizing a complete denture base, it should not be used in reference to natural teeth.

The contacts on the working side are either between the canine teeth only (canine-guided occlusion, Figure 4.1a) or between groups of teeth on the working side (group function, Figure 4.1b and c). Occasionally, individual pairs of

posterior teeth will guide the occlusion in lateral excursion, but this is not regarded as ideal. The canine-guided occlusion is considered to be protective of the posterior teeth which disclude in lateral guidance.

Contact on the non-working side in lateral excursions should not normally occur. It does sometimes occur after extractions and over-eruption and occasionally following orthodontic treatment, particularly when this treatment has been carried out with removable appliances that have allowed the posterior teeth to tilt (Figure 4.3d and e). Contact may also occur in cases of posterior crossbite where the lower teeth are placed buccally to the upper teeth.

## Occlusal interferences and occlusal harmony

### Occlusal interferences

An occlusal interference may be defined either as a contact between teeth in one of the excursions of the mandible so that the free sliding movement of the mandible is interrupted or uneven, or as the guidance of the mandible being carried on teeth that are unsuitable for the purposes. In many cases occlusal interferences develop some time after the eruption of the permanent dentition and are the result of dental treatment.

Figure 4.4 illustrates an alteration to the movement between ICP and RCP resulting from

the over-eruption of a tooth. This constitutes an occlusal interference in this excursion. Figure 4.3d and e illustrates an interference in lateral excursion.

These interferences are often difficult to detect because the sensory mechanism within the periodontal membranes of the teeth involved detects the interference and triggers a conditioned pattern of mandibular movement to avoid it. This accounts for the difficulty many patients have in permitting their mandible to be manoeuvred into the RCP and also the difficulty they have in voluntarily making lateral excursions with the teeth together.

An interference in the intercuspal position resulting from a 'high' restoration involving the occlusal surface will be readily detected by the patient, who will usually comment on an occlusal change as soon as the restoration is inserted. These instant, entirely artificial interferences are obviously easier to deal with than occlusal interferences in the various excursions of the mandible – which may be artificial but can also develop slowly and naturally following extractions, tooth movements, occlusal wear and over-eruption.

Interferences should be suspected if the patient has difficulty in making voluntary protrusive and lateral excursions with the teeth in contact or there is difficulty in manoeuvring the mandible into a reproducible RCP. Interferences can also be detected by the dentist resting a finger gently under the patient's chin while the various excursions are performed. Irregular movements, which the finger will feel, indicate interferences that need fuller investigation.

### **Occlusal harmony**

Occlusal harmony is the absence of occlusal interferences. A harmonious occlusion allows smooth comprehensive movements of the mandible in all excursions with the teeth together without strain or discomfort. The movements will not cause harmful effects to the teeth (for example tooth mobility, fractured cusps or excessive wear). A harmoniously functioning occlusion will usually also involve fairly shallow angles of movement in the guidance from ICP in all four directions.

Patients who do not have free sliding movements may not have symptoms. They have

adapted to their occlusal interferences and there is no need for treatment. However, if the occlusion is altered to produce new and different occlusal interferences (for example by unsatisfactory crowns or bridges), the patient's neuromuscular mechanism may well experience difficulty in adapting to these, resulting in damage to the restorations or teeth, or a dysfunctional disorder leading to temporomandibular joint pain, muscle pain and spasm, or postural and functional problems. These disorders arising from occlusal disharmony are described later and are more fully described in specialist textbooks.

### **'Premature contact'**

The term 'premature contact' should not be used in relation to the natural dentition – only with complete dentures. With complete dentures there is no natural ICP, and ICP and RCP are made to coincide, i.e. the artificial teeth interdigitate on the retruded path of closure. The patient learns, subconsciously, to close on this reproducible path of closure and closes into intercuspatation. When, as a result of inaccurate occlusal records, the ICP and RCP of the complete dentures do not coincide, the patient may close on the retruded path of closure, and then may slide into maximum intercuspatation or alternatively the dentures may move. This is known as 'premature contact' and is clearly unsatisfactory. The artificial teeth do not have a periodontal proprioceptive system, and so the position of an artificial ICP cannot readily be detected. With a natural dentition the ICP is well recognised by the neuromuscular mechanism and the mandible closes directly into ICP in the great majority of involuntary closing movements. It may not do so in the artificial environment of the dental chair when the mandible is brought under voluntary rather than involuntary control. In these circumstances, even if the first contact appears to be a premature contact, this should not be assumed to be the normal pattern of closure, but only the result of the patient concentrating on a movement that is usually entirely automatic.

For these reasons the term occlusal interference as defined and described above should be used for the dentate patient and not 'premature contact'.

### **Occlusal stability (not the same as harmony)**

A stable occlusion is one in which over-eruption, tilting and drifting of teeth cannot occur and therefore cause new occlusal interferences. For an occlusion to be stable, there must also be sufficient posterior contacts to prevent a general collapse of the posterior occlusion resulting in a loss of occlusal vertical dimension. Figure 4.5 shows a disordered but stable occlusion, a disordered and unstable occlusion, and an occlusion that has lost posterior support to the point where collapse and loss of occlusal vertical dimension has occurred.

In a stable occlusion all the teeth should have occlusal contact with either another tooth or a prosthesis (occlusal stops). Mesial drifting should be prevented by the presence of contact points, either with other teeth or a prosthesis, or by adequate cuspal locking with the opposing teeth in intercuspal position.

Not all partially edentulous occlusions are unstable. For example, if all the molar teeth are extracted, the remaining teeth may still be in stable occlusion. Therefore extracted teeth are not always replaced (see Chapter 7). In any case, a degree of instability is sometimes acceptable.

### **Occlusal vertical dimension (OVD)**

The occlusal vertical dimension is the relationship between the mandible and the maxilla with the teeth in ICP, that is, the face height with the teeth in occlusion. It is usual to measure the difference between rest position and ICP (the freeway space) to give an indication as to whether the OVD is within the normal range. However, rest position is difficult to measure with any precision, particularly in dentate patients, and the normal freeway space may be 2–5 mm or more. OVD is therefore judged as much as it is measured by the patient's general facial appearance with the teeth together and apart. In most cases requiring crowns or bridges the OVD is satisfactory. In some it has been reduced by the extraction of teeth, by tilting, drifting and collapse of the posterior occlusion or by rapid wear of the teeth (Figures 4.5c and d and 5.5a). In these it is necessary to restore the original occlusal level for both

aesthetic and technical reasons. In other cases gradual wear of the dentition has resulted in very short teeth so that making aesthetic and retentive crowns is a problem, yet there is no loss of facial height because the tooth wear has been compensated by over-eruption. In these cases a decision must be made between:

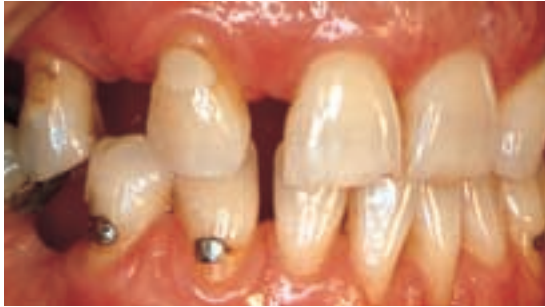- Accepting that the natural or artificial crowns will have a short appearance
- Creating interocclusal space between the teeth to be crowned without altering the other occlusal relationships
- Artificially increasing the OVD by restoring or replacing all the occlusal surfaces in one or both jaws
- Artificially lengthening the clinical crowns by gingival surgery and sometimes alveolar surgery (crown lengthening)
- A combination of these approaches.

When a change in OVD is planned, whether or not it is to restore lost facial height, it is usual to assess the tolerance of the patient's neuromuscular mechanism to the change. A removable acrylic plate covering all the occlusal surfaces of one arch and increasing the OVD by at least the same amount as is proposed for the final restorations may be fitted. Alternatively the teeth may be temporarily built up with composite, amalgam or temporary crowns. The temporary adjustment to the OVD should be left for several weeks to ensure that problems do not arise with the neuromuscular mechanism or the teeth before the change is made permanent (Figure 5.6, page 116).

### **Creating interocclusal space for teeth to be crowned**

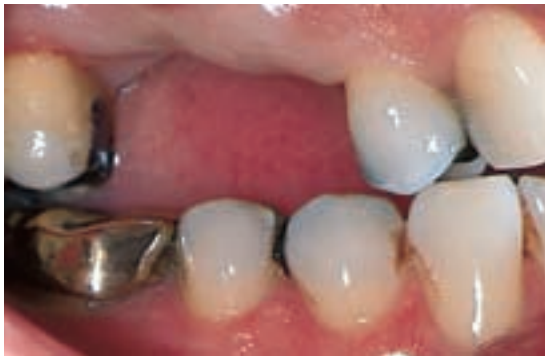In certain circumstances, particularly extreme wear of anterior teeth, it is helpful to carry out minor orthodontic treatment to enable crown preparations to be carried out without further preparation of the worn surfaces. Often the wear has been sufficiently slow that over-eruption has kept pace with it, carrying the gingival margin along with the over-eruption. Conventional orthodontic treatment can be used, but a simple, reliable and rapid technique is to use either a



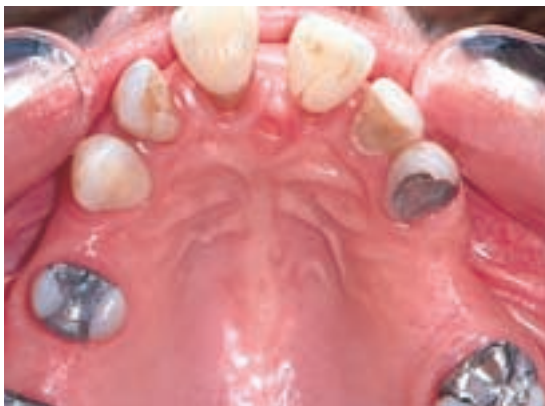**Figure 4.5**

Occlusal stability.

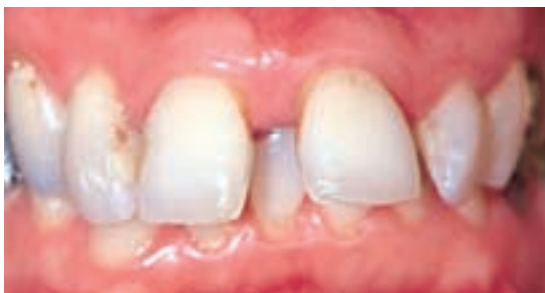*a* A disordered but stable occlusion. Several teeth are missing and there have been a number of tooth movements, some producing aesthetic problems and potential occlusal interferences. However, the occlusion is now stable and study casts taken 5 years before this photograph show that no change has occurred in that period. There are no symptoms of mandibular dysfunction and no other complaints by the patient, even of the appearance of the missing upper teeth. Treatment of this occlusion is therefore not justified.



*b* There have been recent extractions in the upper arch and undesirable tooth movements, including over-eruption of the lower teeth, can be anticipated.



*c* and *d* A 'collapsed bite' with loss of a number of posterior teeth, periodontal disease, drifting upper incisors, an increase in overbite and a reduction in occlusal vertical dimension.



removable or fixed appliance commonly known as a 'Dahl' appliance. Dahl originally described a removable anterior biteplane made of cast cobalt-chromium but modern adhesive technology has enabled a simpler fixed appliance to be made that is well tolerated by most patients and that usually achieves the required result in about 3 months. Figure 4.6 shows the appliance in use.

Alternatively the same effect can be produced by building up the teeth with composite or by preparing the teeth and fitting acrylic provisional crowns, made in the laboratory, which are high in the occlusion.

## Temporomandibular dysfunction (TMD)

Many terms are used to describe this condition, for example mandibular dysfunction, craniomandibular dysfunction, temporomandibular joint dysfunction, myofascial pain dysfunction syndrome, muscle hyperactivity disorder and others. This illustrates the fact that the condition is poorly understood and that there are many suggested explanations for it. Some explanations blame the joint itself for the symptoms, some the muscles of mastication and their control systems, and some the occlusion, which in turn affects the control system and again in turn the muscles and the joints. Some clinicians believe that the symptoms arise mainly or entirely from psychological stress and anxiety.

The least pejorative term is therefore 'temporomandibular dysfunction (TMD)', which is simply used to label a common combination of symptoms often including tenderness, pain and tension in the muscles of mastication and pain, clicking and limitation of movements of the temporomandibular joints.

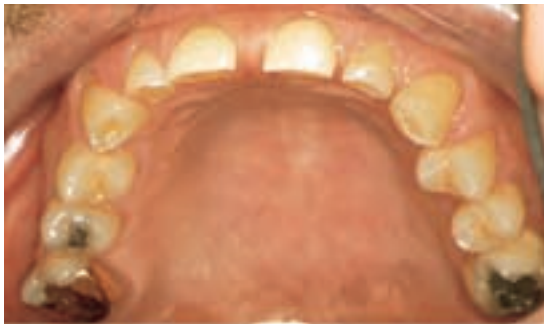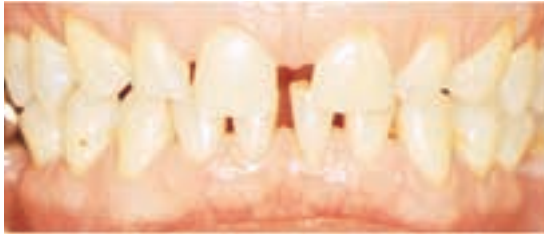In many cases the symptoms resolve spontaneously with or without treatment. The reported incidence is higher in young adult female patients than in other groups. These two facts suggest that the condition is more commonly of functional and psychogenic origin than it is to do with irreversible physical changes in the joints themselves.

Changes do occur in the joints, and these can be demonstrated by conventional radiographic techniques designed for the purpose or by magnetic resonance imaging (MRI), which does

not involve ionizing radiation or physical invasion of the joint. When MRI is available (it is a very expensive technique) it is the best way to investigate the possibility of internal joint derangements or pathology. Confusingly, MRI surveys of normal patients with no symptoms of TMD have shown that a significant proportion of them have displaced discs within the temporomandibular joints, which, when such displacements were discovered by the previous, invasive techniques (which could only ethically be used on patients with symptoms) were considered to be the cause of the symptoms. Undoubtedly some of these internal joint derangements, or more frank pathology of the joints, do cause symptoms similar to those arising from the purely functional disorder: TMD.

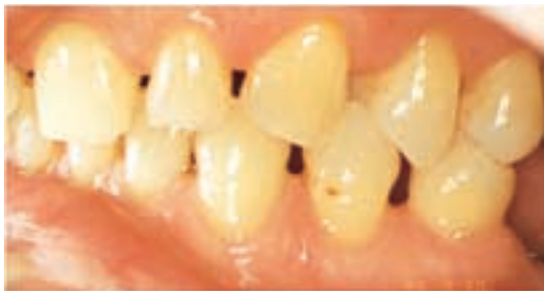There are clearly cases in which the cause of the symptoms is dysfunction, others in which there is some organic, physical explanation and many where the cause is less clear. Sadly some dentists align themselves with one or other of the rather narrow and exclusive regimes for the management of mandibular dysfunction. This is unfortunate and unscientific. With different schools of thought about the aetiology and management of mandibular dysfunction, each supported by some, but incomplete, research evidence, the sensible dentist will keep an open mind. However, some lines of treatment are more interventive than others and so it is wiser to take a conservative approach to the management of mandibular dysfunction and assume that, in the absence of firm evidence to the contrary, most cases of mandibular dysfunction are functional rather than organic in nature.

An attractive hypothesis is that occlusal interferences (described on page 83) produce conditioned patterns of muscle activity that avoid these interferences. This increases the basic level of muscle activity, which, when it is further increased by anxiety or stress, brings the level of muscle tension above a threshold and symptoms develop. Therefore treatment aimed at removing the occlusal interferences is aimed at the cause of the problem rather than the symptoms. Similarly, treatment aimed at reducing anxiety and stress is also aimed at the cause, but this should be limited to sympathy and explanation of the cause together with a caring approach to treatment rather than, in the hands of the general dental practitioner, the use of drugs.

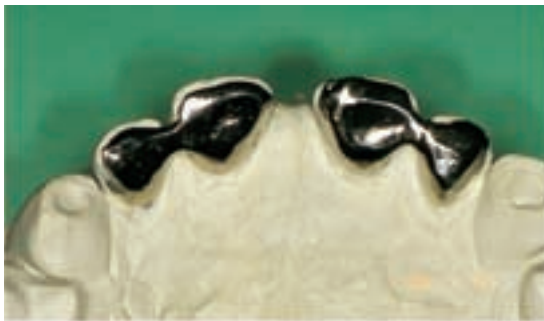

**Figure 4.6**

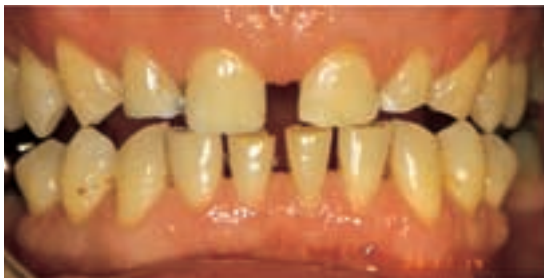*a* and *b* Palatal erosion affecting the upper incisor teeth. The lower teeth have over-erupted and are making contact with the worn palatal surface.



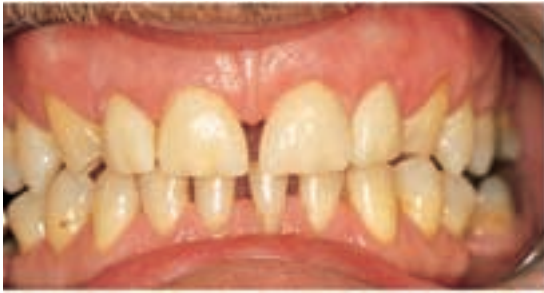*c* The posterior teeth in occlusion.



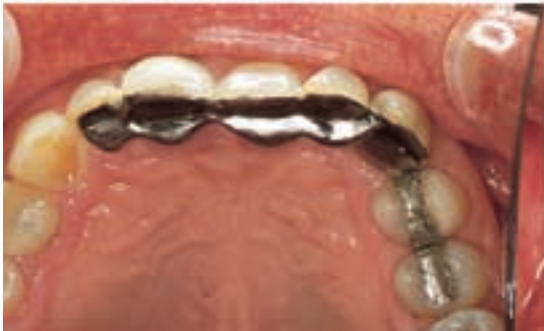*d* The cast Dahl appliances. They are left separate at the midline because of the diastema.



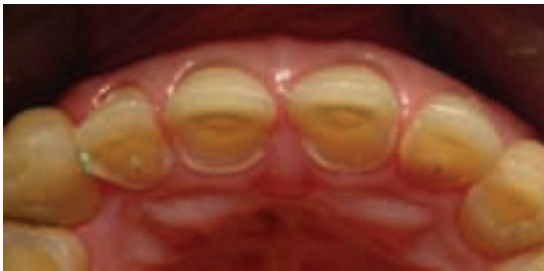*e* The Dahl appliances in place propping the occlusion open on the anterior teeth.



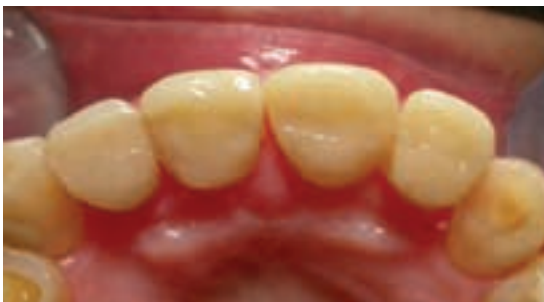f The appliances have worked in depressing the lower incisors and the four upper incisor teeth have been crowned without any further reduction of their palatal surfaces.



g Another typical Dahl appliance, this time in one piece and with a more pronounced shelf palatally to produce axial tooth movement.



h Reflux erosion with considerable loss of anterior OVD.



i Directly placed composite to give a Dahl effect. This has the advantage that it can be adjusted while it is working but it needs more maintenance than a cast appliance.

Occlusal interferences are not always easy to detect clinically because of the set of conditioned reflexes that avoid contact on the occlusal interference. A simple way to detect whether alteration of the occlusion is likely to reduce the symptoms of mandibular dysfunction is to provide a hard

acrylic biteplane covering all the surfaces of one jaw (sometimes called a Michigan splint when it is made for the upper jaw, and a Tanner appliance when in the lower jaw). If the symptoms improve after a few weeks of wearing the appliance at nights (or all day if it is tolerated) then this is a

clear indication that the occlusion has something to do with the symptoms and justifies the expenditure of further time and effort on identifying and dealing with the occlusal interferences.

The acrylic biteplane should be used in this diagnostic way rather than as a long-term treatment of the condition. However, some patients, despite advice given to them, continue to wear the appliance because it has reduced their symptoms, and for this reason biteplanes making contact with only a limited number of anterior or posterior teeth should not be used. If they are, they will act as orthodontic appliances and produce unplanned and damaging depression or over-eruption of teeth.

The treatment of occlusal interferences in the management of mandibular dysfunction is usually fairly simple once the interference has been identified. It usually involves occlusal 'adjustment' by grinding selected parts of the occlusal surfaces. When this only involves one or two clinically obvious interferences, it can be done directly in the mouth. However, if the adjustment needs to be more extensive it is best carried out first on articulated study casts set up in a semi-adjustable articulator, a mock adjustment, to see the effects of the adjustment before irreversible changes are made to the teeth.

This is not the same as occlusal 'equilibration', which is the recontouring of the entire occlusion to fit some preconceived, idealized concept of what the occlusion should be. Similarly the treatment of mandibular dysfunction only very seldom justifies the construction of multiple crowns or bridges. Crowns and bridges may be necessary for other reasons, and if the patient has mandibular dysfunction then this will complicate the treatment and definitive restorations should not be provided until the symptoms have resolved.

Further detailed management of mandibular dysfunction is beyond the scope of this book, and the remainder of this chapter deals with practical aspects of dealing with the occlusion in a patient without symptoms of mandibular dysfunction.

## Examination and analysis of the occlusion

In most cases it is sufficient to examine the occlusion clinically, but in more extensive occlusal

reconstructions or where there are conditioned patterns of movement preventing clinical examination, study casts should be articulated. Provided that the clinician understands what he is looking for, there is no need to articulate study casts for the majority of individual crowns and small bridges at this stage.

## Clinical examination of the occlusion

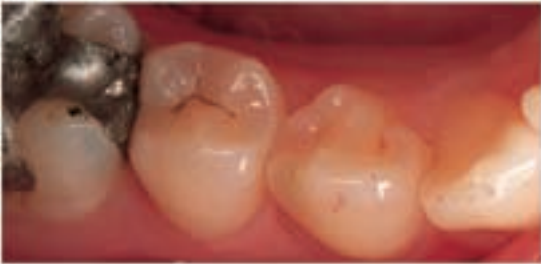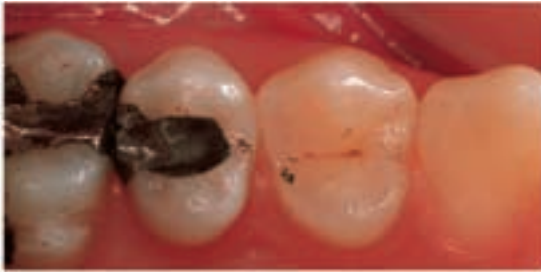
The following points should be noted:

- Any complaints the patient may have of temporomandibular joint pain, muscle spasm or unexplained chronic dental pain
- The ease or difficulty with which the various excursions can be made voluntarily by the patient
- Any occlusal interferences and whether the proposed restorations will influence these
- Mobility of teeth during excursions of the mandible with the teeth in contact
- The presence, angle and smoothness of any slide from RCP to ICP
- The type of lateral guidance and particularly the degree of contact in lateral excursion of any teeth that are to be restored, or the likely degree of contact for any teeth to be replaced
- The presence of any contact on the non-working side
- The location, extent and cause of any faceting of the teeth to be restored or signs of excessive wear to restorations or teeth
- The degree of stability of the occlusion and whether the proposed restorations will influence stability
- Over-erupted and tilted teeth, particularly if they are the teeth to be restored or if they oppose the teeth to be restored.

## Clinical aids


### Articulating paper or foil

Flexible articulating paper or plastic foil of different colours may be used to mark occlusal contacts in different excursions. For example,



**Figure 4.7**

*a* and *b* Occlusal contacts marked in two different colours of foil. The black marks on the marginal ridges of the upper premolars, *a*, and on the buccal cusp of the lower first premolar, *b*, were made with the patient in ICP. Movement to RCP produced the contacts marked in red.



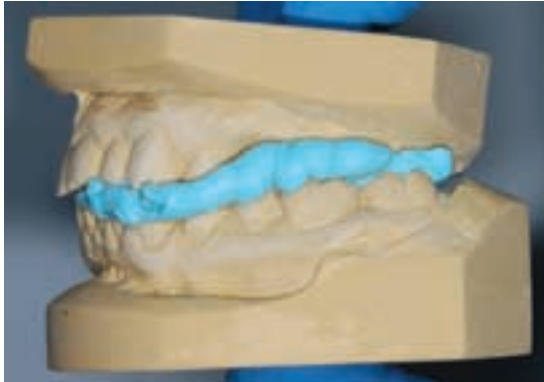
**Figure 4.8**

A selection of articulating papers used to mark occlusal contacts. The red paper is held in Millers forceps. Shimstock in the lower left corner is used to verify that contacts are present as it will be held where contacts exist.

the ICP may be recorded in one colour and the RCP in a second colour (Figure 4.7). Articulating paper is rather difficult to use, having a tendency to mark the tips of cusps whether or not they are in occlusion, and often it does not register contacts on polished gold and glazed porcelain. The thickness of the paper will have an influence on the degree of marking that occurs and ideally it should be as thin as possible. Figure 4.8 shows a selection of marking materials. The teeth are very sensitive to the thickness of material between them and can easily detect the differences between the materials shown in Figure 4.8.

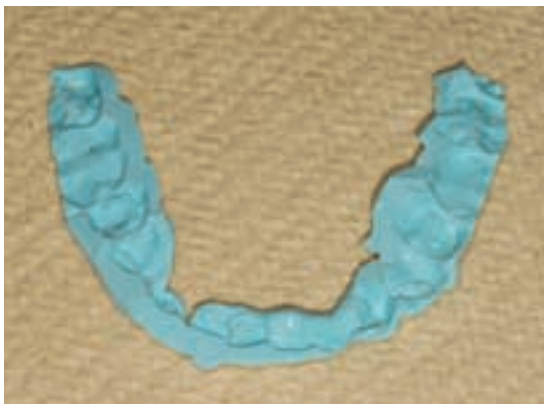
### **Wax**

Thin, fairly soft wax with an adhesive on one side is marketed as a material for registering occlusal contacts. This is useful but rather expensive. A better alternative is to use 0.5 mm thick, dark-coloured sheet wax. Occlusal registrations in this material are shown in Figure 4.3. It has the advantage that it can be removed from the teeth and placed over the study casts for the occlusal contacts to be studied more closely. It can also be used in full arch-sized pieces. Areas of contact in the mouth may be marked through the perforations with a chinagraph pencil.

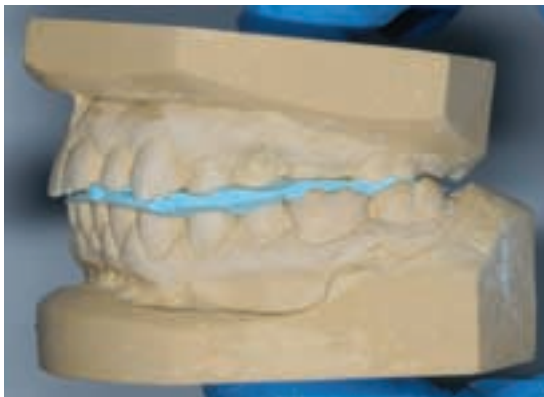


**Figure 4.9**

*a* Plaster casts with a silicone occlusal record used to relate the casts together. The excess of material obscures the relationship between the casts.



*b* The occlusal record is trimmed so that just the material on the occlusal surface remains.



*c* The casts can now be brought together and the correct relation seen and verified.

### Occlusal registration silicones

Fast setting silicone rubber materials can be syringed between teeth and the occlusal contacts recorded. These materials are soft initially so offer

no resistance to the closure of the mandible, which can be a problem with more viscous materials such as wax if not softened properly. The resistance felt on biting into a more viscous material may guide the mandible into a different position.

Once set the silicone material is flexible but sufficiently rigid to be used as an accurate interocclusal record to articulate casts. It can be placed on the model to show, by means of the perforations, which parts of the occlusal surface are making contact. Because it can be replaced onto the model or the patient's teeth without damage it is a better material than wax (Figure 4.9).

### Plastic strips

Plastic strips may be used to test whether teeth are making contact in various excursions. The thinnest of these materials (shimstock) is opaque and silver-coloured and is only 8 micrometres ( $\mu\text{m}$ ) thick. The strip is placed between opposing teeth and pulled aside once occlusal contact has been made. Often two pieces are used on opposite sides of the jaw to test the symmetry of the occlusion, or between the crowned tooth and its opponent, and the adjacent tooth and its opponent to test that the crown is in contact but is not 'high'.

Less accurate (40  $\mu\text{m}$  thick) but more manageable mylar matrix strips, used for composite restorations, are sometimes an acceptable alternative.

### Study casts

Unarticulated study casts are useful for assessing the stability of the occlusion in ICP and for examining wear facets, which are often easier to see on the cast than in the mouth. They are of little value in assessing contacts in the excursions of the mandible. It is important that the casts are a good quality with no air bubbles or blips on the occlusal surfaces of the teeth and that they are trimmed distally to allow the teeth to come into contact. If carefully used, alginate impressions may be adequate but alternatively the casts should be produced from conventional silicone or polyether impression materials used for impressions of the crown preparations.

### Articulated study casts

When sufficient information cannot be obtained by clinical examination or examination of hand-

held study casts, it is unlikely that study casts mounted on a simple hinge articulator will give adequate additional information; a semi-adjustable or fully adjustable articulator is necessary.

Figure 4.10 shows a set of study casts being mounted on a semi-adjustable articulator. For registration of the occlusion the following are required:

- A facebow record which records the relationship of the maxillary teeth to the terminal hinge axis (THA) in three dimensions.
- A record of the RCP in one of the materials described more fully in Chapter 6.
- Sometimes an RCP record is not needed and an ICP record is sufficient, or the interdigitation of the casts is clear and stable and no interocclusal record is needed.
- Protrusive excursion record.
- Lateral excursion records.

The semi-adjustable articulator has a number of limitations and produces only an approximation to the tooth movements in the mouth. However, for most purposes it is quite sufficient.

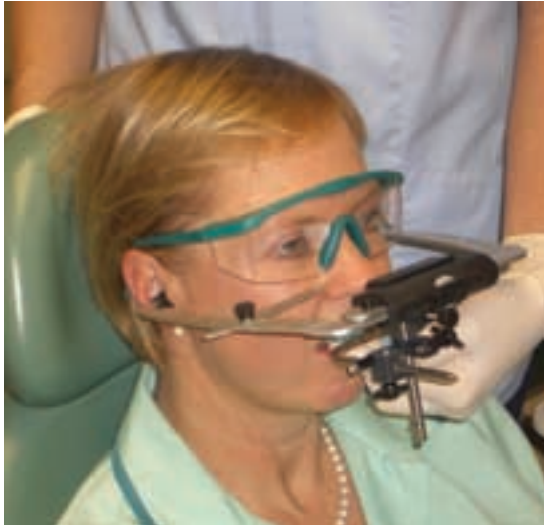### Occlusal adjustments prior to tooth preparation

Once the occlusion has been assessed, adjustment prior to tooth preparation must be considered. This may be necessary in cases where the teeth opposing a proposed bridge have over-erupted or where the occlusal plane is going to be altered by means of crowns. If the tooth to be prepared has an occlusal interference it should be adjusted prior to starting the preparation to ensure that there is sufficient enamel and dentine remaining for the final preparation to be completed without endangering the pulp. Adequate tooth preparation for the proper thickness of occlusal crown material is necessary, otherwise there is a risk that the interference will be reproduced. Sometimes the incisal plane of the lower incisors is adjusted and levelled out before making upper incisor crowns.

Occlusal adjustment is also indicated in many cases of mandibular dysfunction (see earlier).

There is no justification for prophylactic adjustments unless there is evidence of damage or

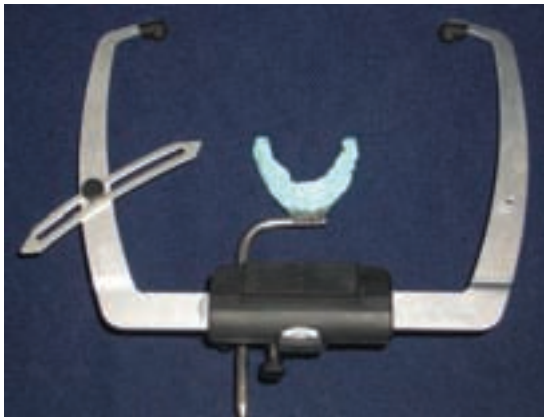



**Figure 4.10**

Articulating casts on a semi-adjustable 'arcon' articulator, in this case a Denar articulator.

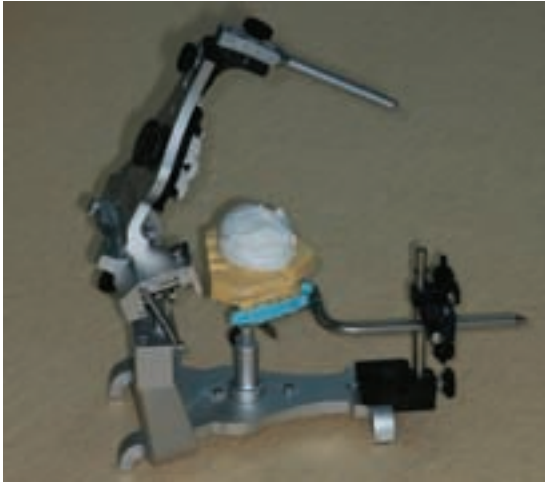*a* A facebow being used to relate the maxillary teeth to an approximation of the terminal hinge axis (THA). The anterior part of the facebow carries a bitefork with an impression seated on the upper teeth. The posterior part has earpieces which fit into the ears. An assumption is made that the THA is an average distance in front of the external auditory meatus.



*b* The facebow record removed from the mouth. The pointer to the side of the nose orientates the facebow to the FM plane.



*c* The upper cast is placed into the bitefork record and the jig placed and supported in the articulator. The undersurface of the cast has been indexed with notches so that it can be removed later and repositioned in the same place.



*d* and *e* Quick-set, low expansion plaster is placed on the upper cast and the upper arm of the articulator is brought down so that when set, the upper cast is secured in place in the correct relationship to the axis points.



*f* and *g* The articulator is inverted and the lower cast is secured to the upper using the interocclusal, ICP or RCP silicone record and sticky wax. The lower cast is then secured to the articulator with plaster and the articulator closed.



*h* and *i* The completed casts in the articulator. They can be removed as required and replaced back in the correct relationship due to the indexing between the casts and the white plaster mounts.

*h* The casts in RCP. The condylar guidance is now adjusted using protrusive or lateral excursion interocclusal records. The record is placed between the teeth and the condylar guidance angle is adjusted until the casts are fully seated in the record.



*i* The articulator open.

pathology arising from the occlusion; our level of understanding of occlusal problems is not yet sufficient to warrant arbitrary prophylactic alterations in an established, comfortable, functioning occlusion.

## Occlusal objectives in making crowns and bridges

There are two main objectives:

- To leave the occlusion with no additional occlusal interferences, i.e. harmonious
- To leave the occlusion stable.

In addition, there may be secondary objectives, for example:

- To distribute the guidance in one of the excursions more evenly between a number of teeth, for example, by modifying the anterior guidance so that a number of anterior teeth share the occlusal forces in protrusive excursion.
- When a canine tooth that previously guided the occlusion is extracted, lateral forces should be distributed as evenly and as widely as possible between the remaining posterior teeth.

These latter objectives may be described as occlusal engineering, planned to produce occlusal relationships that achieve the first two major objectives of occlusal harmony and stability.

Most crowns and small bridges are made in mouths with an established RCP and ICP. These should be left unaltered by the restorations (i.e. a 'conformative' approach) unless:

- So many of the occluding surfaces are being restored that ICP will inevitably be altered
- ICP is unsatisfactory for some reason
- OVD is being altered, or
- There are symptoms of TMD.

In all these cases the occlusion is usually restored with the ICP made to coincide with the RCP (i.e. a 'reorganized' approach). This is mostly for practical reasons and does not imply that RCP is preferable to an established, comfortable, functional ICP. The reorganized occlusion is established either at a vertical dimension which

the dentist considers is close to the original OVD or, more commonly, at an increased OVD to replace the lost OVD and to allow sufficient interocclusal space for the restorations to be made.

With all major reconstructions, well made provisional restorations should be worn for sufficient time to establish that the new OVD and occlusal functional relationships are comfortable. This is usually between 3 and 6 months.

## Clinical and laboratory management of the occlusion

### Avoiding loss of occlusal relationships

When sufficient occluding teeth will remain to register the ICP and other occlusal relationships after tooth preparation, there is no need to take any precautions to record the occlusal relationships beforehand. However, when the occlusal surfaces are being removed from a number of teeth, or when one or more of these teeth are crucial to the guidance of mandibular movements, the occlusal relationships should be registered before the tooth preparations are begun.

When large numbers of posterior teeth are being prepared or when several teeth are missing there is a risk of losing any record of the original OVD. A pair of opposing teeth on either side may be left unprepared, the remaining teeth prepared and then the opposing teeth adjusted so that the ICP is the same as the RCP. Impressions and occlusal records are taken with these teeth stabilizing the jaws during the occlusal registration. They are then prepared and further impressions are taken. Alternatively, one pair of opposing crowns can be made for each side of the arch before the other teeth are prepared and these pairs of crowns serve the same purpose.

### Maintaining occlusal relationships with temporary restorations

Prepared teeth and their opponents will over-erupt unless occlusion is re-established by means of adequate temporary restorations; and the prepared tooth and the teeth either side of it can drift together unless contact points are

maintained in this way. The longer the period between the impression and fitting of the restorations, the more important are temporary restorations. They are probably also more important in younger patients, where tooth movement may occur more quickly. For this reason, individually made temporary restorations in plastic are preferred to preformed types unless the preformed temporary restoration happens to be an excellent fit at the contact points and in the occlusion.

### **Recording the occlusion**

A decision must be made on the type of articulator to use for the working casts. Once this is done, the appropriate occlusal records will be obvious. The choice is between the following four options:

#### **Hand-held models**

These are not usually satisfactory. The most common problem is that posterior restorations are made high and are not detected because it is very difficult to see the tiny spaces between pairs of opposing teeth adjacent to the restoration.

It is unfortunately common that the carefully contoured occlusal surface of a posterior crown has to be adjusted at the chair side because the crown is 'high'. The most common reason for this is the use of hand-held working casts. This adjustment is time-consuming, frustrating and damaging to the patient's confidence in the dentist. It is much better to give clear instructions to the laboratory to use an appropriate articulator. This will be more time-consuming in the laboratory (which may therefore charge more) but will often save clinical time and patient respect (both more valuable than the laboratory time).

#### **Simple-hinge articulator** (Figure 4.11)

This is adequate when there are sufficient unprepared intercuspal teeth and the restoration is to be made occluding in ICP. For example, in a straightforward single upper anterior crown, the palatal surface can be contoured to match the adjacent palatal surfaces so that the incisal

guidance will need very little adjustment. Similarly, for a single posterior crown when the occlusion is canine-guided, it is necessary only to reproduce contact in ICP. The crown will disclude in lateral and protrusive excursions.

The major advantage of a hinge articulator over hand-held models is that if the restoration is made high on the working cast this can be identified and adjusted prior to trying the restoration in the patient's mouth.

Sometimes there is no need for any occlusal record. It is often possible to place the models together entirely satisfactorily in ICP. When there may be some doubt about ICP an occlusal record is made in wax or one of the other materials described earlier and in Chapter 6.

#### **Semi-adjustable articulator** (see Figures 4.10 and 4.12)

These have the following features:

- The condyles are on the lower member of the articulator and the condylar guidance element on the upper membrane, i.e. an arcon design (see later)
- The intercondylar distance is variable
- The maxillary cast is related to an approximation of the THA through the condyles
- Condylar guidance is variable, but only in straight lines
- Some adjustment of incisal guidance is usually possible.

When occlusal relationships are important in positions other than ICP a semi-adjustable articulator should be used. The maxillary cast is mounted using the facebow, and the mandibular cast is related to it by hand in ICP, by an ICP record or by a record in the RCP, whichever is appropriate. The articulator is then adjusted using intra-occlusal records taken in either protrusive or lateral excursions. The records taken will be selected according to the circumstances. For example, if crowns on the right side are being made in a case with group function but where there is no risk of non-working side contacts occurring in left lateral excursion, only a record of right lateral excursion is necessary.

With this arrangement a good approximation to group function should be possible, with only

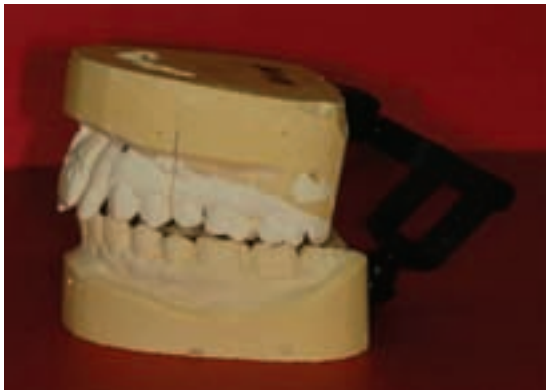

**Figure 4.11**

*a* An example of a simple but rigid articulator that is satisfactory for most single crowns and small bridges.



*b* An inadequate articulator which is not sufficiently rigid and does not maintain the occlusal relationships properly so that:

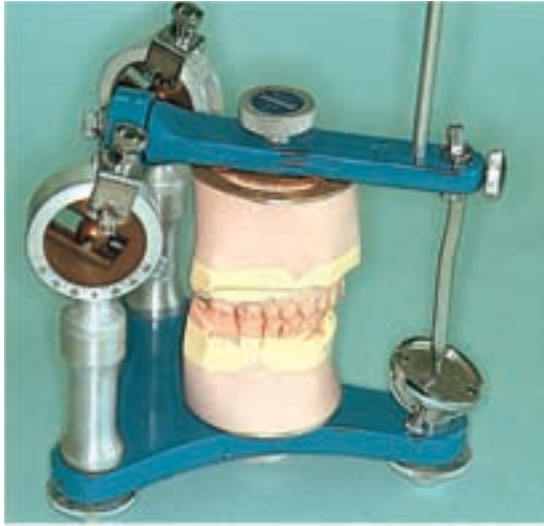


*c* without detaching the articulator the relationship of the casts can be distorted. This much distortion would be obvious but minor amounts would not.

minor adjustment being necessary at the chair side because of the compromises inherent with semi-adjustable articulators.

There are two broad categories of semi-adjustable articulator – arcon and non-arcon. The articulator shown in Figure 4.10 is a semi-

adjustable arcon articulator, and the fully adjustable articulator shown in Figure 4.13 is also an arcon design. The type shown in Figure 4.12 is a non-arcon type. That is, the balls representing the condyles are attached to the upper member of the articulator and the condylar guidance to the



**Figure 4.12**

A 'non-arcon' type of semi-adjustable articulator. This is still sometimes used for dentures but seldom for crowns or bridges.

lower. This is, of course, upside down with respect to the anatomy of the joint. The articulator shown in Figure 4.11 is also non-arcon.

In practical terms the difference between the arcon and non-arcon designs is not particularly relevant, provided that the occlusal records can be taken with the teeth in contact or nearly so. However, if the OVD is being increased or if the occlusal records have to be taken at a degree of opening of the mandible then this affects the relationship between the condylar guidance angle and the upper member of the articulator. It follows that in these circumstances an arcon design should be used.

### Fully adjustable articulator

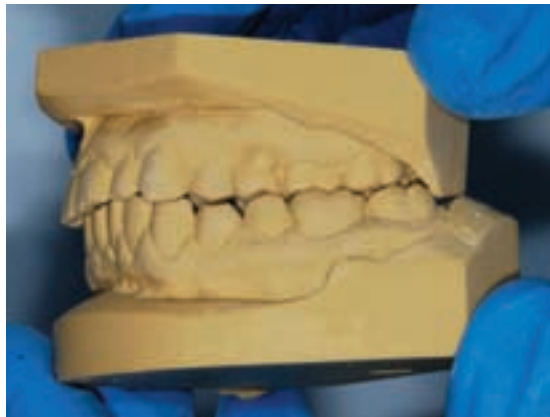A full description of the use of these articulators and the additional records needed to use them is beyond the scope of this book. Suffice it to say that they are sometimes, but decreasingly, used when more accurate and comprehensive records of mandibular movements are required. Their use has been largely superseded by making long-term provisional restorations and adjusting these in the mouth over a period time. When satisfactory the principles, but not necessarily the exact contours, of the occlusal design are reproduced in the final restoration. This can be achieved with a semi-



**Figure 4.13**

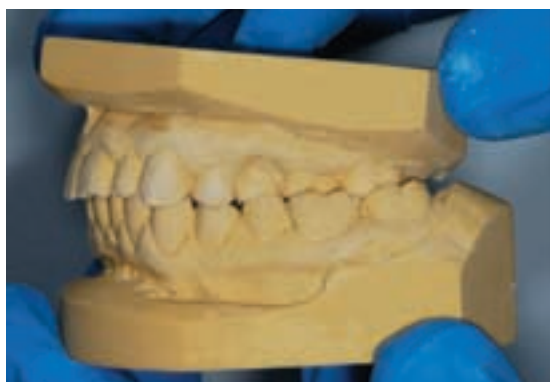A fully adjustable articulator, now of mainly historical interest; see text.

adjustable articulator. In other words the patient's mouth is used to refine the occlusion rather than using an over-complicated, and still not entirely accurate, artificial reproduction of the patient's mandibular movements.



**Figure 4.14**

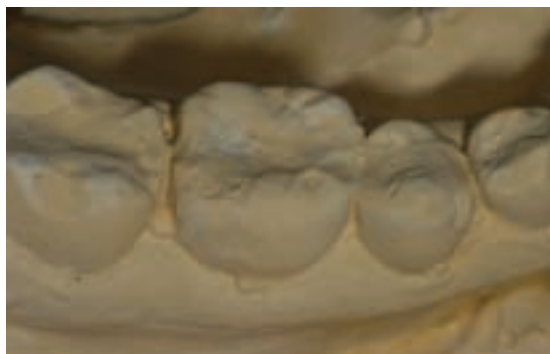*a* Poorly trimmed casts cannot be properly related as the heels at the back of the casts get in the way.



*b* Once trimmed properly the casts will come together.



*c* Plaster 'blips' are common if small air bubbles are present in the impression. This happens more with alginate impressions.



*d* These need to be carefully trimmed.



## Laboratory stages

### Trimming the casts

One of the commonest causes of restorations being high when tried in the mouth is distortion of the casts, particularly the opposing casts, which may be made from an alginate impression. Commonly, small air bubbles trapped in the occlusal fissures will prop the models apart slightly, so that if the restoration is made to touch the opposing model, it will be high in the mouth. Impression techniques for crowns and bridges should concentrate on the crowns of the teeth, injecting impression material into the occlusal fissures or rubbing alginate into them with the fingers. If air bubbles do occur, great care should be taken to trim occlusal defects from the models, and if individual teeth are suspect, they should be cut right away from the model unless they are opposing or adjacent to the teeth being restored (Figure 4.14).

### Articulating the casts

As small an amount of plaster as possible should be used since the expansion of the plaster distorts the relationship of the articulator with the casts. Impression plaster or plaster containing an anti-expansion agent should be used; alternatively, there are plasterless designs of articulator.

### Shaping the occlusal surfaces

The technique of shaping the occlusal surface will depend upon whether the surface is to be metal or porcelain.

**Wax carving** With this technique wax is built up to excess on the occlusal surface and then carved to the required occlusal contour. Small increments of wax are added when necessary to repair over-carving. When completed, occlusal contact should be checked using shimstock, both between the carved tooth and its opponent and between adjacent teeth and their opponents (Figure 4.15).

**The wax-added technique** Small increments of molten wax are flowed from the tip of an instru-

ment to build up cones, each one forming the tip of a cusp. The other features of the occlusal surface are then added, often with different coloured waxes to identify each feature. Using this technique, the occlusal relationships in all excursions can be checked from the beginning and adjusted as the process continues (Figure 4.15).

**Occlusal shaping with porcelain** Porcelain surfaces are built up slightly to excess and then ground to shape, stained and glazed. Again shimstock or similar material is used to check the occlusal relationships in the articulator.

## Adjusting the occlusion of restorations in the mouth before cementation

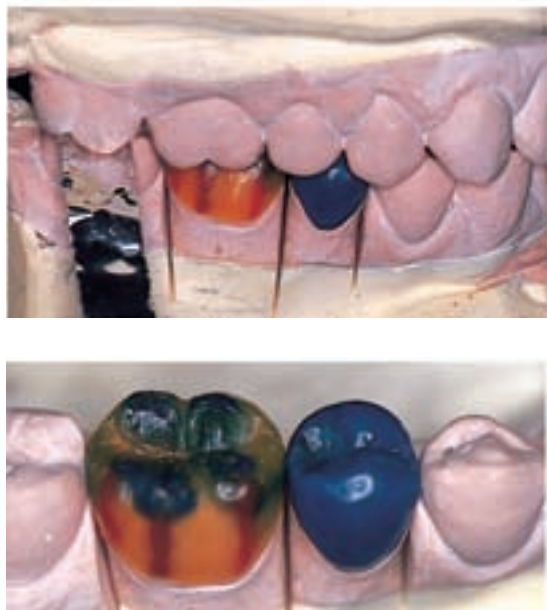### Occlusal marking materials

Articulating paper and foil and 0.5 mm thick darkly coloured wax have already been described. An alternative technique for metal occlusal surfaces is to grit-blast them lightly with a mild abrasive which gives the surface a matt appearance. Burnish marks will then appear in areas of contact with the opposing teeth and the articulating papers will mark more clearly. For porcelain occlusal surfaces, especially with complex occlusions or multiple crowns, it is often best to adjust the occlusion when the porcelain is in a biscuit bake stage prior to the final glaze.

### Adjusting in intercuspal position

A patient who does not have a local anaesthetic will be immediately conscious of a high restoration in ICP. Even with a local anaesthetic the opposing teeth will normally sense a high restoration. The patient will not of course be aware of a restoration that is short of the occlusion, and so occlusal contact should be checked with shimstock or mylar matrix strip. If occlusal contact is not present (i.e. the restoration is not occlusally stable), the tooth or its opponent will over-erupt and occlusal interferences may be introduced.

High restorations should usually be adjusted. However, occasionally a high posterior crown (or



**Figure 4.15**

*a* and *b* Two crowns waxed up on the lower second premolar and first molar teeth on working casts articulated in a simple but robust articulator. The lower second premolar has been waxed using a carving technique, starting with an excess of wax on the occlusal surface. The first molar has been carved by a 'wax-added' technique, cones of wax being built up to the required contact with the opposing teeth and the gaps between filled in with a different-coloured wax. Shimstock is being used to check that contact just occurs between the unprepared second molar teeth, and will be used between the wax patterns and the opposing teeth and the unprepared second premolars.

small bridge) may be planned in advance in order to produce tooth movements similar to tooth movements produced by a Dahl appliance in the anterior part of the mouth. This may be done, for example, when the tooth to be crowned is very short and little or no preparation of the occlusal surface is desirable. This tooth movement (as with a Dahl appliance) is preferably achieved with provisional restorations and the patient warned in advance. Patients readily accept this as part of planned treatment but, as stated earlier, resent it when it is unplanned and appears to be a mistake.

#### **Adjustments in lateral, protrusive and retrusive excursions**

The occlusion of the restoration is examined for interferences in these excursions of the mandible and adjusted if necessary. A simple guide to the presence of possible interferences is whether the crown is displaced during lateral and protrusive mandibular movement with the teeth in contact.

#### **Stability**

Following these adjustments, a final check of the stability of the occlusion is made by confirmation of the presence of centric stops on the restoration and the adjacent teeth. The adequacy of the contact points is checked with dental floss.

#### **Adjustment techniques**

ICP is adjusted first and the centric stops marked with articulating foil, paper or wax. Interferences are marked with a different colour and adjusted.

Metal and porcelain can be adjusted with mounted stones or diamond burs. Metal can be finished with finishing burs and polished with mounted rubber wheels or points. Porcelain can be finished with the mounted points or discs used to finish composite and with specially produced sets of instruments. With these instruments, the finished surface is as smooth as the glazed surface, and re-glazing is unnecessary (see Figure 14.11).

**WWW.HIGHDENT.IR**

همیار دندانسازان و دندانپزشکان

## 5

# Planning and making crowns

There is a natural sequence by which the history and examination of the patient leads to a decision on the advisability or otherwise of crowns in the context of the overall treatment. This general decision leads to a further series of stages in the detailed planning of treatment. This sequence is:

### History and examination:

- Of the whole patient
- Of the mouth in general
- Of the individual tooth

### Decisions to be made:

- Keep the tooth or extract
- If the tooth is to be kept – crown or other restoration
- If the tooth is to be crowned – preparatory treatment necessary

### Detailed planning of the crown:

- Appearance
- The remaining structure of the tooth and its environment, including any necessary core
- Choice of type of crown, including material
- Detailed design of the preparation

### Planning and executing the clinical and laboratory stages:

- Appointment sequence – agreement with patient and laboratory, including agreements on fees and laboratory charges
- First clinical stage
- Laboratory stage
- Second clinical stage
- Maintenance.

It would be very nice if life were as simple as this. It is convenient to have such a sequence of events in mind but it is not often possible to follow the pattern precisely. For example, if endodontic treatment is necessary as part of the preparatory treatment then a temporary crown may well have

to be made at an early stage before the preparation can be finally planned. This outline sequence may have various repeat loops arising within it. The dentist must be prepared to rethink the options as new circumstances arise and allow full freedom to his or her professional judgement.

## History and examination

### *Considering the whole patient*

#### Patient attitude and informed consent

Complex and time-consuming procedures such as crowns should not be contemplated unless the patient is enthusiastic and cooperative about the treatment. There is always some other way of treating the tooth, even if it means extracting it. The patient's attitude is particularly important when crowns are being considered for purely cosmetic reasons. The dentist must be satisfied that the patient fully understands the limitations of what can be achieved. Techniques for demonstrating cosmetic changes to patients before the teeth are prepared are described later.

If these explanations and demonstrations are not given adequately then the patient cannot give properly *informed* consent – a very important legal concept.

Patients generally appreciate having the reasons for treatment explained to them together with some of the details of treatment. A common source of dento-legal problems is the patient who claims an inadequate understanding of what was being proposed and that had it been fully understood, he or she would not have gone ahead with the treatment. Again this applies particularly to treatment provided mainly for cosmetic reasons.

Prior to starting any extensive treatment it is prudent to confirm to the patient in writing

exactly what treatment is proposed, what compromises may be necessary, what the alternatives are and what the costs will be. Copies of this correspondence should be kept. This will help to reduce future problems if the patient is unhappy with the result and is time well spent.

### Age

There is no upper age limit for crowns provided that the patient is fit enough to undergo the treatment and is in other ways suitable for crowns. There are some practical problems in extensive treatment for elderly patients; for example, the teeth tend to become more brittle with age and this affects the design of crown preparations. Also some older patients develop physical problems such as rheumatoid arthritis in their hands or medical problems requiring treatment with drugs which reduce salivary flow and predispose them to caries at the crown margins even if this has not been a problem when they were younger. Both these examples, and others, affect the patient's ability to maintain the standard of oral hygiene which is necessary if crowns are to succeed for a useful period of time.

Neither is there a lower age limit for crowns. It is unusual to make crowns for teeth shortly after they have erupted, and crowns are commonly delayed until the patient is 16 or so. However, this decision has traditionally been based upon three main factors:

- The size of the pulp
- The degree of eruption of the tooth
- The cooperativeness of the patients.

These will vary considerably among patients. For example, an upper incisor tooth that is fractured at the age of 7 or 8 and restored with composite, will usually develop extensive secondary dentine so that the pulp will be smaller by the age of 10 than the pulp of an undamaged tooth at the age of 16. In patients with good oral hygiene, the position of the gingival margin of the incisor does not alter much after this age, and today's children are far less anxious about dental treatment than they were a generation ago. In a case like this, therefore, there may be no contraindication to providing a permanent crown at the age of 10.

Similarly, when a successful root canal treatment has been carried out so that there is no need to worry about the pulp, post-crowns can be made for children in their early teens and even younger.

Even when the pulp has not been damaged or affected by secondary dentine, there is now evidence that the size of the pulp does not vary significantly with age in the great majority of young patients. The ratio of the size of the pulp to the size of the tooth is very varied, and certainly the pulp does not suddenly shrivel to a significantly smaller size on the patient's 16th birthday or at any other age. It is much more important to assess pulp size from a good, clear periapical radiograph than it is to adopt an arbitrary rule about the age at which teeth can be prepared for crowns.

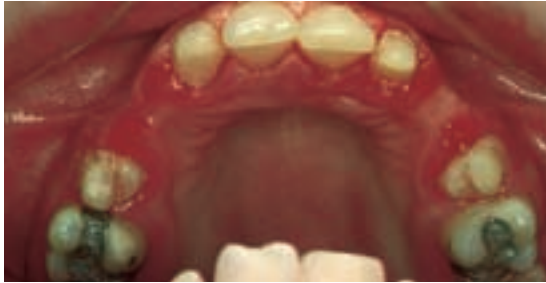Of course, there are far fewer indications for anterior crowns in young patients than there were a few years ago, with the introduction of a variety of new ways to restore anterior teeth and make bridges, as described elsewhere in this book.

Figure 5.1 shows bridges being made for a 13-year-old boy and a set of full mouth crowns for a girl of 12 with severe dentinogenesis imperfecta. Both patients were particularly cooperative and enthusiastic about treatment. Figure 5.1c shows the crowns for the second patient still in place at age 30.

It is argued that boisterous children and sports players who suffer damage to their teeth should not have the teeth permanently restored until they are over this energetic period. However, many of them continue to play vigorous contact sports well into their twenties or thirties or later and, if crowns are indicated, it is quite unacceptable that patients should be deprived of them until they have become docile and sedentary. It is very much better to provide the crowns, and with them a mouth protector, not only for the crowns but also, more importantly, for the remaining natural teeth.

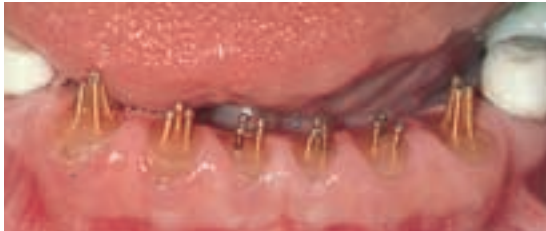### Sex

Many male patients are just as concerned with their appearance as females. They may, however, be less willing to admit to this. It is more important to determine patients' real attitudes to their appearance than to make assumptions based upon their gender.

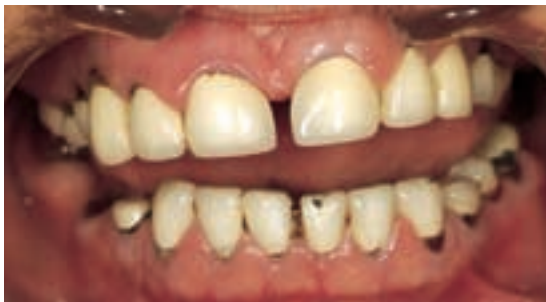**Figure 5.1**

Crowns and bridges for young patients.

*a* Bridge preparations for a patient aged 13 with oligodontia (a combination of hypodontia – congenitally missing teeth – and microdontia – small, malformed teeth). The teeth prepared are the canines and second premolars: the diminutive and unattractive canines are in the position of the missing lateral incisors. At this stage, minimal preparations are carried out and metal-acrylic provisional restorations placed for a period of 6 months to a year. This encourages secondary dentine formation so that the definitive preparations can be made with less risk to the pulp (see the text for an explanation of the poor gingival condition).



*b* Threaded-pin retention for composite cores in a patient aged 12 with dentinogenesis imperfecta. In this condition the pulps recede rapidly, and this procedure was carried out without the need for local analgesia.



*c* These are the crowns made for the patient in *b* 18 years after they were fitted. The porcelain at the incisal edge of the lower left central incisor has chipped and there has been some gingival recession and repairs with glass ionomer cement, otherwise the pin-retained composite cores have been successful and none of the crowns has been lost. The teeth were eventually extracted 26 years after these crowns were fitted and replaced by implant-retained restorations.

### Social history

When extensive treatment is planned, it is important to establish that the patient will be available for appointments of sufficient length and frequency to complete the treatment. Crowns should not be started just before a patient is due to sit important examinations, or just before travelling abroad. People who plan to marry usually like to have their crowns completed in time for the wedding photographs.

The patient's occupation may be important. Wind instrument players, for example, are particularly anxious to retain their incisor teeth in

order to support their embouchure (the particular contraction of the lips needed to form the contact with the mouthpiece).

Habits such as pipe smoking, where the stem of the pipe is clenched between the teeth, may affect the design or type of crown selected.

### Cost

There is no satisfactory way of mass producing crowns, and so they will always be labour-intensive and therefore costly. Whichever way the cost is borne – by the patient, or by a private or

public insurance scheme – the cost is important and must be taken into account in any treatment plan. Because crowns are expensive, they should not be made unless they will really contribute significantly to the patient's well-being and can be expected to last for a reasonable period of time.

## Considering the whole mouth

### Oral hygiene

There is obviously no point in embarking upon a complex course of treatment involving crowns (or bridges) in a mouth with rapidly progressing caries or periodontal disease resulting from poor oral hygiene. The first priority must be to arrest the disease process and improve the oral hygiene.

That being said, however, it is impossible for any mouth to be kept absolutely plaque-free. It is almost always possible to find some in the mouth of even the most meticulous patient. Most, despite good intentions, achieve only a moderately good level of plaque control. The problem for the dentist is therefore one of degree. He or she must decide whether the patient, after instruction in oral hygiene, can achieve a level of oral cleanliness that warrants treatment which is time-consuming and costly. It is also necessary to decide how to treat those patients who are assessed as having a level of oral hygiene falling below this standard but who nevertheless have teeth that can only be treated satisfactorily by means of crowns.

There is no simple guidance on these difficult decisions. Perhaps the best advice is to assess not only the level of oral hygiene, but the effect that this is having on periodontal disease and caries. Yet there is no single direct relationship between oral hygiene and disease – many other factors influence the disease processes. The decision whether to crown a tooth or not should therefore be made on an assessment of the prognosis of the tooth without the crown or with it. If, in an otherwise-intact arch, a single badly broken-down anterior tooth is ugly, does not function well and is difficult to restore by any means other than a crown then, provided that the prognosis of the alveolar support is such that the tooth is not likely to be lost for at least a few years, it is almost certainly better to make a crown than to extract it and provide a partial denture, even if

the oral hygiene is poor and cannot be improved. It would be quite wrong not to offer any form of treatment, and morally dubious to attempt to blackmail the patient to maintain a better standard of oral hygiene by refusing the crown unless the oral hygiene improves. In any case, this crude psychological approach seldom produces a permanent improvement in oral hygiene.

Although every effort should be made by both dentist and patient to improve oral hygiene when it is poor, there are those who are simply not able to improve, but who are nevertheless fortunate in having a slow rate of progress of periodontal disease and a low caries incidence, and for these patients crowns are often justified.

Figure 5.1a shows a typical 13-year-old boy who has entered puberty. This hormonal change affects the gingival response to plaque, but it also – as many parents of teenagers know – sometimes leads to expressions of independence and even rebellion. This may show as lapses in cleanliness, including oral hygiene. Fortunately most recover. This patient had several missing or misshapen teeth through no fault of his own. He had cooperated with a course of fixed orthodontic treatment. How cruel now to prescribe a removable denture, which he desperately wished to avoid, at this difficult stage in his life, just because, for the time being, his standard of oral hygiene has lapsed. When crowns or other forms of treatment that improve the patient's appearance are provided, this and the general increase in dental awareness that comes with extended courses of dental treatment themselves often improve the patient's motivation and, in turn, oral hygiene (Figure 5.2).

### Condition of the remaining teeth

The state of health and repair of the whole mouth must be taken into account. When there have been no previous extractions and the prognosis of the remaining teeth is good, it is usually worth the patient and dentist putting a considerable amount of effort into saving an individual tooth. Conversely, when the patient has already lost a number of teeth and is wearing a partial denture that will need replacing fairly soon, it would be foolish to struggle to save an individual tooth unless it is a crucial abutment for the denture, or of particular importance to the patient's appear-



**Figure 5.2**

*a* and *b* The same patient before and after a 6-month course of extensive dental treatment involving periodontal treatment and the construction of upper anterior crowns. During this period, the patient's dental awareness and motivation improved considerably and his oral hygiene became markedly better once he had more attractive teeth.

ance. It is usually better to extract the tooth and remake the denture.

The periodontal condition of the remaining teeth is one of the factors in assessing their prognosis, but it is more important to determine whether any periodontal disease is progressing or whether treatment of it has produced a stable state. The effects of periodontal disease, particularly when there has been gingival recession, can affect the choice and design of the crowns

Assessment of the occlusion is important (Chapter 4). In particular, the adequacy of posterior support should be considered when anterior crowns are planned. Insufficient occluding natural posterior teeth usually means that anterior crowns should be metal–ceramic or one of the stronger ceramic materials.

The replacement of posterior teeth by removable partial dentures may provide medium-term posterior support but will rely on the patient wearing the denture continuously, which may be counterproductive. It is unlikely that a denture will maintain the posterior occlusion in the long term due to the denture teeth becoming worn and resorption of the alveolar bone.

A fixed reconstruction of the posterior teeth, even if limited in distal extension, may be achieved with bridges or implant-supported restorations. It is not necessary for all teeth to be present for the remaining dentition to be considered stable (see the discussion of the shortened arch concept in Chapter 7 (page 182)). A patient who is insistent on anterior crowns for reasons of appearance should be strongly advised



of the risks to anterior crowns without initially providing adequate posterior support.

In some cases where there has also been periodontal disease and drifting of the incisor teeth, crowns joined together may be necessary (splinting is discussed in Chapter 13).

## Considering the individual tooth

### The value of the tooth

Not all teeth are of equal value. Third molars are commonly extracted with no harmful effects on appearance or function. To crown third molars in an intact dentition would probably be no more than a display of clinical virtuosity. However, if a number of other teeth are missing, a broken-down third molar tooth that can be crowned may provide an invaluable abutment tooth for a denture or a bridge. There is a similar range of possibilities for most other teeth.

### Appearance (Figure 5.2)

The presence of failed restorations may suggest that crowns are advisable, but since anterior filling materials are continually improving, the possibility of replacing the restoration rather than crowning the teeth should normally be considered first. Whether the problem is one of failed restorations, intrinsic staining or the shape or angulation of the teeth, a realistic appraisal of the cosmetic advantages of crowns must be made. Sometimes patients expect more of crowns than can be achieved, and are disappointed with the end result. This should be avoided by explaining the problems, complications and compromises associated with crowns (see Chapter 1). A more conservative approach such as veneers should also be considered before a crown is made.

### Condition of the crown of the tooth, the pulp and periodontium

The presence of caries, previous restorations or pulp pathology are not contraindications to making crowns, but they may well determine the type of crown and the design of the preparation.

Caries or fractures extending deep below the gingival margin will make crown preparation difficult, and it may sometimes be better to extract the tooth. Alternatively, periodontal surgery may be used to expose the margin of the fracture.

Unless the tooth has been root-treated, the vitality of the pulp must always be tested and when necessary endodontic treatment carried out. The prognosis and acceptability of crowning a recently root-filled tooth will depend on the absence of signs or symptoms and its radiographic appearance. If there is any anxiety about the success of a root filling then a choice must be made between a number of options:

- Leave the tooth temporarily restored until the symptoms settle and a good prognosis can be given
- Repeat the root filling
- Proceed with the core and a temporary crown, but delay the final crown until the symptoms have settled or the radiographic appearance has improved, or the tooth has been apicected.

In many cases the third option is best. If a tooth is left with a temporary restoration (the first option) for too long, there is a risk that remaining enamel and dentine will break (if there is no risk, why is the tooth being crowned in the first place?). With anterior teeth, if the post and core are inserted immediately, there will be no risk of disturbing the root filling later, and with most well-condensed anterior root fillings, the treatment for further endodontic problems may be an apicectomy. It is better to cement the post and core before the apicectomy rather than afterwards, to avoid the risk of disturbing the apical seal.

A more liberal attitude should be taken to minor radiographic defects in the root filling when it has been present for some years and is symptomless. Further details of the criteria for assessing root canal fillings are left to the endodontic textbooks.

Any local periodontal problems should be assessed and treated.

### Occlusion

The occlusal contacts on the surface of the tooth may be important in determining the type of crown to be used. For example, an upper canine

tooth that is the only tooth in contact in lateral excursion (canine guidance, see Chapter 4) will usually need a metal–ceramic crown rather than a ceramic crown. However, if the tooth is only one of a number that make contact in lateral excursion (group function), it may be possible to restore the canine with a ceramic crown.

The point of contact between the tooth to be crowned and the opposing tooth is also important in determining the position of the crown margin. It is wise to design the preparation so that the opposing tooth contacts either tooth tissue or the crown but not the junction between the two. In the case of partial crowns, when occlusal protection is required, the occluding surfaces of the tooth to be crowned should be determined. These are not always the same as the occlusal surface. Occlusal is an anatomical term, and an extracted tooth still has an occlusal surface. The occluding surfaces are those that really do make contact with opposing teeth in one or other excursion of the mandible.

### Root length

The length of the root should be assessed from radiographs in two ways. First, this should be done from the point of view of periodontal support, i.e. the ratio of the length of the root supported by alveolar bone to the length of the remainder of the tooth. Second, the length of the root is important in providing retention for a post crown. A convention is that the length of the post should be not less than the length of the artificial crown, but there is no good evidence to support this. A better approach is to make the post as long as possible without disturbing the apical seal or risking perforation in a curved or very tapered root.

Variations are possible: for example, a shorter post is acceptable in the case of reduced occlusal forces (such as incisor teeth with an anterior open bite); and a longer post is necessary where there are excessive forces applied to the tooth, for example when the tooth is used as a partial denture abutment. When this length is not available, a post with improved retention, such as a threaded parallel post, should be used. An alternative is to include a full diaphragm of gold over the root face together with a collar around the periphery. This improves retention and also reduces the likelihood of root fracture.

## Decisions to be made

### *Is the tooth to be kept or extracted?*

Usually the result of the history and examination will determine this question. Sometimes, however, it is necessary to proceed to further stages and then return to a decision to extract the tooth if further endodontic, periodontal or other treatment is not successful.

### *If the tooth is to be kept, is it to be restored by a crown or a filling?*

In Chapter 1 the alternatives to crowns are described, and the findings of the history and examination will sometimes settle this question. However, it is often necessary to proceed to a further stage, actually starting the treatment by removing previous restorations and caries, before a properly informed decision can be made (Figure 1.12). For example a tooth with extensive decay may have the decay removed and the need for endodontic treatment determined before it can be decided if a crown is possible. Decay in the mouth is always worse than seen on a radiograph and if extending deeply subgingival or into the furcation area may make the tooth unrestorable even with a crown.

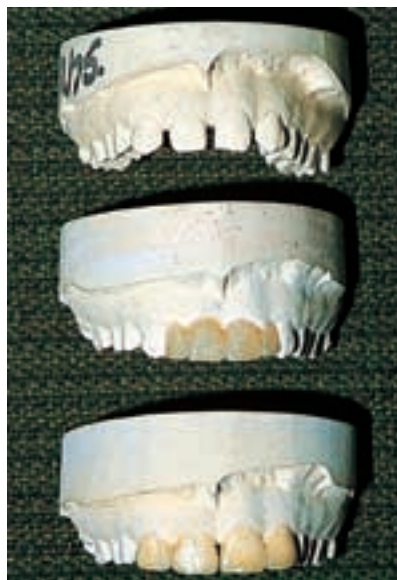### *If the tooth is to be crowned, is any preparatory treatment necessary?*

Preparatory orthodontic treatment may be necessary to move the tooth into a suitable position for crowning. Combinations of orthodontic treatment and crowns can often produce results that cannot be achieved by either form of treatment alone. Periodontal and endodontic treatment may also be necessary.

## Detailed planning of the crown

### *Appearance*

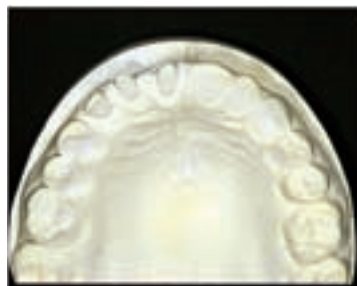When a significant change in appearance is proposed, it is most important that the patient is



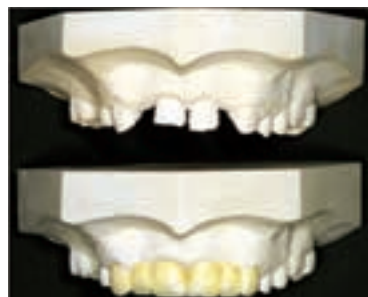**Figure 5.3**

Trial or diagnostic wax-ups.

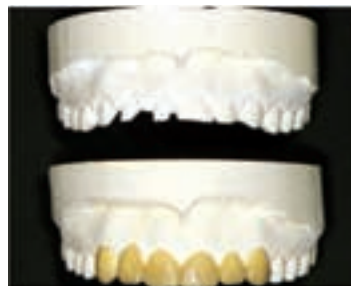*a* Missing upper lateral incisors and a midline diastema. *Centre*: closing the diastema orthodontically and providing bridges to replace the lateral incisors. *Lower*: the alternative is to make four oversized crowns or veneers on the central incisors and canines to resemble four incisors. Neither solution will produce an ideal appearance.



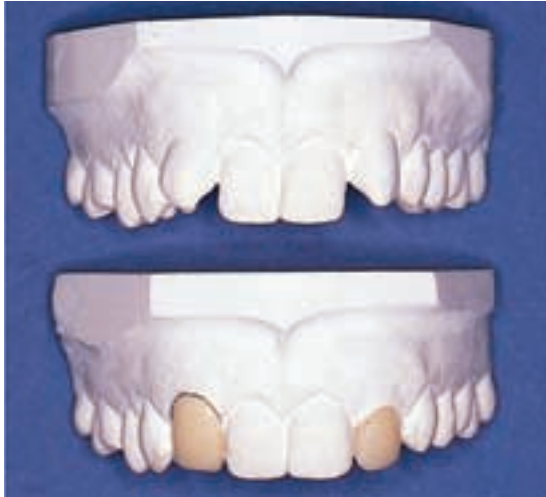*c* This patient has extensive palatal erosion as a result of an eating disorder. The teeth are already short and so diagnostic preparations have been made on three of them to see whether sufficient dentine remains for retentive preparations or whether some other solution is necessary.



*b* A diagnostic wax-up for a similar case. The pointed canines are unattractive and the right central incisor is fractured. The canines have been retracted orthodontically. The lateral incisor teeth will be replaced by two 3-unit conventional bridges (see Part 2) increasing the size of the central incisor crowns and improving the shape and the size of the canines.



*d* The preparations are judged as being sufficiently retentive and this figure also shows how short the unprepared incisor teeth have become. The diagnostic wax-up shows the appearance of the planned restorations and also provides a starting point for more detailed planning of the preparations and for making temporary crowns.

**Figure 5.4**

Diagnostic wax-up 'cheating'. The upper cast shows a patient with ugly prominent canine teeth and missing lateral incisors with no residual space. He was not prepared to have orthodontic treatment to retract the canines. Because of their shape and size it would not be possible to achieve a satisfactory appearance by adjusting them and adding composite. So, leaving them alone or crowns were the only options.

The lower cast shows two trial wax-ups: *left*, with the contour of the gingival margin carefully marked in pencil before the preparation and wax-up are made; *right*, the position of the gingival margin has been lost and a more natural-looking wax-up made. However, it will not be possible to achieve this result in the mouth and a decision whether to proceed with crowns must be made on the appearance of the 'honest' diagnostic wax-up.

fully informed of what can be achieved and what cannot. This can best be done by a modification of the patient's own study casts, usually in wax. Figure 5.3 shows examples of missing upper lateral incisors that could be treated by moving the central incisors mesially closing the diastema and replacing the lateral incisors by means of bridges. If this were done, all the teeth would be rather small. The alternative of not moving the teeth and enlarging the central incisors by means of crowns and crowning the canines to resemble lateral incisors is also shown.

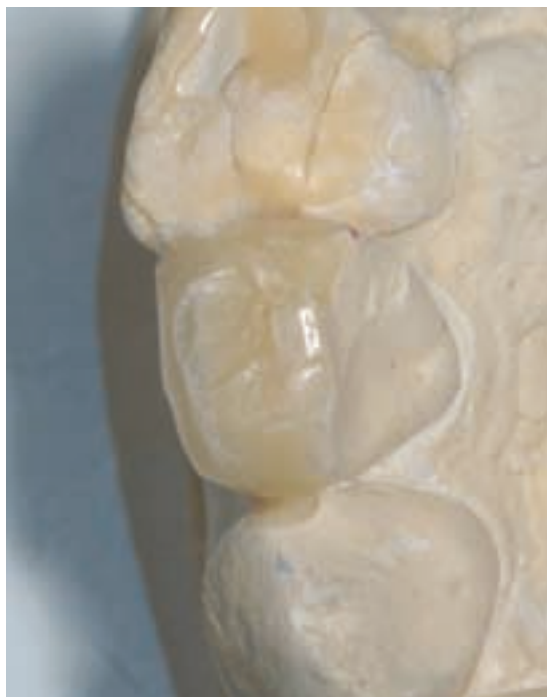Figure 5.3b, c and d shows satisfactory trial wax-ups demonstrating retentive preparations and aesthetically pleasing crowns and bridges.

Trial preparations and diagnostic wax-ups are extremely valuable in predicting the final appearance, and should be used routinely in all but the most straightforward cases, particularly when the student or dentist is inexperienced.

Because the teeth and soft tissues are all reproduced in plaster or artificial stone in the cast, it is possible to 'cheat' by making the diagnostic wax-up in a way that would be impossible in the mouth by reshaping the gingival margin or by changing the dimensions of the root as it emerges

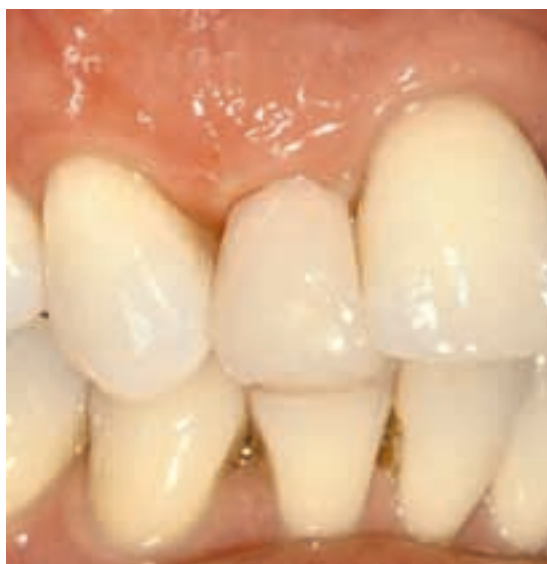from the gum. When the teeth are not to be moved orthodontically, it is useful to draw a pencil line around the gingival margin on the study cast and to ensure that this is still visible after the wax-up has been completed. When the tooth is to be moved orthodontically, the mesio-distal width at the gingival margin should be measured and this width reproduced in the new position of the tooth on the study cast. Figure 5.4 shows an example of study cast 'cheating'. The plan is to crown the upper canines to resemble upper lateral incisors. This is always difficult and often disappointing. One of the distinctive features of an upper canine is the sharply curving gingival margin. This will be retained once the crown is in place, and will detract from the impression that the tooth is a lateral incisor.

These diagnostic wax-ups serve a number of other purposes as well as informing the patient of what can be achieved. However experienced the clinician, each case is different and modified study casts will help in planning details of the eventual appearance. The technician will know what is wanted and will have models to copy rather than have to design the patient's new appearance in porcelain.

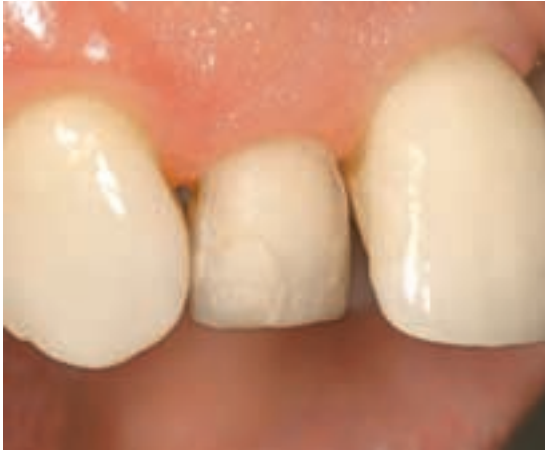

**Figure 5.5**

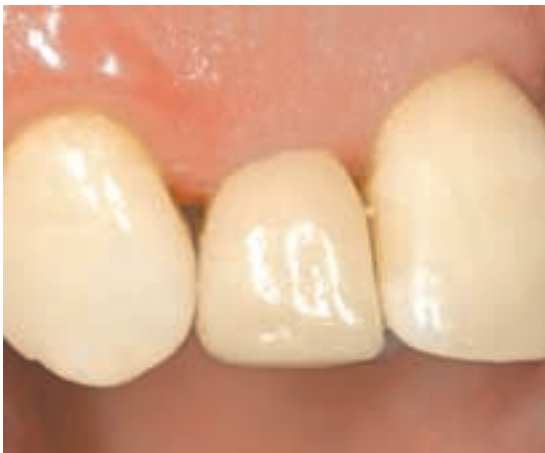*a* On a study cast the possible shape of the tooth can be seen if it is to be built with the labial surface level with the adjacent teeth. This will result in a very thick incisal surface and the patient needs to be fully aware of this complication. Due to the overlap of the adjacent teeth the lateral incisor tooth may appear narrower.



*b* Directly placed composite can be used as a trial for the patient to assess the likely outcome. It might be possible for this to be used as a final restoration but a better result can be achieved by minor adjustment of the adjacent teeth and placing a porcelain veneer.



c Following agreement with the patient, the tooth is prepared minimally.



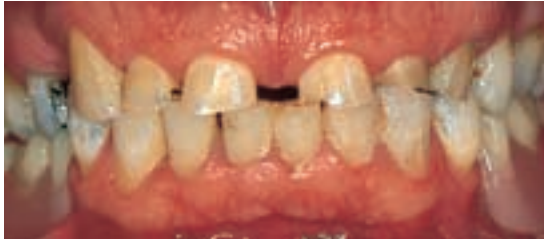d The result with a porcelain veneer.

The person who may have difficulty in interpreting a diagnostic waxing on a study cast is the patient. They are not used to seeing their teeth in this way and the dentist needs to explain the results carefully. It is helpful to show the patient the unmodified model as well as the modified one. Tooth-coloured wax should be used as brightly coloured wax is distracting. Ideally the modified model should be duplicated in the same coloured stone as the original.

The diagnostic wax-up can be used to construct a vacuum-formed matrix that can allow for a trial to be undertaken in temporary crown material in

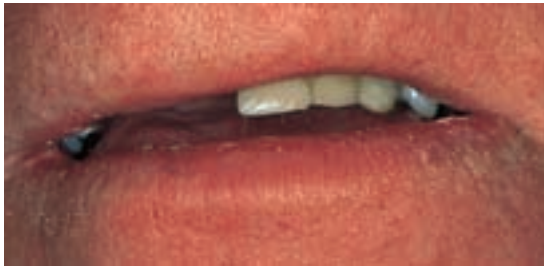the mouth. Alternatively a change to tooth contours can be tried out in directly placed composite so that the patient can see directly in their mouths what the result will be like (Figure 5.5). In patients with high expectations for their appearance great caution should be taken in stating the appearance that can be achieved and the dentist should not be worried about seeking a second opinion on the advisability of treatment.

Techniques are available to alter photographic images of the patient's actual teeth to show the effects of possible treatment. With these techniques it is easy to promise more than can

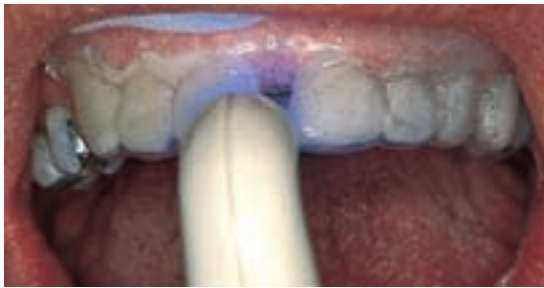
**Figure 5.6**

Temporary and permanent changes to occlusal vertical dimension.

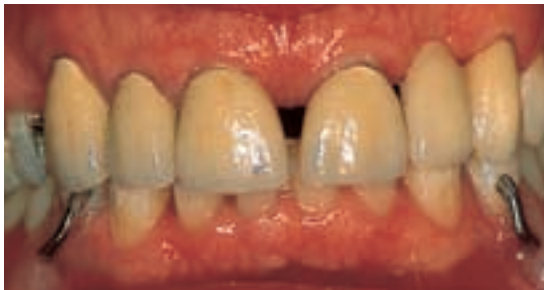*a* Gross erosion of the upper incisor teeth following a period of chronic vomiting. The patient had a peptic ulcer that had been successfully treated surgically 2 years before this photograph. The OVD is reduced because of this wear and because the lower posterior teeth are replaced only by a tissue-supported partial denture. The gingival condition at this early stage of treatment is poor.



*b* and *c* Increasing the length of the upper incisors temporarily by means of light-cured composite placed in a vacuum-formed PVC matrix. Acrylic was added to the lower partial denture to increase its occlusal height temporarily.



*d* After a period during which the patient became accustomed to the new OVD, the upper incisors were crowned and a tooth-supported partial lower denture was fitted. The gingival condition has improved. Note the supragingival crown margins, which help the patient to maintain good oral hygiene. The left lateral incisor has been extracted and replaced by a bridge.



be achieved and their use as a diagnostic tool is dubious.

The modified study cast, agreed by the patient, forms part of the contract between the dentist and patient. If the final outcome is an appearance similar to that of the study cast, it can be used as evidence that the contract has been fulfilled, and so dento-legal problems can be avoided. The

modified study cast may also be used to produce temporary crowns (see Chapter 6).

### Shade

It is wise to select the shade at this early stage, since some shades are more difficult to match

than others. It is better to know about any difficulty before the teeth are prepared, both from the point of view of warning the patient and because it may be helpful to modify the preparation. For example, if there is an extensive amount of incisal translucency, the preparation may need to be shorter to allow additional incisal porcelain than if the tooth were more opaque. Many patients these days wish to lighten the shade of their teeth with bleaching techniques. If this is anticipated, it is important that this is done before the crowns are made. Patients should be discouraged from over-bleaching their teeth as extremely 'white' shades can be impossible to match in porcelain.

### **Clinical modifications**

In some cases it may be helpful to adjust the shape of teeth in the mouth by adding composite material – particularly when alterations in occlusal vertical dimensions (OVDs) are planned. Figure 5.6 shows a patient with gross erosion treated by upper anterior crowns and a new partial lower denture with an increase in OVD. The patient's tolerance of an increase in OVD is assessed by means of the temporary additions of acrylic to the occlusal surfaces of the old partial lower denture and of composite material to the upper incisor teeth. Temporarily reshaping incisor teeth with composite to close diastemas and produce other changes are further examples.

### **Assessing the remaining tooth structure and its environment**

Existing restorations and caries, especially in badly broken-down posterior teeth, should be removed, together with any completely unsupported enamel, so that the amount and shape of the remaining tooth structure is not guesswork. Only at this point should the final restoration be planned. This preliminary cleaning away was necessary in all the examples shown in Chapter 1 (Figure 1.12), for a properly informed decision to be made.

At this stage it may also be necessary to return to a decision on further preparatory treatment.

For example, although the pulp may be vital in an anterior tooth, it may be decided that because of the weakness of the remaining coronal tissue, an elective root canal treatment and post crown is the preferred restoration. Similarly, where caries extends below the gingival margin, it may be decided to carry out crown lengthening or other periodontal surgery to alter the gingival contour.

### **The need for a core**

At this stage, when the full extent of the damage to a broken-down tooth is known, a decision is made on whether sufficient tooth substance remains for a crown preparation or whether it needs to be built up by means of a core and, if so, whether the core should be of amalgam, composite or cast metal.

At the same time, the position of the crown margin should be settled. Almost always the crown will extend beyond the core and completely cover it. However, occasionally, when part of an amalgam core is subgingival but is well condensed and smooth, it may be better to make the crown margin supragingival, leaving part of the core exposed at the gingival margin.

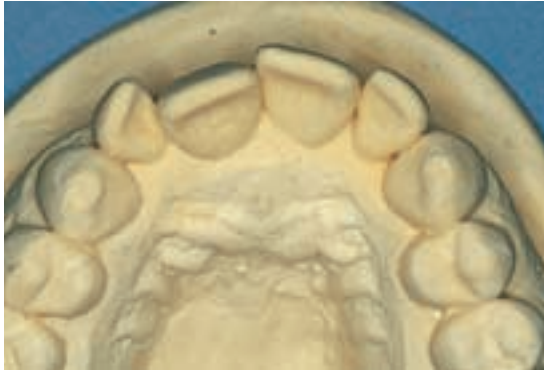
### **The choice of the type of crown and the material**

At this stage too the decision is taken between making a complete or partial crown, and what the material for the crown will be chosen.

### **Detailed design of the preparation**

Chapter 3 described the principles of crown preparation design. This is the point where they are applied to the particular tooth. In cases of doubt, for example where there are questions on the likely retentive qualities of the final preparation or on the likelihood of exposing the pulp in removing sufficient tooth tissue for a crown that is planned to change the shape of a tooth, a trial preparation on the study cast is of considerable value (Figures 5.3c and d and 5.7).

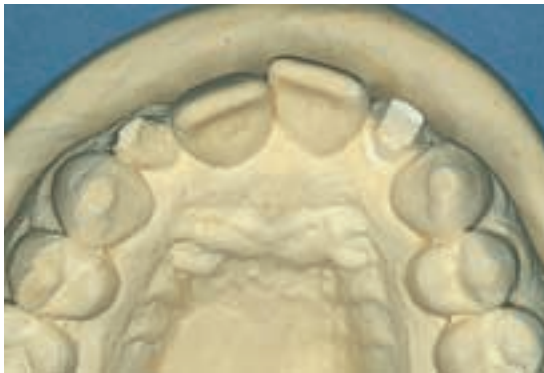





**Figure 5.7**

Trial preparations on study casts.

*a* The patient is unhappy about the appearance of the rotated lateral incisors and would like them crowned.



*b Right:* the maximum labial reduction, while preserving the vitality of the pulp, would result in this preparation, allowing some reduction in the prominence of this tooth. *Left:* however, initial preparation quickly shows that devitalization would be necessary if a crown is to be made. The patient should be encouraged to have orthodontic treatment.



*c* The upper right central and lateral incisors were almost identical to the unprepared worn teeth on the left. Trial preparations show that it will be possible to achieve a retentive crown preparation for the central incisor but not for the lateral incisor. Crown lengthening would make a retentive preparation possible.

## **Planning and executing the clinical and laboratory stages**

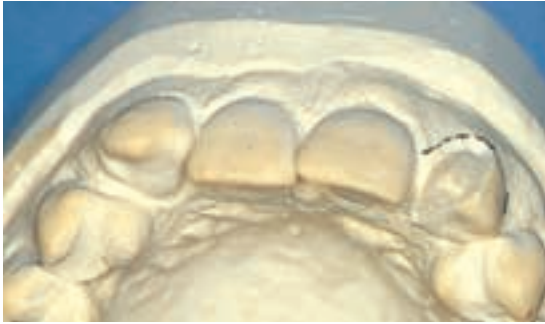### **Appointments**

The treatment plan and fee having been agreed with the patient, a series of appointments is made and agreement reached with the laboratory that the technical work can be undertaken in the time allotted. Very few dentists now carry out their own technical work and most laboratories appreciate being notified in advance when their services

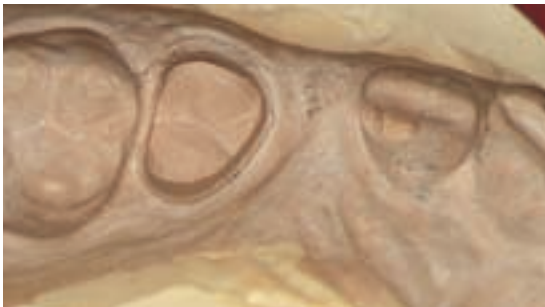will be required, at least for extensive cases. This avoids the problem of promising the patient delivery of the crown by a specified date only to find when the impression is taken that your favourite technician is on holiday.

### **Clinical and laboratory stages**

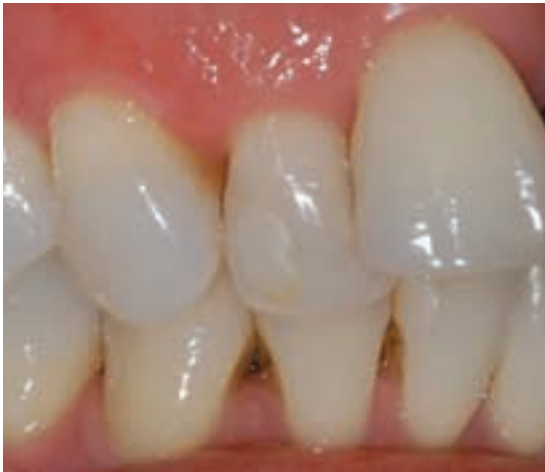Details of clinical techniques are given in Chapter 6; at this point only the sequence of events is listed (see pages 120 and 121). Depending on the number of crowns involved, the experience and



*d* The same patient as shown in Figure 5.4. Half the preparation has been completed on the upper canine tooth, showing the amount of enamel and dentine that could be removed without damaging the pulp. This is not enough to achieve a successful aesthetic result, and devitalization would be necessary. Most dentists and patients would consider this too destructive and a compromise solution with composite additions should be considered – the patient was adamant about not having orthodontic treatment.



*e* Trial preparations for a conventional fixed-movable bridge (see Part 2). These show that this design would work in this case.



*f* An instanding lateral incisor which the patient wishes to improve. They are not prepared to have orthodontic treatment.

speed of the operator and other factors, each clinical stage may be accomplished in a single appointment or in several. The patient should be advised on oral hygiene techniques appropriate to the new crown, and the crown should be examined and, if necessary, maintenance carried out at the patient's general review appointments.

It may be necessary to abort the procedure

shown on pages 120 and 121 and return to an earlier stage, either in the construction sequence or even the planning stages. For example, a damaged working model in the laboratory stage may mean returning to the first clinical stage for a new impression, or a cusp fracturing after a tooth has been prepared for a partial crown means returning to the planning stage.

## Clinical and laboratory stages of making crowns

### First clinical stage

#### All crowns (after making any necessary core)

- Select temporary crown technique and prepare for temporary crown
- Recheck shade
- Prepare the tooth to be crowned
- Make temporary crown (which helps to detect faults in the preparation)
- Impression of the prepared tooth and other teeth in the same arch with extremely accurate material (the working impression)
- Impression of the opposing arch, usually in alginate (unless the study cast is adequate for the opposing arch)
- Occlusal record (if necessary)
- Cement temporary crown
- Advise patient on maintenance of temporary crown

### First laboratory stage

#### All crowns

- Make working cast and articulate with opposing cast
- The laboratory procedure will then be different, depending upon the type of crown being made

#### Metal crown

- Prepare wax pattern
- Cast
- Polish

#### Ceramic crown

- Make refractory die
  - Apply core, dentine and enamel porcelain
  - Remove die by sandblasting
- or
- Follow instructions in making a crown in one of the alternative ceramic materials.
- Note: These materials should only be used by people who have been specifically instructed in their use.

#### Metal-ceramic

- Prepare wax pattern
- Cast
- Either add porcelain or return to clinic for try-in of the metal

#### Cast post and core

- Prepare wax pattern (or combination of wax and plastic or metal)
- Cast
- Either make crown or return to the clinic for try-in or post and core only

**Second clinical stage**

**Metal-ceramic crown**

**Cast post and core**

**Metal crown**

- Try-in crown
- Adjust, including adjustment to contact points and occlusion
- Repolish or add solder if necessary
- CEMENT

**Ceramic crown**

- Try-in crown
- Adjust and add stain or reglaze if necessary
- CEMENT

**If porcelain is added**

- Try-in crown
- Adjust and refire if necessary
- CEMENT

**If porcelain is not added**

- Try-in crown
- Adjust metal
- Reconfirm shade
- Return to laboratory

**If crown is made**

- Try-in post and core and crown
- Adjust and refire if necessary
- CEMENT both post and core and crown

**If crown is not made**

- Try-in post and core
- Either cement post and core and take new impression for crown or return post and core to laboratory

**Secondary laboratory stage**

- Add porcelain

- If new impression, proceed as for crown
- If no new impression make PJC or MC crown on the post and core

**Third clinical stage**

- Try-in crown
- Adjust
- CEMENT

- Try-in post and core and crown
- Adjust
- CEMENT both post and core and crown

**WWW.HIGHDENT.IR**

همیار دندانسازان و دندانپزشکان

## 6

# Clinical techniques for making crowns

## Planning stages before preparing the tooth

Emphasis has been placed in earlier chapters on the general approach to planning. Here the process is taken to the final, practical stages. The following factors should be considered before clinical tooth preparation is started:

- Study casts
- Photographs
- Trial preparations
- Appearance
- The final impression
- The temporary crown.

## Study casts and opposing cast

Full arch study casts are useful in a variety of planning procedures described earlier (Chapter 5) and below. In addition, the opposing cast may be articulated with the working cast, provided that it has not been damaged during the planning stages and there has been no occlusal adjustment or other restorations since the impressions for the study casts were taken.

Alginate is usually satisfactory as an impression material for study casts, but occasionally a more accurate material is required for the opposing cast: if the opposing cast cannot be poured straightaway, a more stable material than alginate should be used. Alginate material should be rubbed into the fissures with the finger to obtain good impressions of the occlusal surfaces of the teeth. If a rubber material is used, it should be syringed into the occlusal fissures.

If there is any doubt about the opposing study cast, a new impression should be taken at the time of tooth preparation to produce an accurate opposing cast.

## Photographs

When the main indication for crowning anterior teeth is to change their appearance in some way, photographs of the teeth before preparation are a valuable record. It is easy for both dentist and patient to forget the exact appearance of teeth when they have been prepared.

Good quality clinical photographs should now be a routine record in all cases where the appearance is to be changed. Digital photography has simplified this. Clinical photographs have been a standard part of orthodontic records for many years.

Patients sometimes have old photographs of themselves showing their teeth before they suffered. These can be helpful in reproducing the patient's original appearance.

## Planning the tooth preparation

A trial preparation on the study cast can be invaluable in predicting difficulties that may be encountered with preparing the tooth. For example, with short clinical crowns in posterior teeth, where the intention is to provide a porcelain occlusal surface on a metal–ceramic crown, a trial preparation on the study cast will indicate whether there will be sufficient axial length of the remaining preparation for adequate retention or whether additional devices are necessary to achieve retention. With thin upper anterior teeth, trial preparations will show whether it is possible to remove sufficient palatal tooth tissue to allow a ceramic crown preparation to be made or whether a metal–ceramic crown will be necessary. In some cases it will become clear that additional steps, such as increasing the vertical space between the incisal edges of the upper and lower teeth, or removing gingival tissues to

'crown-lengthen' the teeth will become necessary (see page 58).

There are so many similar problems that can be assessed with trial preparations that an inexperienced operator is recommended to always spend a few minutes making a trial preparation before embarking on the natural tooth.

When the intention is to alter the shape, size or angulation of incisor teeth, even the more experienced operator is well advised to make trial preparations first. These will show whether the pulp is likely to be endangered and whether problems with the appearance will arise.

Trial preparations on plaster or artificial stone study casts are best started with a steel bur in a slow handpiece and finished with a scalpel blade or chisels. The air turbine is difficult to control when cutting relatively soft materials like this.

It is helpful to do the preparation in stages, particularly if there is any question of the pulp being exposed. Figure 5.7d (page 119) shows an example with half a preparation complete so that the remaining half indicates the original shape of the tooth. The tooth could not be prepared any more than this without serious risk to the pulp.

## Planning the appearance

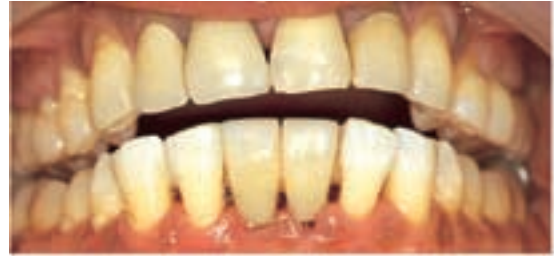### Diagnostic wax-ups

Chapter 5 gave examples of diagnostic wax-ups with alternative treatment plans for the same clinical situation.

Ivory wax is preferably to other waxes since it is easy to carve and gives a reasonably realistic appearance. However, pink wax, inlay wax or other material may also be used.

### Shade

One reason for matching the shade before starting tooth preparation was described in Chapter 5. A second, very basic reason is that when shade matching (one of the most crucial parts of the procedure) is left to the end of a long appointment, the operator and patient are tired and the operator's vision is not at its best, so the process may be hurried and mistakes made. Besides, teeth may change shade slightly during a long operative



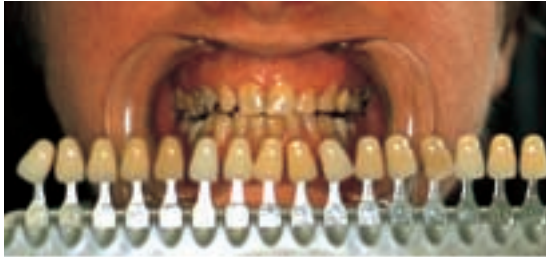**Figure 6.1**

The lower central incisors are bridge pontics for a minimum-preparation bridge (see Part 2). They are a good shade match to the natural upper incisor teeth but the lower lateral incisors and canines have become temporarily whiter because they have been isolated under rubber dam for some time while the minimum preparation bridge was bonded. This has resulted in them drying out and the shade lightening. They will revert to the normal shade an hour or so after the rubber dam has been removed. This phenomenon may occur to some degree during impression taking and making temporary crowns. Hence the advice to take the shade prior to starting tooth preparation.

appointment. It is well known that teeth change colour dramatically after a period of time under rubber dam (Figure 6.1). Although rubber dam is not normally used for crown preparations, it is possible that after an hour or so of wetting and drying and then several minutes in contact with a rubber impression material, the shade of the tooth to be matched may be altered.

### Technique for shade selection

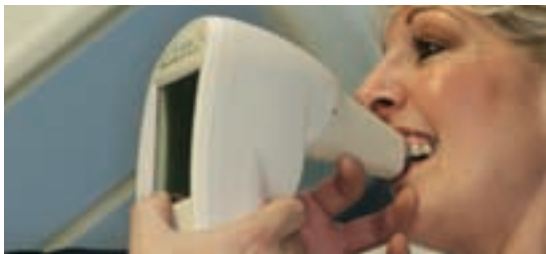The lighting conditions are very important. Traditionally shades are selected in natural daylight rather than artificial light. However, there are practical problems with this. Daylight is very variable in its intensity; and it is not always possible to make appointments during the hours of daylight. It is anyway equally important that the

**Figure 6.2**

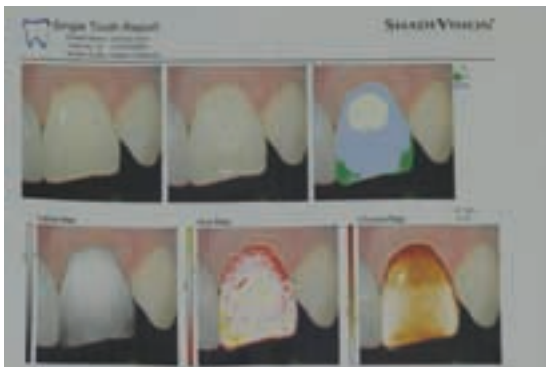*a* Using a traditional shade guide to select the basic hue. The upper left central incisor is in fact a ceramic crown made from a combination of the two shades immediately below it. More commonly individual tabs would be removed and compared to the tooth to be matched.



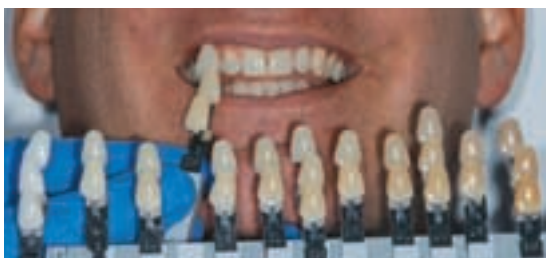*b* A standardized light source can be used to remove the risk that the shade is influenced by the ambient lighting.



*c* and *d* An example of a shade-taking device that digitally analyses the shade of a tooth and produces a print out of the shade in detail.



*e* More detailed shade guides are available including shades specially formed to match to bleached teeth (see those on the lower left).





crowns appear to be the correct shade in both artificial light and daylight. Many people spend a large part of their working and social lives in artificially lit surroundings.

Dentists often now match the shade both in daylight and in different forms of artificial light (tungsten filament and fluorescent).

Alternatively, a standardized artificial light source designed to be a close approximation to natural daylight may be used. It is of course important that the technician has a similar light source (Figure 6.2b).

Various devices are available to record shade automatically with variable accuracy. The shade of the tooth is analysed and a prescription to copy the shade with differing porcelains is printed for the laboratory (Figure 6.2c). With experience both at the chair side and in interpreting the prescription in the laboratory these systems can give predictable results.

Involving the dental technician in taking the shade is an excellent idea; first because it gives two opinions, but also because it allows the technician to meet and see the patient and their actual clinical situation, usually producing a better result. Further information on shade can be given to the laboratory by taking a photograph of the tooth with the selected shade guide in position (Figure 6.2e).

Modern dental unit lights are designed to provide a reasonable colour balance, and if this is adequate then using the unit light has the advantages of consistency and convenience.

Colour is said to have three dimensions: hue, chroma and value. Hue is the colour itself (e.g. red compared with green). Chroma is the amount of colour (e.g. red compared with pink) and value is the darkness or lightness of the colour (the shade of grey that the colour would appear if seen on a black and white photograph). Many shade guides for dental porcelain are arranged in groups representing different hues, with a gradation of chroma within each hue. Figure 6.2a shows a typical shade guide with four hues (light brown, yellow, blue/grey and a pinkish hue) designated A, B, C and D. Within each group, differences in chroma are indicated by a number. For example, B2 is a fairly light yellow shade, whereas C4 is a much darker blue/grey.

In addition, many shade guides have different neck, body and incisal edge shades on them. The incisal edge is also made more translucent.

Shade selection usually follows these lines:

- Choose the appropriate lighting conditions or take the shade in a variety of different lighting conditions
- Look at the whole mouth and make a general assessment of the appropriate hue – whether the teeth are generally brown, yellow or grey
- Look more closely at the tooth to be crowned, the adjacent teeth and the contralateral tooth, and decide the hue or mixture of hues (the letter on the shade guide)
- Select the chroma (the number)
- Choose the blend of neck, body and incisal shades. It is not necessary to select the neck, body and incisal edge shades from the same shade button, and it is possible to mix porcelain powders so that shades between those on the shade guide are produced
- Decide whether any other characteristics such as crack lines, areas of opacity or increased translucency are required.

It is helpful to draw a shade map of the tooth. Figure 6.3 shows a tooth with its shade map.

Some dentists and technicians prefer a shade guide consisting of 'shades' made by fusing a small button from each of the single porcelain powders.

Others find the combination of shades on the commercial shade guides confusing, and grind off the neck (which often has surface stain added) and incisal portions, leaving a single body shade.

### **Planning the impression**

The impression technique should be decided before preparing the tooth. Some impression materials are better used in a special tray, and this is made on the study cast. Other impression materials can be used in stock trays. If a stock tray is used it must be possible to seat it without distortion by contact with the teeth or soft tissues. It is essential that good quality stock trays are used which are not too flexible.

Generally a special tray is chosen if multiple crowns are being made or the patient has an arch size or form that a stock tray does not fit. Special trays, if properly made, are rigid and will not distort. They cost more than stock trays but this is partly offset because they require less impression material.

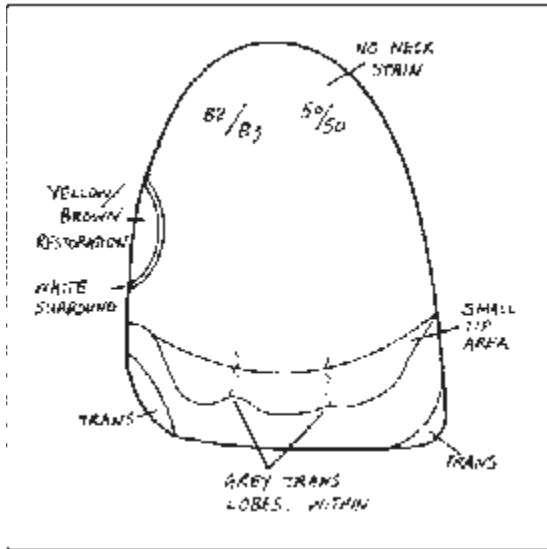
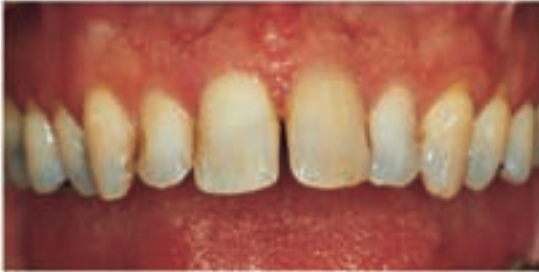

Figure 6.3

a and b A shade map of this patient's upper right central incisor.

### Making a special tray (Figure 6.4)

When a special tray is to be used it can be made from self-curing acrylic or light-curing acrylic. At one time shellac and vacuum-formed materials were used but they are not sufficiently rigid or stable and so they should now be regarded as obsolete as far as impressions for crowns and bridges are concerned.

To make a special tray a wax spacer approximately 3 mm thick is laid down over the study cast. This is perforated through to the occlusal surface of three or four teeth that are not to be prepared for crowns. The purpose of these perforations is to allow tray material to form stops on the occlusal surfaces of the teeth. This

will localize the tray in the mouth and prevent it making contact with the prepared teeth. The tray is then formed by moulding acrylic dough or a sheet of light-curing acrylic over the study cast.

Figure 6.4 shows the stages in making special trays in the two materials. Self-curing acrylic is convenient and inexpensive and does not require special equipment. Self-curing acrylic special trays can be made in the dental surgery. Light-curing acrylic special trays are quicker and easier to produce and give more consistent results. However, it is necessary to have a light-curing box in which to cure the tray, and the cost of this would not normally be justified for surgery use. The trays are therefore made in the laboratory. There is usually little difference in cost

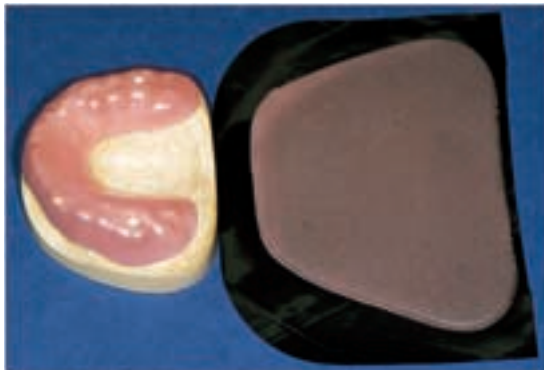
**Figure 6.4**

*a and b* Making a self-curing acrylic special tray.

*a* shows a study cast with a wax spacer with holes made in it. The holes have been filled with self-curing acrylic. Self-curing acrylic has been rolled out and shaped together with a handle.



*b* The tray has been moulded over the study cast and spacer and the handle attached. The stops, located over teeth which are not to be prepared, prevent the tray from seating too closely onto the prepared teeth.

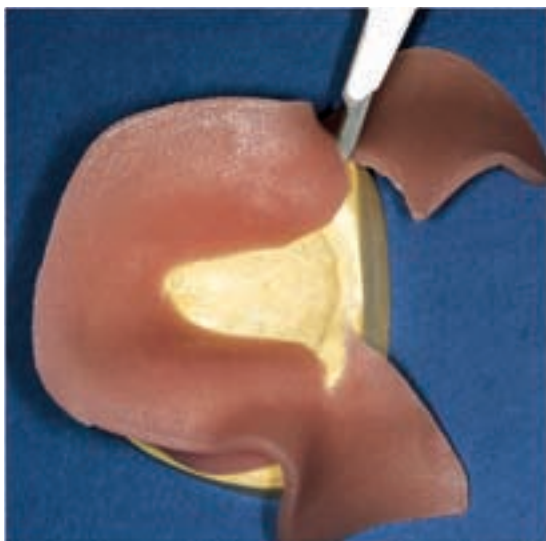


*c-g* The construction of a light-cured acrylic special tray.

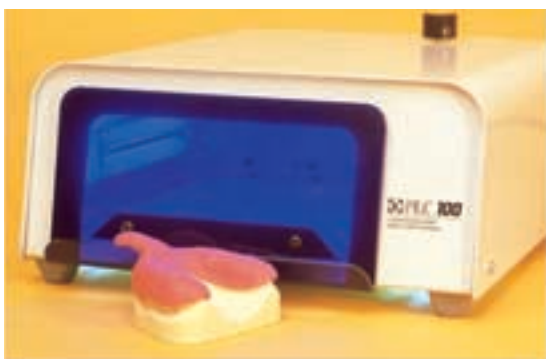*c* The study cast and wax spacer together with a preformed blank of light curing acrylic material.



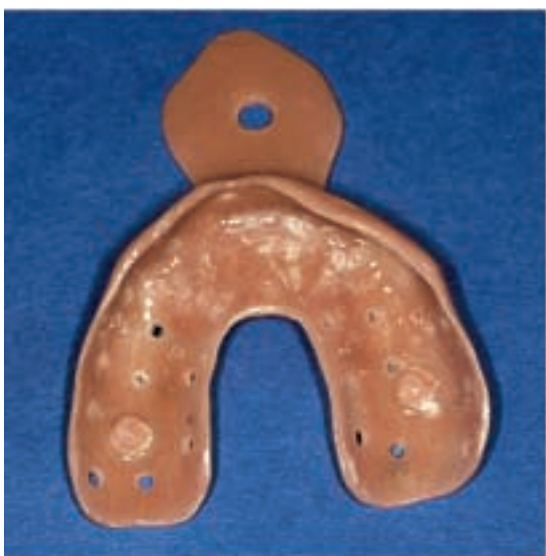*d* The blank is roughly shaped, producing a handle.



e It is moulded over the study cast and trimmed with a scalpel.



f The light curing box with the bright blue light turned on.



g The finished tray with stops.

between the two types of tray if they are laboratory-produced. Light-cured materials have the advantage of being quick and will be dimensionally stable once light-cured, whereas self-curing trays need to be made 24 hours previously to allow for polymerization shrinkage to occur.

### **Planning the temporary crown**

Temporary crowns may be either purchased as preformed units or made at the chair side in a suitable mould.

#### **Preformed temporary crowns**

The following types of preformed temporary crown are available:

- Polycarbonate, tooth-coloured temporary crowns for anterior and some posterior teeth
- Stainless-steel posterior temporary crowns
- Aluminium posterior temporary crowns.

When one of these is to be used the appropriate size can be selected before the tooth is prepared using the study cast as a guide.

Polycarbonate temporary crowns are preferred as they are relined with acrylic or other resin material in the mouth and can therefore be trimmed to a better marginal fit than metal temporary crowns.

#### **Chair-side temporary crowns**

Temporary crowns can be made in the mouth, using one of the higher acrylics, usually consisting of a mixture of poly(ethyl methacrylate) and poly(isobutyl methacrylate), sometimes with a nylon fibre filler. Alternatively acrylic-poly(methyl methacrylate), epimine resin or amalgam may be used. The mould that is used to form the temporary crown may be one of the following:

- A preformed celluloid crown form
- A vacuum-formed PVC crown form made on a study cast or a modified study cast of the patient's mouth
- A silicone putty impression of the study cast

- An alginate or silicone impression of the mouth taken before the tooth is prepared.

The use of these materials and moulds is described on pages 150–153.

### **Laboratory temporary crowns**

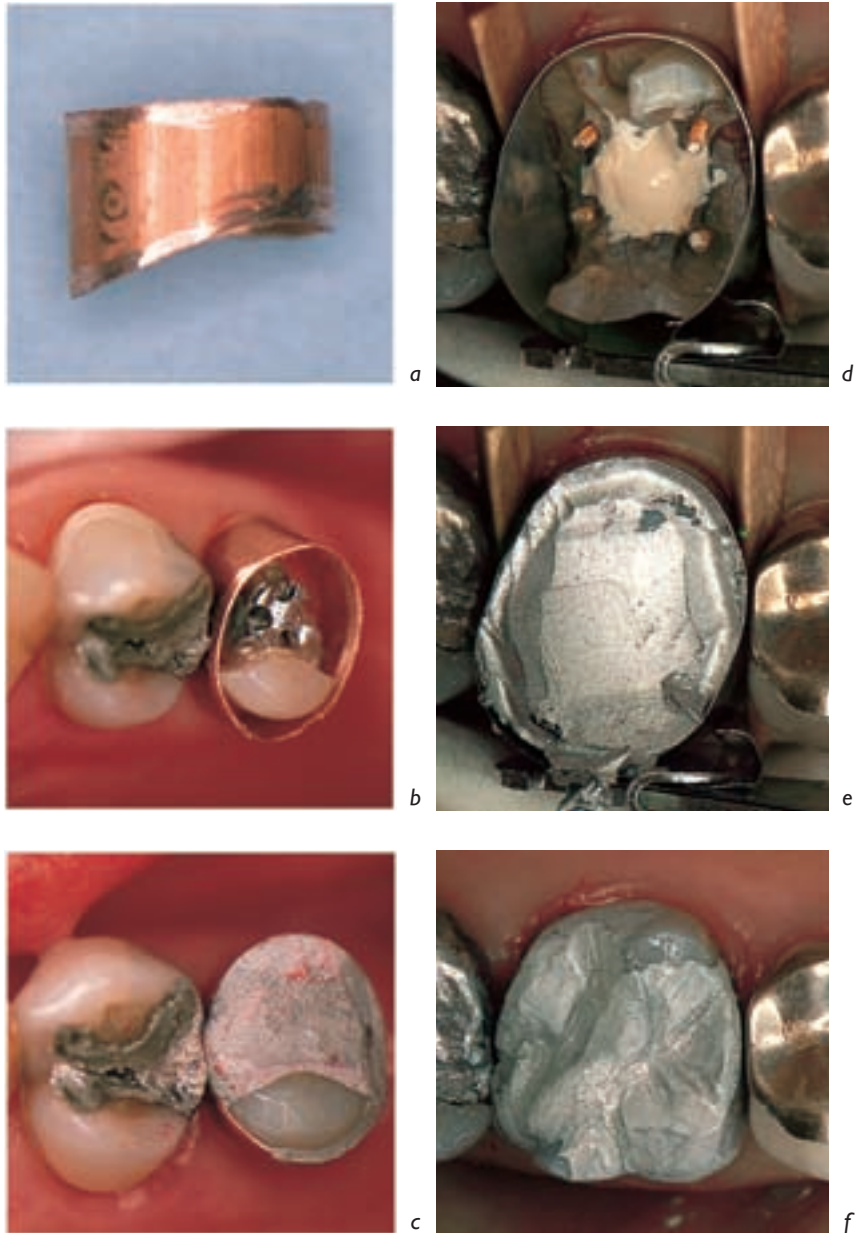
Temporary acrylic or composite crowns can be made in advance from the model following diagnostic preparations. These will need to be relined in the mouth. The potential advantages are minimal considering the clinical time taken and the extra laboratory costs. This is in contrast to laboratory-made provisional crowns – see later – for the difference between temporary and provisional crowns.

### **Building up the core**

As described in Chapter 2, cores may be made of cast metal retained by a post, or of amalgam or composite retained by posts or pins when required. Techniques for constructing post and pin-retained amalgam cores are illustrated in Figure 6.5. Other cores are shown in Figure 2.7 (pages 48–50). With a composite core the tooth can be prepared at the same visit. The site and angulation of pins is crucial (see Chapter 2). The detailed design of the preparation must be decided before the pins are placed; otherwise, if the pins are in the wrong place, they may be cut off during the preparation of the core for the crown.

### **Managing worn, short teeth**

Figure 6.6a shows some very worn and short upper anterior teeth. They have continued to erupt as they have worn, and so remain in contact with the lower incisor teeth. The gingival margins have migrated incisally, following the further eruption of the teeth. The upper and lower posterior teeth remain in contact. The upper incisor teeth are to be crowned to improve their appearance and prevent further



**Figure 6.5**

Post- and pin-retained cores and Nayyar cores.

*a* A copper band trimmed to shape and the margins smoothed.

*b* Band in place ready to receive amalgam. Retention in this root-filled tooth is provided by a preformed post (see Figure 2.7).

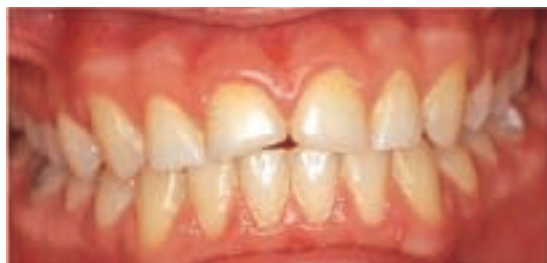*c* The amalgam core placed. Note that the gap between the remaining cusp and copper ring has been filled with

amalgam so that the edge of the copper ring does not irritate the tongue. The amalgam will fall away when the copper ring is removed at the next visit. As the copper band will be left in place, the amalgam can be left in occlusion – note the marks from articulating paper.

*d* Pins, lining, matrix and wedges placed. Pins are used when the pulp remains vital.

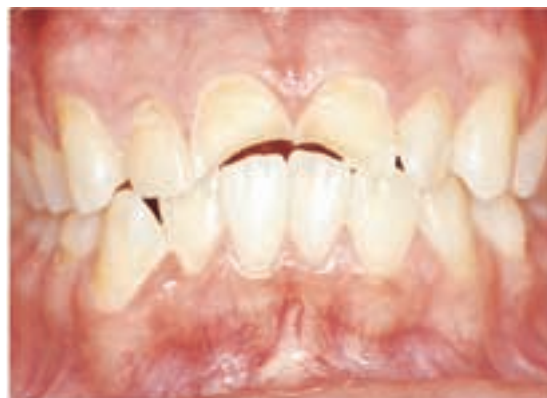*e* Amalgam placed.

*f* Matrix removed and amalgam roughly carved. The amalgam is left out of occlusion to avoid undue stresses before the crown is placed.

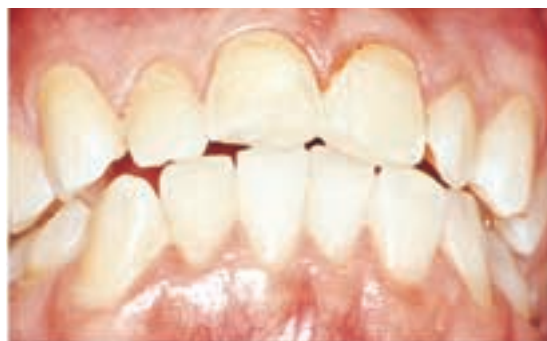

**Figure 6.6**

*a* A patient who has suffered from bulimia nervosa producing extensive palatal and incisal erosion of the upper incisor teeth. Continuing eruption has kept pace with the erosion and so the upper and lower incisor teeth are still in contact.



*b* A similar case, again caused by an eating disorder, but this time predominantly affecting the incisal edges of the upper central incisor teeth.



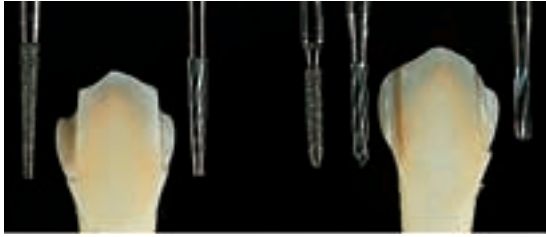*c* The central incisors have been built up with composite which improves their appearance for the time being but also acts as a form of Dahl appliance which will depress both upper and lower incisor teeth. Note that the composite restorations are in contact with the lower incisors and yet the canine and posterior teeth are out of occlusion.

wear (other preventive measures having been unsuccessful), but the length of the crowns is not sufficient to produce satisfactory preparations and crowns with a good appearance.

There are a number of ways to overcome this problem:

- A fixed anterior biteplane (a fixed Dahl appliance), is cemented to the upper incisor teeth. This is designed to hold the anterior teeth

apart by the amount that is needed for tooth preparation. Once cemented, the posterior teeth do not occlude, but patients cope with this very well. In 3–6 months the anterior teeth are intruded and/or the posterior teeth over-erupt so that they come into occlusal contact. At this stage the fixed Dahl appliance is removed and the teeth are prepared for crowns without removing any more dentine from the worn palatal surfaces or incisal edges

**Figure 6.7**

A selection of burs and the surfaces prepared by them. In all cases the bur was used entirely within the contour of the tooth and would not have damaged the adjacent tooth. *From the left:* a square-end tapered diamond bur, a square-end tungsten carbide bur, both producing narrow shoulders; a parallel-sided but pointed diamond bur, with the matching tungsten carbide finishing bur; a round-ended parallel-sided plain cut tungsten carbide bur, these last three producing chamfers.

(Figure 4.6a–g). The original Dahl appliance was a removable cast metal anterior biteplane retained by clasps on posterior teeth. However, this has now been largely superseded by the fixed appliance.


- Restoring the worn surfaces with composite to act in the same way as a Dahl appliance (Figures 4.6h and i and 6.6b and c).
- The upper anterior teeth may be prepared for crowns, without removing any dentine from the worn palatal surfaces or incisal edges, and then provisional crowns made to the length and shape that is required for the permanent crowns. These will act in a similar way to the fixed Dahl appliance. However, the disadvantage is that the teeth are prepared before the tooth movement has been established.
- The incisal teeth may be depressed and/or the posterior teeth allowed to over-erupt by conventional orthodontic treatment. The inter-incisal space created means that the worn incisal surfaces do not need to be prepared, and the gingival margins migrate upwards as the incisor teeth are intruded. This is the technique of choice in some cases, but the disadvantage is that the patient needs to wear an orthodontic appliance, which is usually visible.
- Crown-lengthen the teeth by means of a periodontal surgical procedure to remove gingival tissue and usually bone. This is destructive if the gingival tissues are healthy and is usually quite painful for the patient. It can produce sufficient length for retentive crown preparations, but the worn incisal surface has

to be prepared and so there is a risk to the pulp. The neck of the preparation is placed part way up the tapering root, and so is of a smaller diameter than if it were at the cement–enamel junction. This means that the interdental spaces are usually greater, and this can spoil the appearance.

- Increase the whole occlusal vertical dimension (OVD) by crowning all the teeth in the upper arch. This is sometimes necessary if the OVD is reduced and if the posterior teeth need crowning in any case. However, it is unjustifiably destructive if the posterior teeth do not need crowning and is likely to fail if a normal OVD is encroached upon artificially. It is possible for intact posterior teeth to be built up to an increased OVD by the direct bonding of composite materials but in the long term these will not be stable enough to maintain the occlusal form. If the problem is the other way round and the posterior teeth require building up with crowns to a new OVD and the anterior teeth do not, building up the palatal surfaces of the upper incisors with composite may well be stable for long periods of time as the risk of wear and overloading is less.

Of these techniques, the fixed Dahl appliance or composite additions are preferred whenever possible. Provisional crowns or conventional orthodontic treatment are the next best, and crown lengthening and increasing the OVD overall should be preserved for those cases where there are specific indications for these techniques.





**Figure 6.8**

An occlusal record taken in 2 mm thick soft wax, which does not require warming. The occlusal contacts of the unprepared first and third molar teeth can be seen together with the imprint of the second molar preparation. It is clear that there is nearly 2 mm clearance, and this is sufficient for a metal–ceramic occlusal surface.

## Tooth preparation

### Choice of instruments

The major part of the preparation is carried out with the airtor. Diamond burs are preferred for preparing enamel, and either diamond or tungsten carbide burs for amalgam and dentine.

The shape of the bur or stone should be chosen to match the contour of the surface that is being prepared. This includes the shape of the margin, so that if a shoulder is being prepared, a square-ended straight or tapered bur should be used. Alternatively, if a chamfer finishing line is being prepared then an appropriately shaped bur should be chosen. Figure 6.7 shows a selection of burs set against the tooth surfaces they have prepared.

It is easier to control the preparation of the concave palatal surface of upper incisor teeth if a large diameter diamond bur, matching the contour of the tooth, is used.

The finishing is an important stage and can take rather longer than the main bulk reduction. The purpose is to finalize the shape of the preparation, rounding off angles where necessary, ensuring that the margin is properly located in relation to the gingival margin and is the correct contour and dimension. In addition, coarse undercuts resulting from diamond score marks should be removed and the surface of the preparation left reasonably smooth. Otherwise there will be difficulty with removing a wax pattern from the die and with cementation. There is, however, no need to polish preparations: a very slight roughness helps retention (Figure 3.9, page 62).

Slow-speed handpieces with steel finishing burs or fine stones can be used for finishing; however,

it is more commonly done at medium to high speed with plain tungsten carbide burs or fine-grain diamond burs.

### Stages in the preparation

It is usual to prepare each surface in turn so that the amount of tooth reduction can be controlled. Establishing how much tooth has been removed can be done in a number of ways. At the margin the width of the shoulder or other finishing line can be seen directly. Where the tooth being prepared occludes with opposing teeth, and other adjacent teeth also occlude, the amount of tooth tissue removed from the occluding surface is assessed by direct observation or by the patient biting through soft wax; the thickness of the remaining wax shows how much tooth has been removed (Figure 6.8). On other surfaces, half may be prepared first, leaving a step between the prepared and unprepared areas so indicating that amount of tooth tissue removed (Figure 6.10c). Alternatively, a groove may be prepared across the surface to the intended depth of the preparation and the remainder of the surface then prepared to the depth of the groove (Figure 6.10b).

Another useful technique to ensure that adequate tooth reduction has been made is to make a silicone putty matrix of the tooth or its diagnostic wax-up prior to starting and section this through the centre of the tooth. Placing it onto the preparation shows whether further reduction is required (Figure 6.10g).

The order in which the tooth surfaces are prepared will depend upon the circumstances and

the operator's preference. However, for the inexperienced, some basic guidelines may be useful. Surfaces that are easy to prepare and that will improve access to more difficult surfaces should be prepared first. For example, with incisor teeth some operators prepare the incisal edge first in order to remove part of the approximal surfaces and improve access to the remainder of them. Similarly, the most difficult surface should be left until last.

It is best to initially prepare the tooth, leaving the margin well supragingival until the basic preparation is completed, and then assess and refine the preparation taking the margin down to the appropriate gingival level.

Sometimes with a difficult path of insertion, the direction of one surface is critical. In this case it should be prepared first and the other surfaces prepared relative to it. When grooves are to be used as part of the preparation, they are left until last and aligned with other prepared surfaces to form part of the overall retentive design.

## Preparing teeth for complete posterior crowns

Figure 3.15 (page 68) shows a typical sequence in the preparation for a complete gold crown of a posterior tooth that has been built up with a pinned amalgam core. Figure 6.9 shows a premolar with a composite core prepared for a metal–ceramic crown.

## Occlusal reduction

The shape of the prepared occlusal surface should follow the general contours of the original tooth surface. In some cases, with heavily worn teeth, this will be flat, but in others the general shape of the cusps should be reproduced. This allows the crown to be of reasonably uniform thickness with minimum preparation of tooth tissue.

A convenient instrument to prepare the occlusal surface is a dome-ended parallel-sided diamond bur held on its side. With this instrument it is possible to form the cuspal inclines together with a rounded shape to the fissure pattern.

The occlusal relationships of the tooth being prepared should be studied in function. For example, in preparing a posterior tooth, if the guidance in lateral excursion is carried by the tooth being prepared, the cusp (or cusps) that carry this guidance should be prepared rather more, so that there is a greater thickness of crown material covering them. This will produce greater strength in this stressed area and will also allow for future wear. In these circumstances the cusp in question is known as the 'functional cusp'. However, in most natural dentitions the posterior teeth disclude in lateral excursion and so none of the cusps can be described as 'functional' in the same sense. Therefore they do not need to be reduced any more than the remainder of the occlusal surface.

The term 'functional cusp' is sometimes used inaccurately as an anatomical term. For example the buccal cusps of lower molar teeth are sometimes called 'functional cusps' even if they disclude in lateral excursions. They would not be described as 'functional' on an extracted tooth. 'Functional' is a physiological term. It is more important to assess what the cusp does rather than where it is before deciding whether it needs to be reduced more than the other cusps.

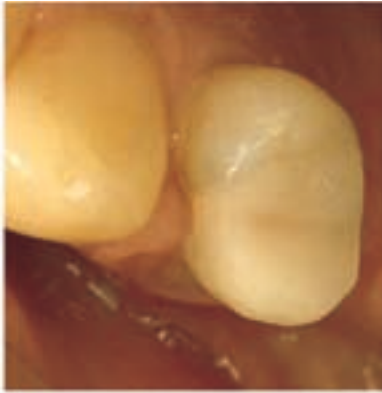One advantage of minimizing the reduction of the occlusal surface is to maintain the axial walls of the preparation as long as possible, thereby improving retention.

The amount of reduction will depend on the material being used on the occlusal surface. Metal occlusal surfaces should be at least 0.5 mm thick, or more if they are in occlusal contact in a patient who grinds their teeth. Metal–ceramic crowns require a minimum of 1.5 mm and all ceramic crowns 2 mm.

## Axial reduction

### Buccal and lingual surfaces

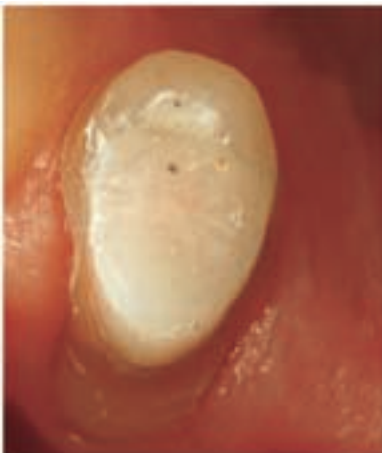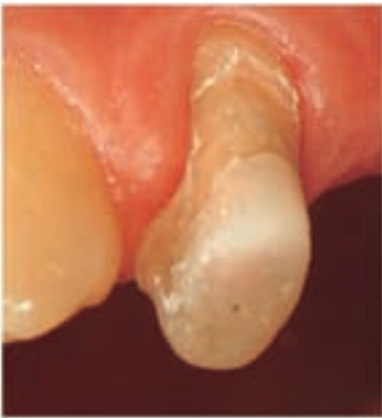These may be prepared with parallel-sided or tapered diamonds of appropriate length and with the end shaped to produce the required shape of margin. It may be possible to use a diamond of known taper held at a constant angle on the buccal and lingual sides, so that the taper of the preparation can be controlled. However, this



**Figure 6.9**

Crown preparation for a metal–ceramic crown.

*a* The pin-retained composite core has been present for several months. The appearance is better than an amalgam core.



*b* and *c* The finished preparation.

often has to be modified because of the curvature of the tooth's surface, previous restorations or the presence of a core. A fairly large diameter instrument is convenient and reduces the likelihood of vertical ridges in the preparation.

### Mesial and distal surfaces

These are the most difficult surfaces to prepare if there is an adjacent tooth in contact; without one, they are prepared like the buccal and lingual surfaces. Sometimes both adjacent posterior teeth are to be crowned, and then the surfaces in contact should be prepared simultaneously, the reduction of each being minimized.

Unfortunately, damage to adjacent teeth is common, with some studies showing over 90% of adjacent teeth damaged even by careful operators who knew their work would be inspected. When the preparation is finished the adjacent tooth surface should always be checked for damage, and if necessary smoothed, polished and fluoride applied.

It is almost impossible to prepare the approximal surfaces of a posterior tooth when there are teeth in contact on either side without either over-tapering the preparation, removing more tooth tissue than is desirable or damaging the adjacent teeth (Figures 3.12 and 6.7).

Very thin long tapered diamond burs are passed through the approximal surface in an attempt to leave a sliver of enamel (or core) between the bur and the adjacent tooth. Controlling the angle, position and depth of this bur without wavering or going off course is one of the most skilful procedures in operative dentistry and deserves many hours of practice on extracted teeth in models before it is attempted in the mouth.

A matrix band may be applied to the adjacent tooth to protect it, but this interferes with vision and access, and is in any case cut through very easily. A wooden wedge at the gingival margin to separate the teeth slightly may help.

### Margins

The shape of the margin will be determined by the shape of the end of the bur used for the axial reduction. This may be flat, producing a shoulder,

or chamfered if the bur has a rounded end. A knife-edge finishing line is produced by the side of the bur only being used, the tip not cutting the tooth. It is more efficient to produce the required shape of margins during the bulk preparation stage rather than as a secondary procedure.

### Finishing

Suitable finishing instruments are used as described on page 140. It is important that the angles between the axial and occlusal surfaces are rounded for reasons described in Chapter 3.

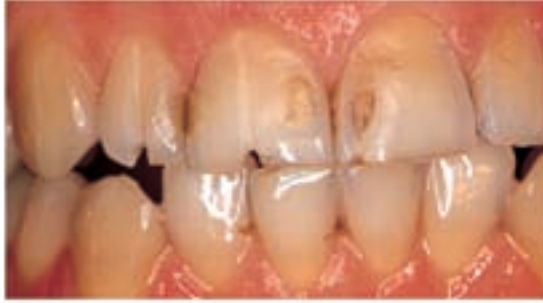### Preparing teeth for complete anterior crowns

Figure 6.10 shows stages in preparing an upper incisor tooth for a ceramic crown. The stages of preparation of a tooth for a metal-ceramic crown are similar, although the end result is rather different, complying with the principles described in Chapter 5. If a tapered or parallel-sided diamond bur of appropriate length and diameter is selected, the first three stages of the preparation can all be carried out with the same instrument, with only the incisal-palatal reduction and finishing left to be done with different instruments.

### Incisal and proximal reduction

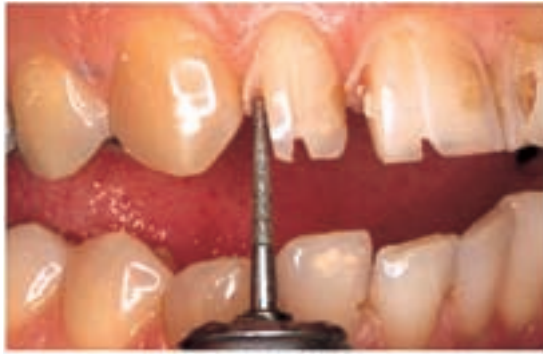When only one tooth is being prepared the incisal surface can be reduced with the shank end of the tapered diamond bur and the adjacent teeth used as a guide to the amount of reduction necessary. When a series of teeth is being prepared, either alternate teeth are reduced first with the unprepared teeth used as a guide, or half the incisal edge is reduced followed by the second half to the same depth.

In patients with a Class I incisor relationship the upper incisor teeth have their incisal edges inclined lingually and the lower incisors labially. The same inclinations are preserved in the prepared teeth.

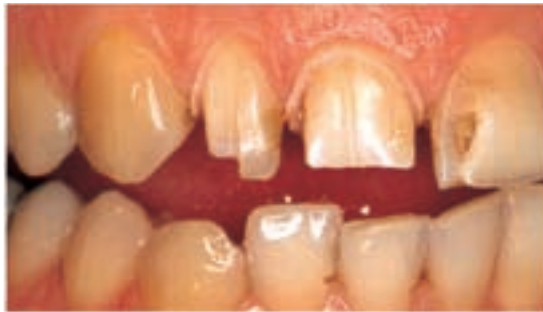**Figure 6.10**

Stages in the preparation of upper incisors for ceramic crowns. The indication for crowns was progressive erosion of the buccal surfaces and unsightly restorations that rapidly discoloured after replacement. The first three stages were carried out with a long-tapered diamond bur. Finishing was with plain-cut tungsten carbide burs in a 1:4 ratio speed increasing contra-angle handpiece. The stages in the preparation for metal–ceramic crowns would be very similar except that the palatal surfaces would be prepared with a suitably shaped bur.

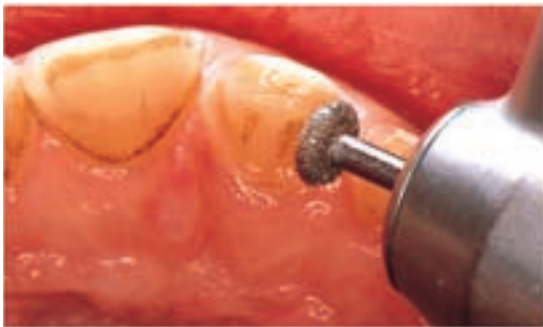*a* Reference grooves are cut in the buccal and incisal surfaces to establish the depth of the preparation.



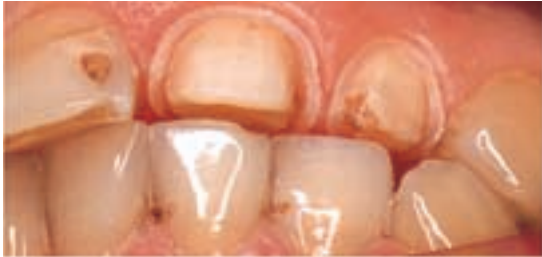*b* Distal surfaces being prepared. Note that a sliver of enamel has been preserved at the contact point of the lateral incisor to protect the canine from damage. This will fall away as the preparation is carried further gingivally.



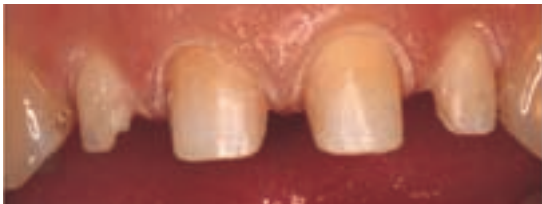*c* The incisal reduction of the central incisor has been completed together with half the incisal reduction of the lateral incisor.



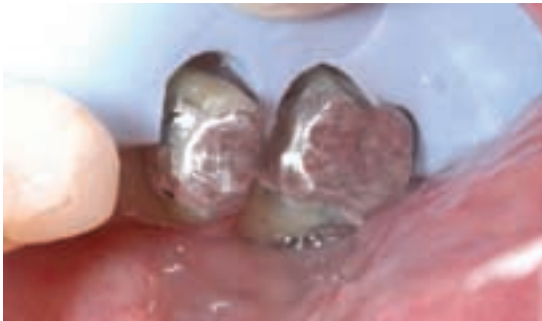*d* Palatal reduction with a round-edged wheel bur in an airator.



e Checking, with the teeth in occlusion, that there is sufficient clearance for porcelain.



f The finished preparations. The right lateral incisor has lost a mesial composite. This defect will be made good with glass ionomer cement before the impression is taken. The finished crowns are shown in Figure 2.1a (page 30).



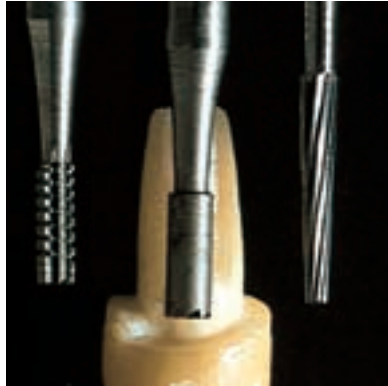g A silicone putty matrix made from a diagnostic wax up is held against the teeth being prepared to ensure that the correct amount of tooth reduction has been carried out. There is adequate space for a metal-ceramic restoration on the premolar tooth but further preparation is required to the mid-buccal area of the molar tooth behind if a metal-ceramic restoration is to be provided to the contour of the diagnostic wax-up.

Approximal reduction may be continued with the same bur. Because so much more tooth is being removed than is necessary for a posterior metal crown and since incisor teeth are a more favourable shape and the buccal/lingual dimension at the contact point is smaller, it is much easier to prepare the approximal surfaces without damaging the adjacent teeth than in the case of posterior crowns. Passing the bur through the mesial and distal approximal surfaces (leaving a sliver of enamel) establishes the taper of these surfaces as well as the location and width of the approximal shoulders.

### **Labial reduction**

The contour and depth of the labial shoulder is established with the tip of a diamond bur. A

common mistake in preparing upper incisor teeth for crowns is to remove insufficient material from the labial/incisal third of the preparation because the labial surface is curved rather than straight and so the tooth reduction needs to follow the tooth contour in all planes. This results either in a crown that is too thin, so that the opaque core material shows through (Figure 3.2, page 55), or in a bulbous crown. The amount of tooth reduction in this area can be fixed by a buccal depth indicator groove being cut down the buccal surface and the remainder of the surface reduced to the same depth. With large teeth or where the alignment of the buccal surface is being altered, more than one groove may be needed. In reducing the remainder of the surface, the bur should be used at an angle to the depth groove to prevent it dropping into the groove and deepening it unintentionally. A sectioned putty matrix is very useful.



**Figure 6.11**

Three burs used to finish a shoulder preparation. *Left*: a steel slow-speed bur cutting both on the side and at the end. *Centre*: an end-cutting bur that has produced a ledge; it would be difficult to eradicate this without lifting the bur from the shoulder. End-cutting burs are now seldom used. *Right*: a plain-cut tungsten carbide tapered side and end-cutting bur, which is best used in a friction grip 1:4 speed increasing handpiece. The tungsten carbide bur produces the best finish most conveniently.

### ***Gingival-palatal reduction***

For a ceramic crown the same bur is continued round the palatal surface, producing the palatal shoulder and a short gingival palatal wall nearly parallel to the buccal-gingival surface.

These three stages, using the same bur, can all be carried out very quickly provided that the operator has planned the design properly and has thought through the sequence.

### ***Incisal-palatal reduction***

This surface is usually concave and is best prepared with a large diameter instrument, for example a large wheel bur in the air turbine (Figure 6.10d). Small instruments produce an undulating surface, which is difficult to finish smoothly. The occlusion between this surface and the opposing teeth should be checked before the preparation starts, and constantly rechecked during preparation until sufficient space has been produced for the crown material.

### ***Finishing***

The prepared individual surfaces should be blended into each other to produce a rounded shape during the gross reduction. The axial

surfaces are finished and the angles around the incisal edge rounded, using a suitable finishing instrument. An excellent finish can be produced by using a plain-cut tungsten carbide friction grip bur in a 1:4 speed increasing contra-angle handpiece. The shoulder can be finished using the same instrument or steel burs (Figure 6.11).

### **Preparing anterior teeth for post crowns**

There are three stages:

- The shoulder or other margin is prepared
- The post hole is prepared
- Any remaining dentine between the two is reduced as necessary.

The margin is prepared as for a ceramic or metal-ceramic crown, but because there is no pulp to protect, there can be more reduction so that the shoulders are wider than for an equivalent vital tooth and therefore the crown thicker.

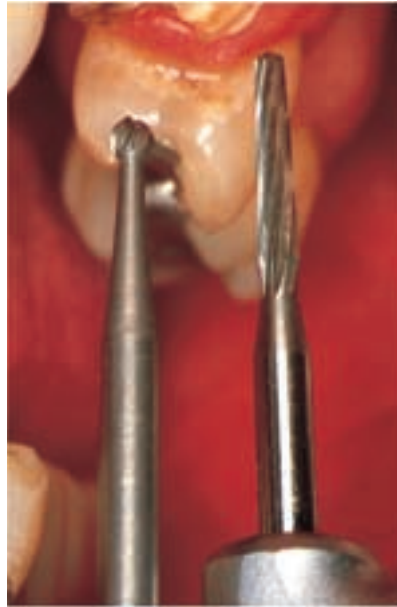### ***Post hole preparation***

#### **Removing the root canal filling**

When the root canal filling consists of gutta percha (GP) and sealer, the coronal part may be



a



b

**Figure 6.12**

Post-hole preparation.

a Long-shank round burs (left) and Gates-Glidden burs for removing gutta percha from root canals.

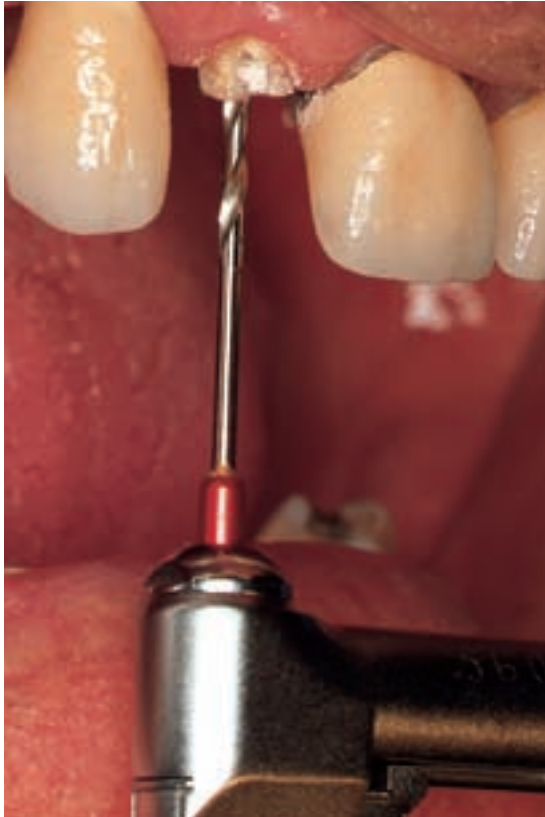b Extra long shank contra-angle burs allow access without the head of the handpiece clashing with adjacent teeth. They also improve visibility.

removed with Gates-Glidden or round burs (Figure 6.12) or by softening it with heated metal instruments. Provided that the root filling is well condensed, a convenient method is to cut out the GP root filling with a slowly rotating round bur or twist drill slightly larger in diameter than the root canal. If too small an instrument is used, or too fast a speed so that the GP melts, it becomes attached to the bur and the whole of the root filling may be pulled out when the bur is removed. Using a bur or drill slightly larger than the root canal enables the root filling to be cut away from its end

without the sides of the GP point becoming entangled in the bur. Extra long shank contra-angle burs are useful in long teeth. With normal length burs the head of the handpiece clashes with the adjacent teeth.

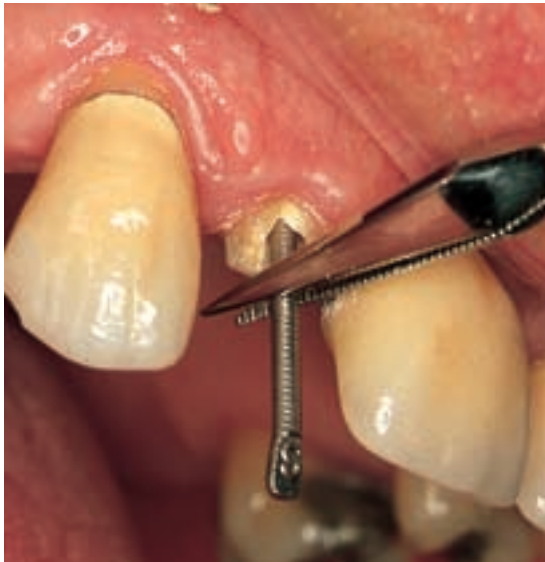GP and most sealers are softer than dentine, and so the bur will tend to follow the root filling rather than cut into the side of the root canal, but nevertheless great care must be taken to ensure that the bur stays on course. Regular inspection of the root canal using both the mouth mirror and direct vision is essential (Figure 6.13). Magnification will also help.





**Figure 6.13**

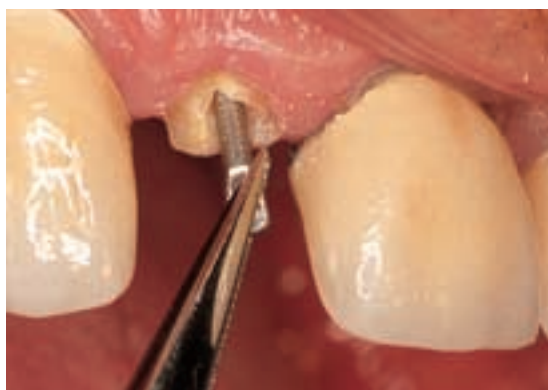*a* A handpiece-driven twist drill to prepare a parallel-sided post hole.



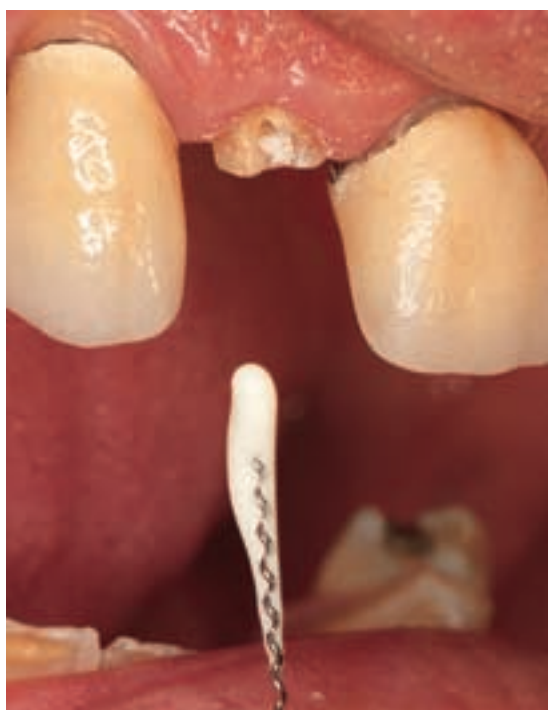*b* The prepared post hole and a preformed stainless-steel post being tried in.



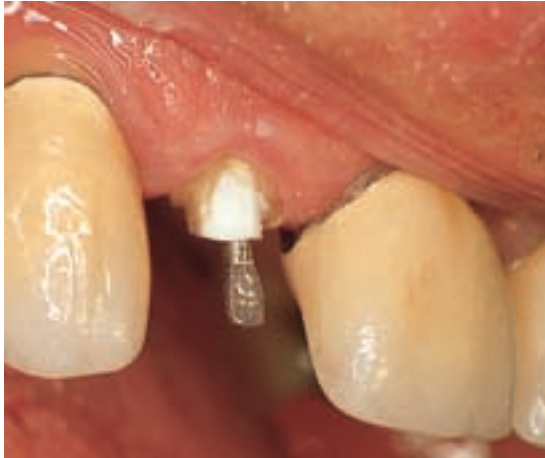c The posthole is 9 mm long.



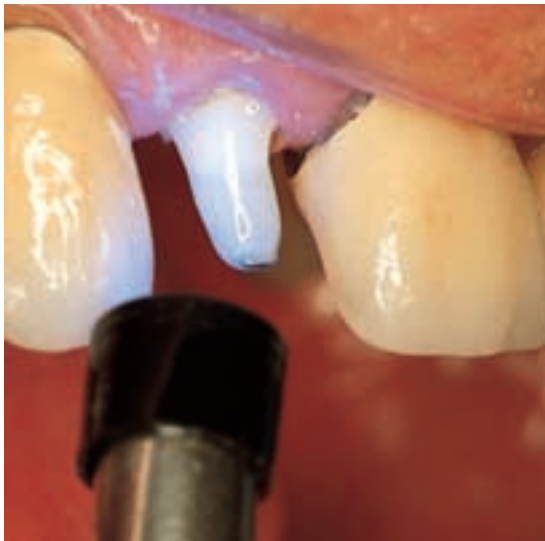d The post is shortened from its apical end to preserve the retentive tag for the core, and is tried in again.



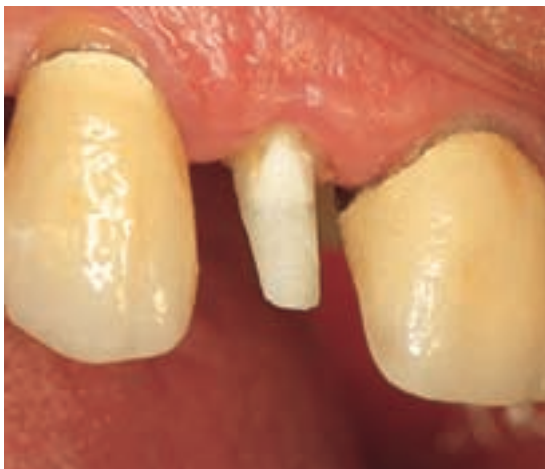e Glass ionomer luting cement is spun down the post hole with a rotary paste filler.



f The post cemented with glass ionomer cement.



g Light-cured composite is built up freehand.



h The completed core.

At deeper levels in the root it is wise to switch to a Gates-Glidden bur which has a blunt tip, reducing the risk of the bur going out of the long axis of the root canal. This is followed by the appropriate diameter twist drill to match the preformed post.

Whichever instrument is chosen it must be used at slow speed and removed frequently so that the end of the hole can be inspected to ensure that it is centred on the root filling. The air turbine should never be used to remove GP root fillings.

Some cement fillings are more difficult to remove than GP because they set to a consistency harder than dentine so that the bur tends to slip away from the root filling into the dentine. In this case the coronal end of the root filling can be removed with a long tapered bur in the air turbine, but great care is needed to avoid lateral perforation of the root.

It is almost impossible to cut down full-length silver point root fillings, and these should be removed intact, if possible, and replaced by GP root fillings. When the silver point cannot be removed, an alternative form of core should be used.

### Shaping the post hole

The post hole needs to be shaped to match the post selected (the different types of post were described in Chapter 2). When the post is to be parallel-sided, a twist drill may be used from the outset, and the root filling is removed and the post hole shaped in a single operation. In some cases, once the root filling is removed, it may be decided that a larger diameter post is needed, and so the next size of twist drill is then used to shape the post hole. Figure 6.13 shows the stages in preparing a parallel-sided post hole and making the post and core.

For a tapered post hole for a cast metal post, an instrument such as that shown in Figure 6.12b is used. This not only produces the taper but may also be moved side to side to produce an oval-shaped canal, following the shape of the tooth. This increases the strength of the post while leaving a uniform thickness of root (Figure 6.14). A selection of instruments, and sections of the teeth prepared using them, are illustrated in Figure 6.15.

### Finishing the preparation

Once the margin, the remaining axial walls and the post hole have been prepared, there may remain a substantial collar of dentine, some spurs or none at all. Substantial amounts of dentine should be left, since they lengthen the post hole and define the margins. Fragile fragments, however, should be removed.

Completed post crown preparations with posts and cores in place are shown in Figure 3.19 (page 74).

### Temporary crowns

For a description of the difference between 'temporary' and 'provisional' crowns and bridges, see page 155. Temporary crowns are described at this stage because in a normal clinical sequence, once a crown preparation has been started, it must be completed at least in terms of gross reduction at the same visit and a temporary crown fitted. Often it will be possible to proceed to impressions and other stages at the same visit, but these can be deferred if necessary. The temporary crown, however, cannot be deferred.

### Preformed temporary crowns

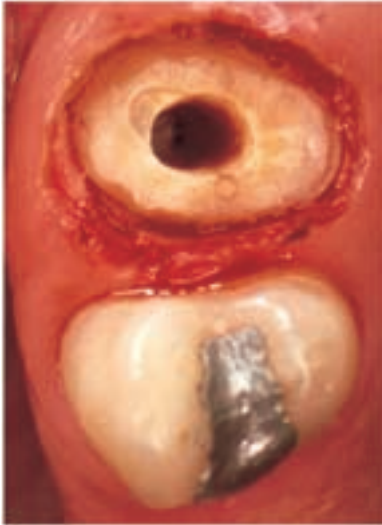#### Polycarbonate temporary crowns

The appropriate size of a temporary crown has already been selected during the planning stage, and Figure 6.16 shows the stages in preparing and modifying a polycarbonate crown for an upper canine tooth. The crown is relined with a temporary crown resin.

Once the polycarbonate crown has been relined, it can be adjusted for incisal length, occlusion and marginal fit. It does not matter if the polycarbonate is ground right through, as long as a layer of the lining material remains.

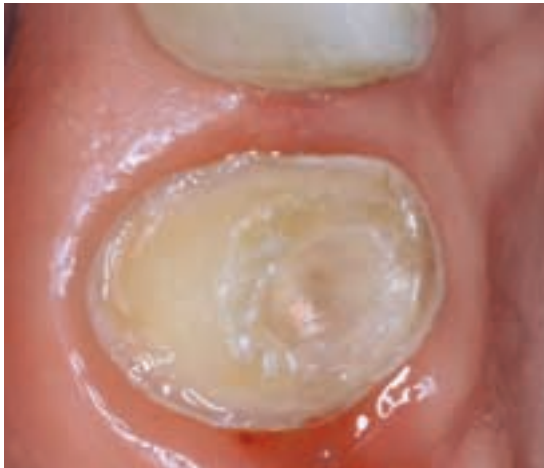#### Stainless-steel temporary crowns

These are difficult to adapt and often do not produce good contact points or occlusal contact.

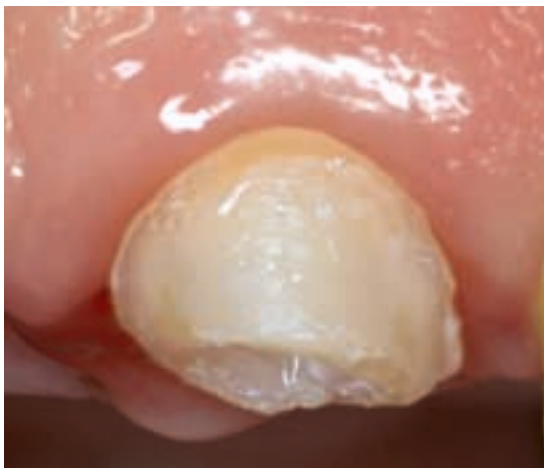

**Figure 6.14**

*a* Looking up the post hole with direct vision. Note that the oval shape of this post hole will resist rotation of the post within the hole. Note too that the crown margin has been exposed using electrosurgery. This was necessary here because of caries beneath the previous crown. An 'anti-rotation' notch has also been prepared. The idea was that this prevented the post losing retention by rotating in the post hole. However, clinical evidence suggests that these notches are more likely to be the starting point of a longitudinal root fracture. Therefore they should not be used.



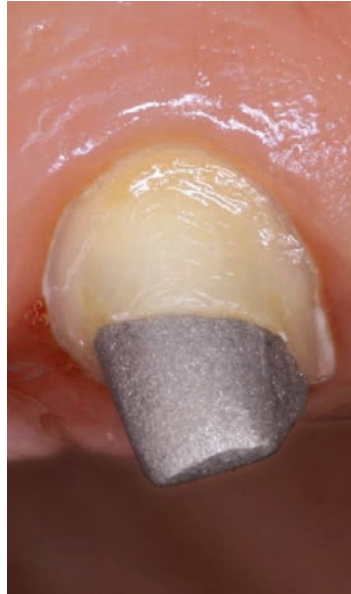*b* and *c* A tooth prepared for a cast post, retaining as much coronal dentine as possible. The remaining gutta percha can be seen at the base of the post hole.





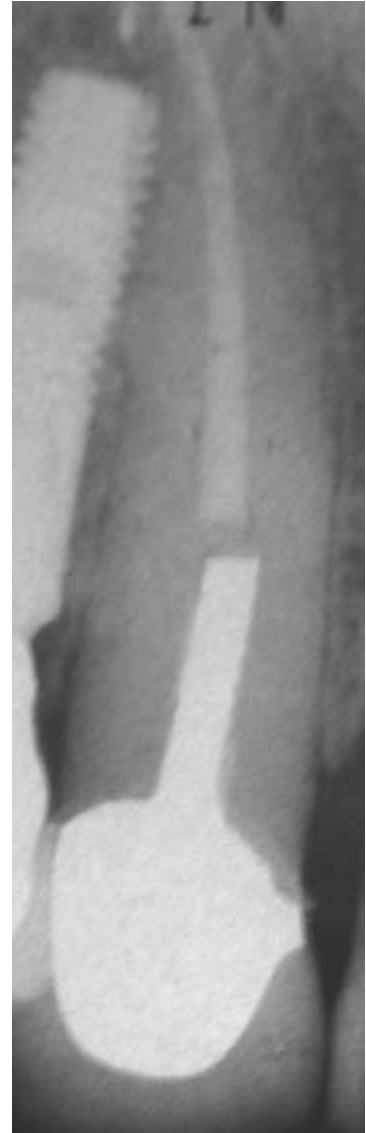*d*

*d* The completed cast post and core which has been made with a burn out plastic post for the apical two-thirds, producing a parallel-sided post with serrations for increased retention. The coronal part is irregular in shape to fit the shape of the root canal. The core supplements the remaining dentine to provide adequate retention for the crown. The post is 12 mm in length.

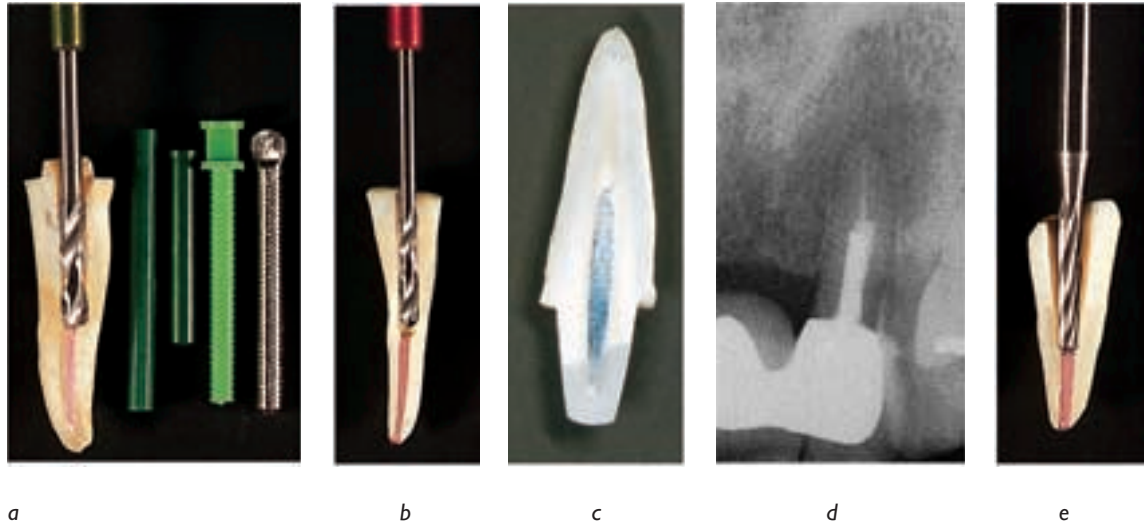


*e*

*e* and *f* The post and core cemented. A radiograph shows the post to be centred in the root canal and extends about half way down the root as this is a long rooted tooth. In a shorter root the post may extend up to two-thirds of the root.



*f*



**Figure 6.15**

*a* A sectioned, extracted tooth showing the preparation for a parallel-sided post hole. The system being used is the same as that shown in Figure 2.5b. This is a 1.75 mm diameter drill. It is rather too big for this size of tooth and is veering towards the side. Ideally the post hole should be longer but, if continued in this direction, there would be a risk of lateral perforation of the root.

*b* This tooth is thinner and the drill is 1.25 mm diameter; however, it is progressing down the centre of the tooth with less risk of lateral perforation.

*c* A sectioned, extracted tooth with a stainless-steel post and composite core in place. The composite core is about half the preparation. (The stainless-steel post is parallel and longer but part of it and the root filling and have been lost in the sectioning process.)

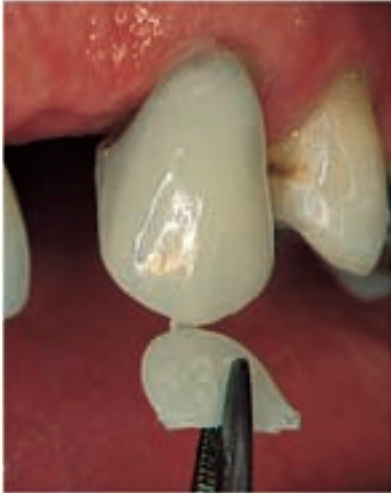*d* A radiograph of a post in a root-filled upper lateral incisor tooth. The tooth is an abutment for a bridge and the bridge had been present for many years. The length and diameter of the post are suitable for this size and shape of root.

*e* A tapered post hole cutter with good side-cutting ability. It has been tilted back and forth to produce a tapered post which is larger at the neck than the diameter of the bur. This is often necessary when caries has progressed down the root canal or when a previous post was present. An impression and cast post will be necessary. As this preparation inevitably weakens the tooth, the root face has been prepared with an external bevel so that a complete diaphragm can be cast together with the post and core.

*f* A parallel-sided post with a very fine self-tapping thread. *Top*: the post. *Centre*: the wrench which locks onto the head of the post so that it can be screwed in and then the wrench released. *Bottom*: the matching twist drill.

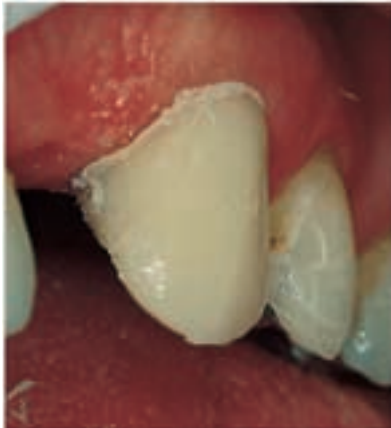

*f*

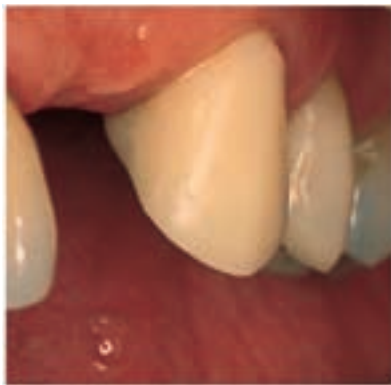

**Figure 6.16**

Polycarbonate temporary crowns.  
*a* Temporary crown being tried in.

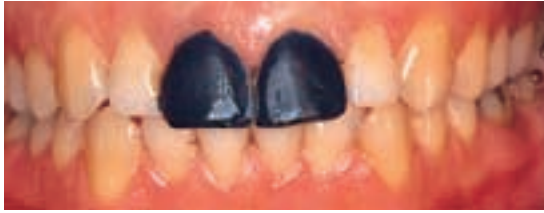

*b* Trimmed and relined with a temporary crown and bridge material.



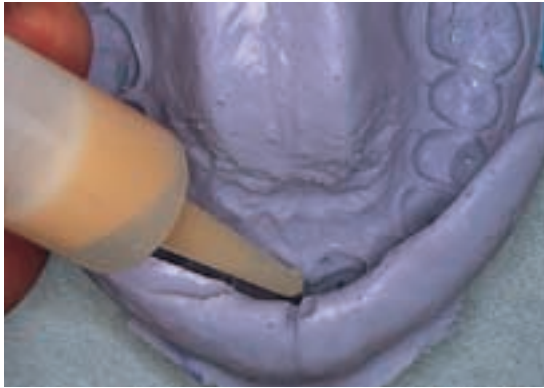
*c* The temporary crown 2 weeks later.



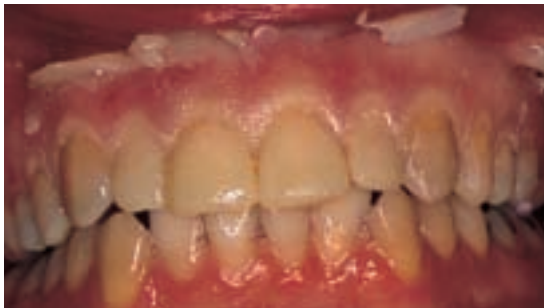**Figure 6.17**

Chair-side temporary crowns: injection techniques.

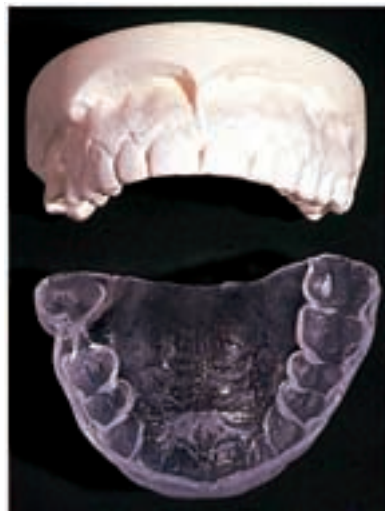*a* The patient shown in Figure 6.10; the buccal surfaces of the central incisors are reshaped with wax in the mouth.



*b* A temporary crown and bridge material being injected into an alginate impression of the modified teeth.



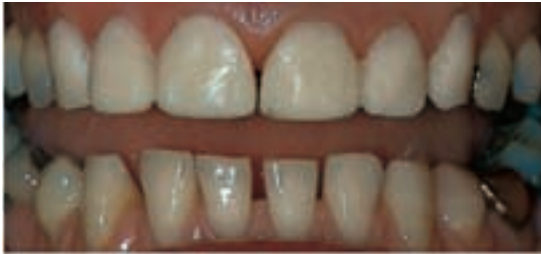*c* The temporary crowns before being removed from the mouth. Note the thin flash which is easy to trim, leaving a good marginal fit.



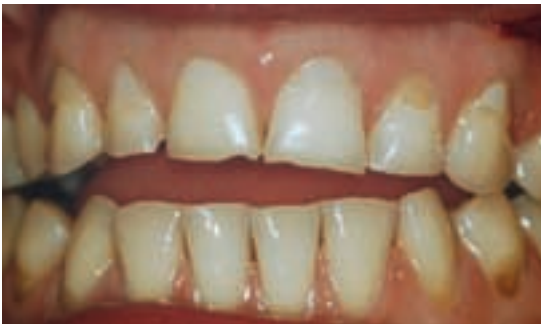*d* Flexible PVC slip vacuum-formed to the study cast for a different patient.



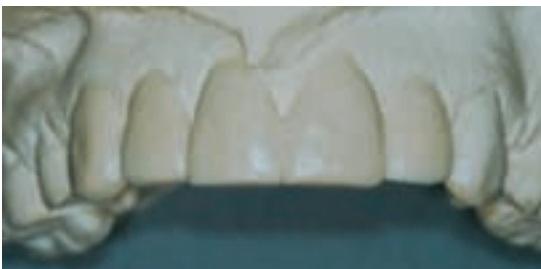e The partly set material (in this case a different material) is removed from the mouth still in the mould.



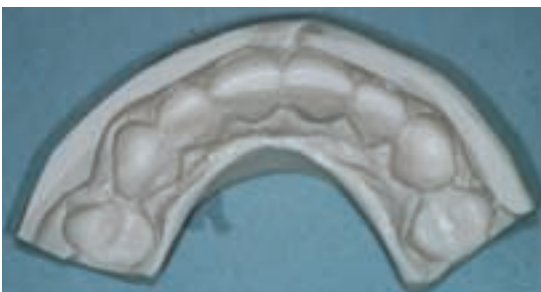
f The completed temporary crowns for the second patient.

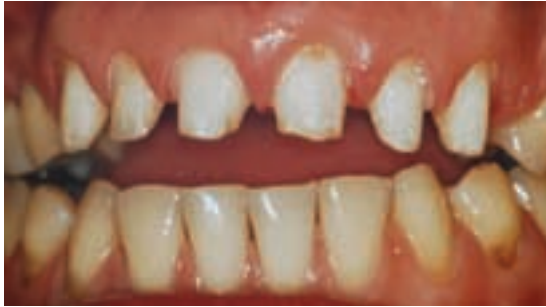

g This patient has lost extensive amounts of enamel and dentine following many years of gastric reflux. To improve the appearance ceramic crowns are to be provided.

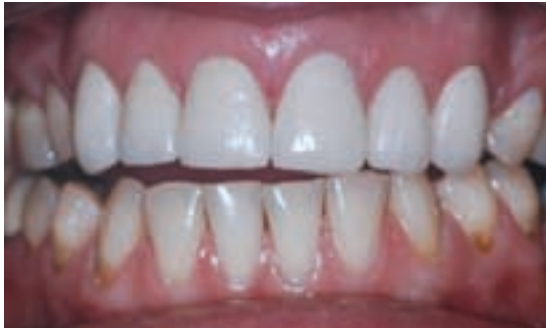
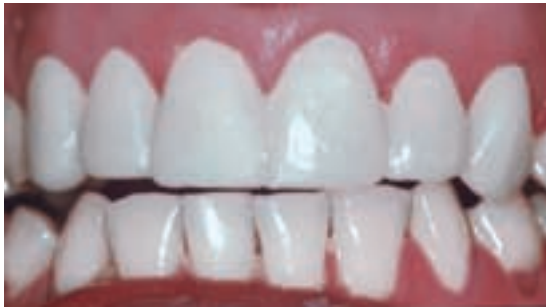
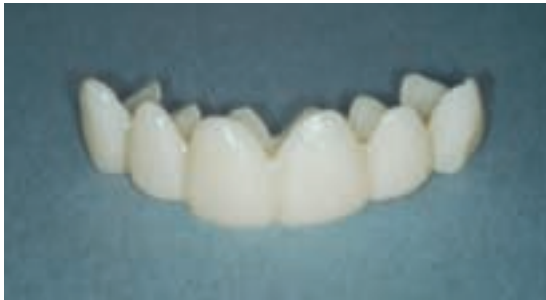h and i A diagnostic wax-up has been made to show the patient the proposed end result and a silicone putty matrix made for the temporary crowns.

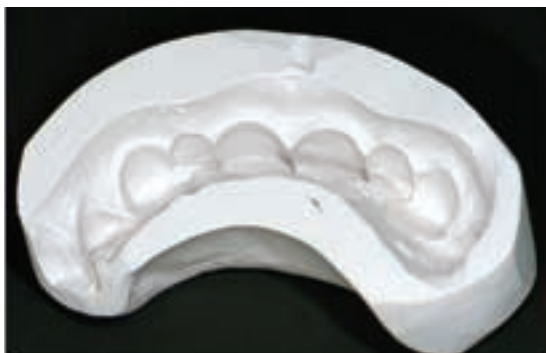




*j, k and l* Following preparation of the teeth the putty matrix is used to make chair-side temporary crowns which are the same shape as the diagnostic wax-up. Temporary crown material is syringed into the matrix and placed over the preparations. It is important that the margins are trimmed to a good fit. The temporary restorations are in one piece for strength.



*m* The completed Procera porcelain crowns.



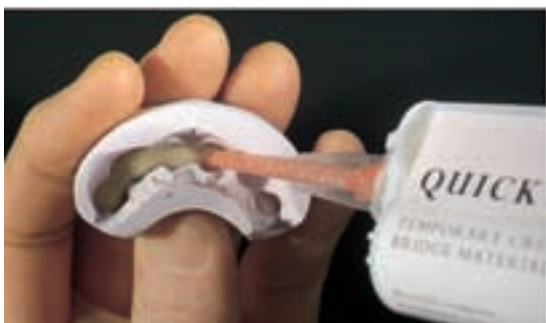**Figure 6.18**

*a-d* A similar technique to Figure 6.17 using a mould produced in a laboratory silicone putty material and temporary crown and bridge material mixed in an automix gun and injected directly into the impression.

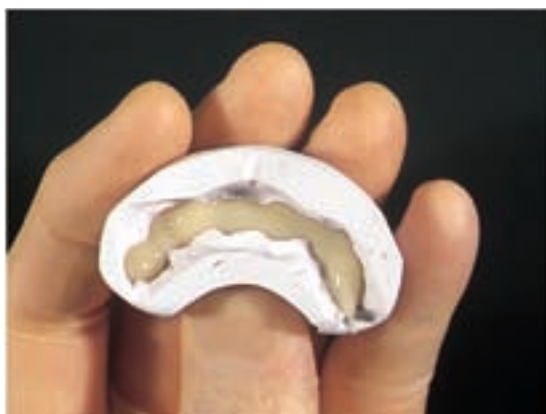*a* The silicone mould made on a study cast modified with wax.



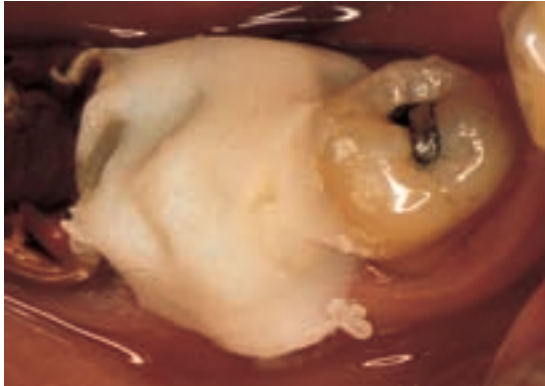
*b* The automix gun with a very fine nozzle.



*c* Inserting the material.



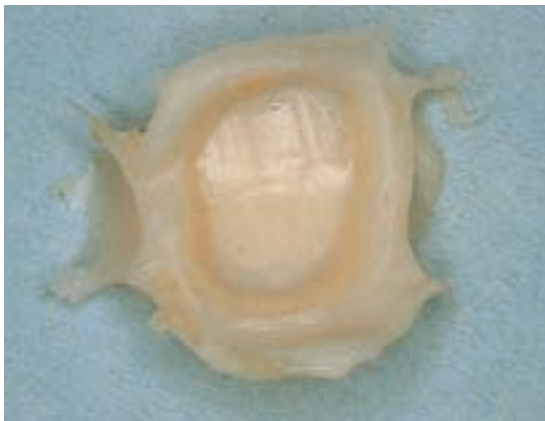
*d* Ready to be placed in the mouth.



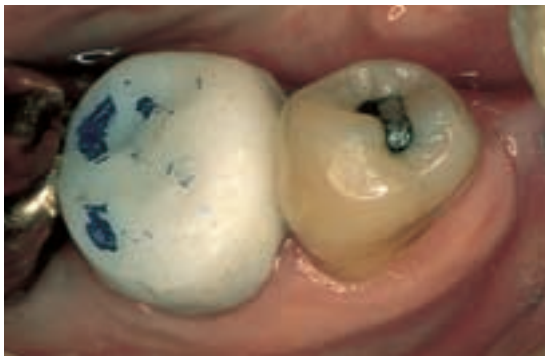**Figure 6.19**

Chair-side temporary crowns: moulding technique.

*a* A temporary crown and bridge higher acrylic mixed to a dough consistency is moulded over the prepared tooth and the patient is asked to occlude into it.



*b* When nearly set it is eased off the preparation and out of the undercuts between adjacent teeth. In this case the fit surface was satisfactory; in others it may need to be relined with a further mix of material after the exterior surface has been trimmed.



*c* The temporary crown trimmed to a good fit at the margins. Articulating paper is being used to adjust the occlusion.

They are, however, hard and durable and can be left in place for some time. The margins are trimmed with stones and contoured with pliers, and the temporary crown is then cemented, usually with a rigid cement such as zinc phosphate or a reinforced zinc oxide eugenol cement.

### Aluminium crown forms

Being softer, these are more readily adapted to fit contact points and occlusal contacts, but the margins are irritant to the soft tissues and are difficult to clean so that the gingival margin

becomes inflamed making impressions difficult. Also some patients complain of a metallic taste. Although they are quick to make, they are less satisfactory than adjustable chair-side plastic or relined polycarbonate temporary posterior crowns. Aluminium and stainless-steel temporary crowns are sometimes preferred when minimal tooth preparations have been carried out for metal crowns and temporary crowns made from acrylic would be too thin to last.

### **Chair-side techniques for making temporary crowns**

#### **Injection or pouring techniques**

This is the temporary restoration of choice as it is made specifically for the prepared tooth. It produces a more accurate fit than pre-formed crowns. Modern materials are strong in thin section and can be added to with composite, they have a good appearance and a fast setting time. The mould used may be a preformed celluloid crown form, a thin PVC slip vacuum formed on the patient's study cast (or a modified study cast), or a silicone putty or an impression taken prior to starting the preparation. Figure 6.17 illustrates typical techniques using an alginate impression and a PVC slip with two different higher acrylics. Figure 6.18 shows a similar technique with a putty impression of a modified study cast and a higher acrylic in an automix gun.

#### **Moulding techniques**

Some of the higher acrylics go through a dough stage when they can be moulded rather like putty. In this consistency they can be formed into temporary crowns simply by moulding over the prepared tooth with the fingers and the patient biting into it to establish the occlusion. Gross excesses will be present, but these can be removed by rough carving in the mouth and then with an acrylic bur in a straight handpiece once the crown has been removed and has become hard (Figure 6.19). This is a useful technique, particularly for posterior teeth where the shape of the tooth to be prepared (often a core) is to be changed and so is not suitable for copying in a chair-side impression.

A temporary crown made by this moulding technique will have better contact points, occlusal contact and marginal adaptation than an aluminium crown form. There is no need to modify the study model or make a vacuum-formed PVC slip and so it is an effective and efficient technique.

However the temporary crowns are made it is important that they should not be overbuilt at the margins so they will not interfere with oral hygiene. The temporary crown needs to have a good contact point with the adjacent teeth and the occluding surface needs to be adjusted to maintain contact with the opposing tooth.

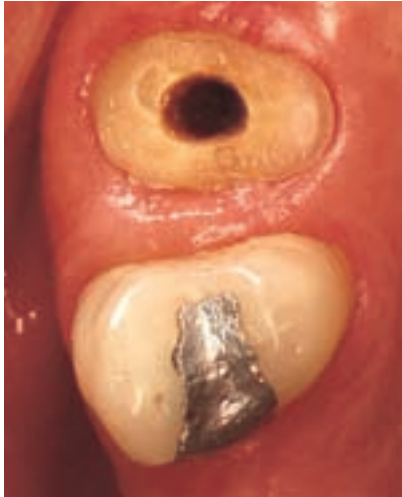#### **Temporary post crown techniques**

Some manufacturers supply temporary posts with their kits. An example of an aluminium temporary post is shown in Figure 6.15. For tapered post holes, temporary posts may be made from wire modified with acrylic before the temporary crown is added to the wire by one of the techniques described in the previous section (Figure 6.20).

### **Differences between temporary and provisional crowns**

It is useful to make a distinction between 'temporary' and 'provisional' crowns (and bridges). Temporary restorations are made to last for a short while to protect the prepared dentine, to maintain the appearance, and to prevent tilting or over-eruption of the prepared tooth by maintaining contact points and occlusion. Because they are temporary, they are usually made by one of the relatively simple chair-side techniques described above and are cemented with a temporary crown and bridge cement.

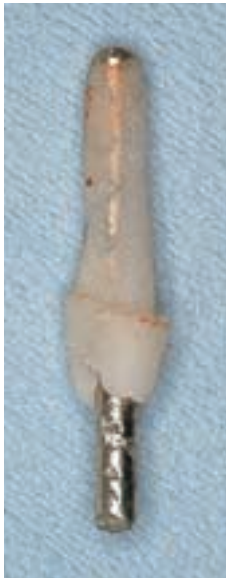Provisional restorations also have all these functions, but are made to last for a longer period while other treatment is being provided before the permanent restorations can be made or when a period of assessment is necessary. For example, if the patient has periodontal disease associated with poor margins on existing restorations, provisional restorations may be made with well-adapted margins and left for some time until the



**Figure 6.20**

Temporary-post crowns.

*a* The same preparation as shown in Figure 6.14a after initial gingival healing.



*b* The thickest possible length of serrated German silver wire is tried in the root canal, coated with a higher acrylic and inserted into the post hole. When nearly set it is withdrawn and reinserted a number of times to prevent the possibility of the post jamming and not coming out. After excess material has been trimmed, the coronal part of the temporary crown is added using one of the techniques described earlier. In this case the polycarbonate temporary crown is illustrated in Figure 6.16.

treatment of the periodontal disease is completed. Similarly, when the occlusion is being modified, for example by increasing the OVD, provisional restorations will be left in place for some months to assess the patient's tolerance of this change before the new occlusion is finally established by permanent restorations. During this time, the occlusion can be modified by

occlusal adjustment or by additions to the restorations.

Long-term provisional restorations are also used when significant changes are being made to anterior teeth. They allow for a period of accommodation to the change to assess the response to appearance, function and speech. The provisional restorations can be altered by addition or

grinding until the patient is happy with the result and then a copy model made to help the laboratory with the appearance of the final crown.

### **Laboratory-made provisional restorations**

Many of the temporary crown and bridge materials are capable of lasting in the mouth long enough to function as provisional restorations. They can therefore be made at the chair side by the same techniques as have been described for temporary restorations.

Alternatively, the teeth are prepared, an accurate impression is taken and temporary restorations are made at the chair side. The impression is then used to make provisional restorations in the laboratory, or sometimes a simple casting is made to which acrylic or composite is added (Figure 11.8). The expense of these is seldom justified for individual crowns, particularly as reinforced composite techniques are now available which produce very satisfactory and less expensive long-term provisional restorations but metal/composite provisional bridges may be needed for long span bridges.

### **Cementation of temporary and provisional crowns**

The retention of the temporary or provisional restoration and the likely dislodging forces should be assessed and a cement of appropriate strength selected. The following list of temporary cements and their appropriate use is arranged in ascending order of strength:

- A non-setting mixture of petroleum jelly and zinc oxide powder – used for short periods between appointments, for example, for cementing temporary crowns when teeth are prepared and impressions taken in the morning and laboratory-processed provisional crowns fitted with a stronger cement in the afternoon.
- Temporary crown and bridge cement with a high proportion of modifier to reduce the strength – used when several temporary crowns are joined together, giving considerable

overall retention; this may be done even though the permanent crowns will be separate (Figure 6.17).

- Unmodified temporary crown and bridge cement – used for individual complete crowns that will have to stay in place for periods of up to 2–3 weeks. Most materials contain eugenol which will be obtundent to the tooth following preparation. If adhesive bonding techniques are to be used for the final crown a non-eugenol cement should be used.
- Polycarboxylate and zinc phosphate cements – used with poorly fitting temporary crowns, for example aluminium temporary crowns, or where the temporary crown has to last for an extended period, for example laboratory-made provisional crowns fitted for periods of orthodontic or periodontal treatment.

After temporary crowns have been cemented, it is important that surplus cement is removed, otherwise irritation of the gingival margin and plaque retention will produce gingival inflammation.

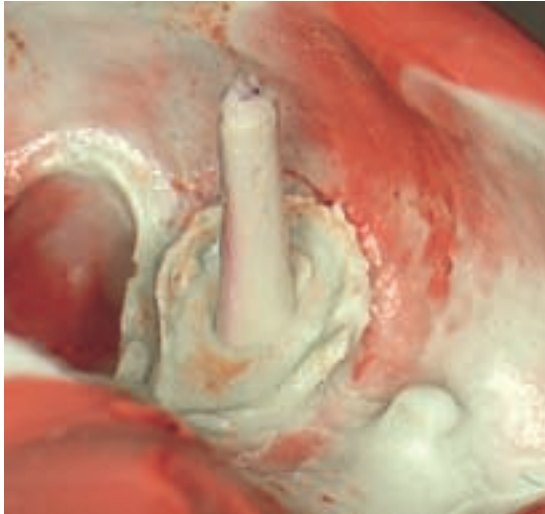
### **The working impression**

The working impression is the very accurate impression from which a cast with removable dies is made. The crown is made on the removable die of the prepared tooth. The impression should include not only an accurate impression of the prepared tooth but also the adjacent teeth so that the contact points and occlusal surfaces of the crown may be contoured. It should also include the remaining teeth in the arch so that the working cast can be articulated against the opposing cast. This usually means that it should be a full arch impression.

### **Impression materials (Figure 6.21)**

There are two groups of materials used for crown and bridge impressions: elastomeric materials (silicone or polyether (Figure 6.21a, b and c)) and reversible hydrocolloid (Figure 6.21d). The elastomeric materials set by a chemical reaction when two materials, usually two pastes,





**Figure 6.21**

Impressions for crowns and bridges in various materials.

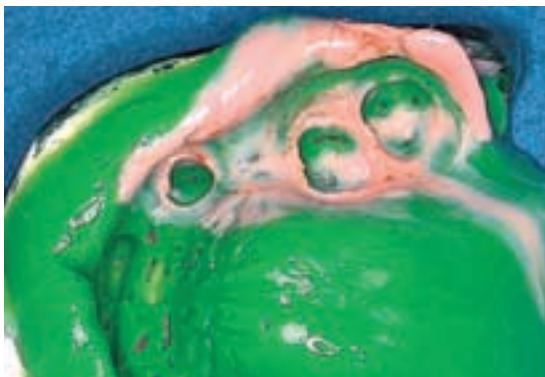
*a* The impression of the patient shown in Figure 6.20 in addition-curing silicone: light- and heavy-body technique. For the impression of the post, the light-body material is spun down the post hole with a spiral root canal paste filler. This is rotated during removal. A thin reinforcing wire is inserted to stiffen the impression and prevent it bending when the die is cast.



*b* A different brand of addition-curing silicone showing the impressions for the patient in Figure 6.10.



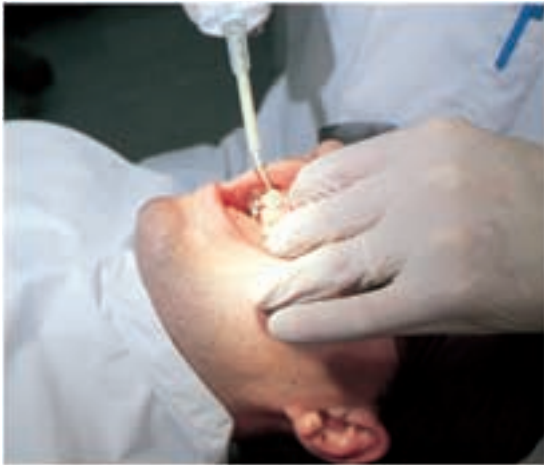*c* An impression in polyether in a stock tray.



*d* Reversible hydrocolloid in a water-cooled tray.



e An automix gun with a standard nozzle adapted with a fine curved tip for direct use in the mouth.



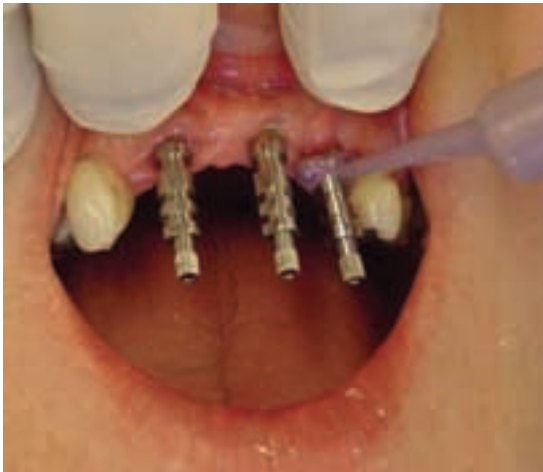f The automix gun being used in the mouth.



g A mixing machine for polyether impression material.



*h* Material being delivered directly into a stock tray.



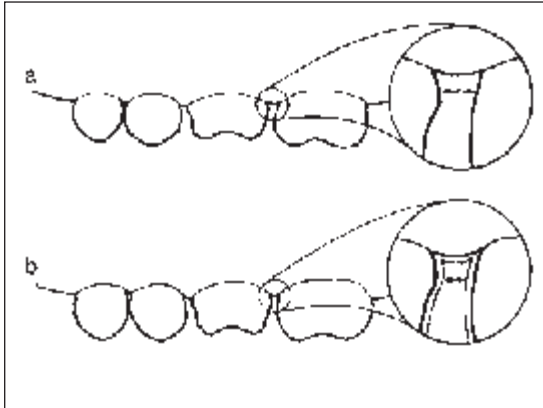
*i* A disposable plastic syringe being used to place impression material.

are mixed together. The reversible hydrocolloid is based on agar. It is melted in a water bath and sets on cooling. The teeth must be dry for elastomeric impressions, but may be wet with reversible hydrocolloid.

Elastomeric materials are very accurate and can usually be re-poured if necessary. They are convenient to use and so have almost entirely replaced the reversible hydrocolloids.

### **Silicone impression materials**

Most manufacturers supply addition-curing silicones in a range of viscosities including putty, heavy-body, regular, light-body and wash. This means that a whole range of techniques is possible using combinations of these materials with or without special trays. Light-body material is usually inserted onto the preparation from an

**Figure 6.22**

Elastomeric impressions should not be relined with a further mix of material once they are set unless all the undercut areas are cut away.

*a* A preliminary impression taken without a spacer.

*b* If this impression is relined with a second mix of material, distortion will occur: the second layer of material in the undercut areas of the unprepared teeth will distort the original material while it is in the mouth. When the impression is removed this will return to its original shape, distorting the impression of the prepared tooth. For a two-stage technique, a spacer of polythene or similar material should be used. Alternatively the primary impression should be cut back with a scalpel or burs, and in particular all the interdental areas and impression of any undercut surfaces removed.

automix gun or syringe (Figure 6.21e, f and i) and the medium or heavy-body either mixed in a second gun or on a pad and placed in the tray. Putty is kneaded by hand.

The automix gun used with an extra fine nozzle has several advantages in placing the light-body material directly around the preparations (Figure 6.21f and g). The material is thoroughly mixed without air bubbles, and the mix is very fresh when it is applied to the tooth preparations. With light- and heavy-body materials mixed on pads, the dental nurse usually mixes one material and the dentist the other. Timing of the two mixes, loading the syringe and then drying and isolating the preparations requires very good coordination, and the mixed, light-body material may start to set before it is properly in place. With the automix system the dentist maintains the prepared teeth in a dry and isolated state and starts to inject the light-body material at the point where the nurse is loading the tray. However, some operators find that the automix gun is too large and clumsy and they prefer to use a smaller disposable syringe (Figure 6.21i).

Silicone does not wet tooth preparations well. In compensation, it is very clean to use. Toxic and allergic reactions have not been reported.

Hydrophilic impression materials are available which are not so susceptible to the presence of moisture.

### **Polyether impression material**

Polyether is convenient since the same material may be used in the syringe and the tray, only one mix being required, although light and heavy viscosities are also available. It is also best used in thick sections, and so should be used in stock trays; or if a special tray is used, it should be made with extra thick space between the study cast and the tray.

An automatic mixing machine is available for polyether (Figure 6.21g and h).

### **Reversible hydrocolloid**

This was available long before the elastomeric materials were developed, and it largely fell into disuse with their introduction. However, there have been sporadic revivals of interest in it. It has the advantage of being usable in a wet environment.

## Impression techniques

### Single material technique (e.g. polyether)

When a single viscosity material is used, the material is mixed, and part of it placed in an impression syringe and the remainder in the impression tray, usually a stock tray. The material is syringed over the dry tooth preparation and the tray is immediately seated in place. With a stock tray that has no occlusal stops, it is important to localize the tray carefully and avoid seating it too far so that it does not contact the prepared tooth.

### Two viscosity material technique (e.g. light- and heavy-body silicone)

Two sets of material are mixed: a low viscosity material that is syringed around the preparations, and a heavier viscosity material used in the impression tray and seated in the mouth before the light-body material has set. The light-body material is thus forced into intimate contact with the preparation and gingival crevice.

A special tray with occlusal stops is preferably used with the elastomeric materials.

### Putty and wash (e.g. silicone)

This is a modification of the two viscosity technique with a low or medium viscosity material used in the automix gun and a putty material in the tray. Because of the viscosity of the putty material a large amount is needed and so a stock tray is usually used. This technique is therefore popular because the cost of a special tray is saved, but it is difficult to achieve results of the same quality as other techniques because the pressure needed to seat the tray can distort it (Figure 6.22).

## Polymer materials and gloves

One disadvantage of putty materials is that some of the gloves worn by dentists react with the material and prevent it setting. It is therefore often necessary for the dentist or nurse who will

be mixing the putty material to remove their gloves and wash their hands before mixing it. The most convenient method is to use one of the polymer materials available in an automix gun.

## Gingival retraction

It is essential that the impression has a clear record of the entire preparation margin and just into the crevice beyond the margin so that the die can be accurately trimmed and the technician can see the exact extent of the margin.

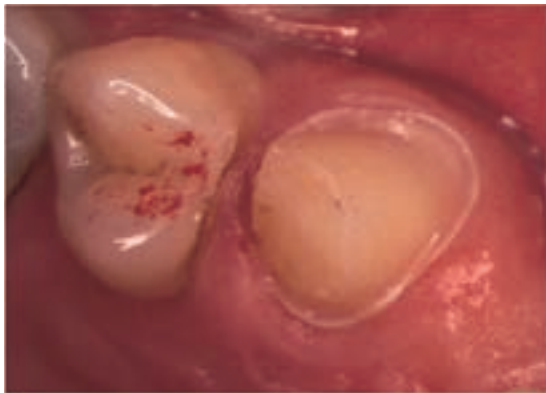
The ideal is to start with gingival health and supragingival crown margins. Gingival retraction is not then needed, impression taking is easier and more reliable, but most importantly, gingival health is easy for the patient to maintain. However, it is often necessary to retract the gingival tissues in order to obtain an impression of the tooth surface beneath the gingival margin. This will always be necessary if the preparation margin is subgingival. It will also be desirable if it is close to or at the gingival margin. This is because the crown contour at the periphery should be in line with the tooth surface to avoid a plaque-retentive crevice at the margin. This can only be achieved if an impression of the tooth surface is obtained for some distance beyond the preparation margin.

There are five ways of retracting the gingival margins (in ascending order of potential damage):

- Blowing the impression material into the gingival crevice with vigorous blasts of air.
- Syringing kaolin-based materials into the crevice prior to taking the impression. These absorb moisture and cause retraction of the gingiva.
- Temporarily retracting the gingival margin with cord.
- Using cords impregnated with chemicals.
- Electrosurgery.

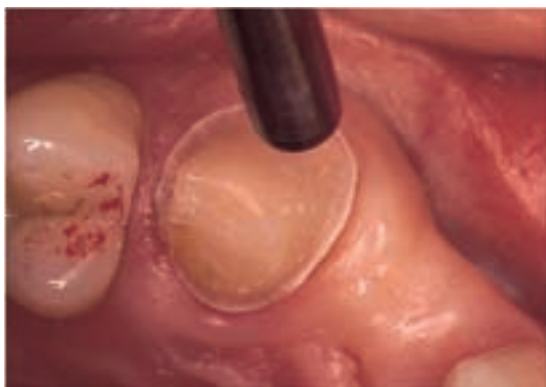### Compressed air (Figure 6.23a and b)

With a healthy gingival margin undamaged by the preparation it is often sufficient to blow the impression material into the crevice with air. This technique works best with light-body and wash

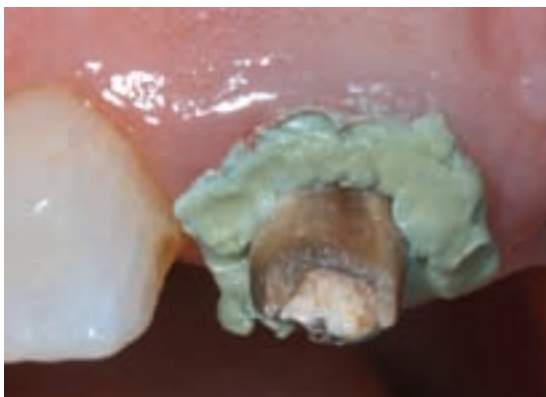**Figure 6.23**

Gingival retraction.

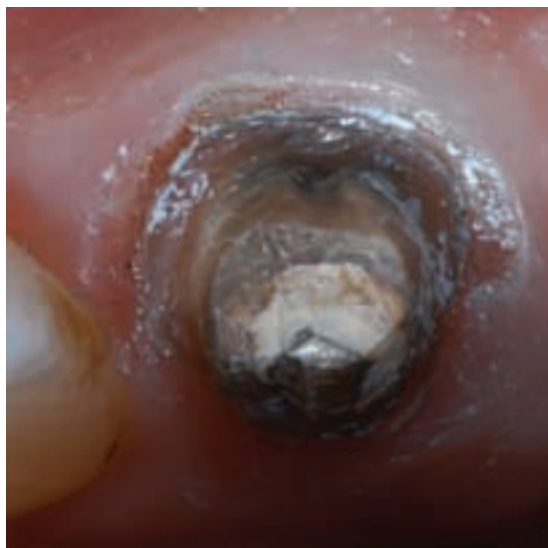*a* A crown preparation with the mesial margin level with the gingival margin.



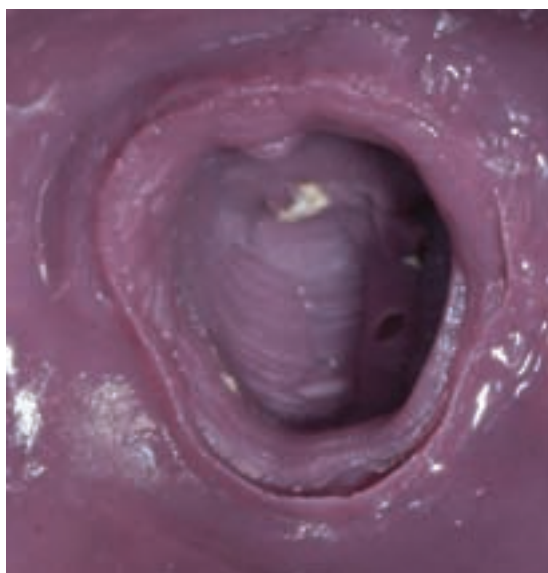
*b* The mesial-gingival margin being retracted solely by blowing air into the gingival crevice. With light-bodied elastomeric impression materials this is often all the retraction that is needed.



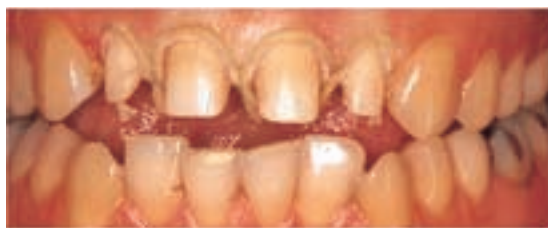*c* A kaolin-based gingival retraction paste is syringed around a prepared tooth.



*d* Following thorough washing of the preparation the gingival tissue is not bleeding and has retracted a little from the tooth, allowing access for impression material. This will not be adequate for deep preparations.



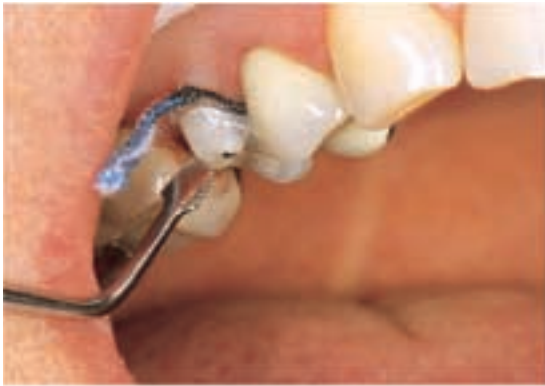*e* A clear impression has resulted.



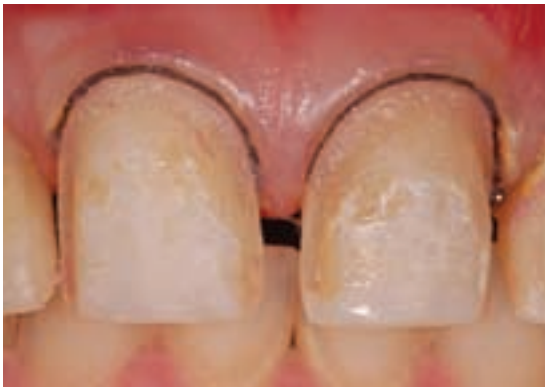*f* Gingival retraction with adrenaline-impregnated braided cord. These are the preparations shown in Figure 6.10f. The palatal margins are supragingival, and gingival retraction is only necessary on the labial and proximal surfaces.



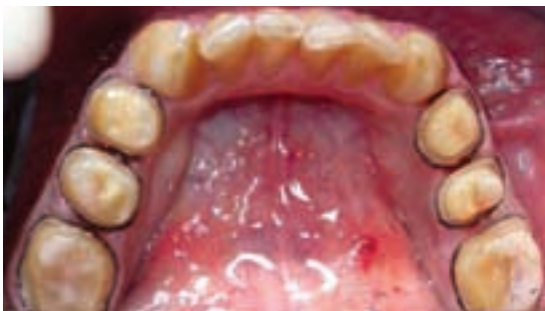*g* An instrument designed to insert gingival retraction cord.



*h* The instrument in use.



*i* Double cord for an impression for veneers. The gingival tissue has retracted and it is time to pull out the top cord.



*j* Double cord retraction for multiple preparations.



silicones and with polyether. The viscosity and wetting ability of the material are critical.

### **Kaolin pastes** (Figure 6.23c, d and e)

Minor degrees of gingival bleeding or access to margins only just subgingival can be made clear and accessible by syringing the paste into the crevice and leaving it undisturbed for 4–5 minutes. The kaolin absorbs any fluid and so expands pushing back the gingiva. After washing out the paste, the crevice is opened for the impression material.

### **Cord and impregnated cord** (Figure 6.23d)

If cord is to be used, it is usually impregnated either with adrenaline, which acts as a vasoconstrictor assisting in gingival retraction and in arresting any minor gingival haemorrhage, or with an astringent material such as aluminium trichloride, which functions in a similar way. However, some operators prefer plain unimpregnated cord.

Cords are available in various thicknesses, both twisted and braided. Braided cords are preferred since they do not unravel while they are being inserted and newer cords have fine copper wire within them to keep their shape and stay put in the crevice.

A cord of appropriate diameter is pressed lightly into the gingival crevice with a suitable instrument, for example a flat plastic type or one of the special instruments designed for the purpose (Figure 6.23g and h). It may not be necessary to retract the gum all the way round the tooth if part of the preparation margin is sufficiently supragingival. The cord is left in place for 2 or 3 minutes and then removed before the impression is taken. If it is left for too short a time, gingival retraction is inadequate; if it is left for too long, the chemicals diffuse and become inactive. Too much force should not be used, or permanent damage to the gingival tissues may result.

Another technique is to use a very thin cord pressed into the base of the gingival crevice and a thicker cord placed on top of it. Usually only the thick cord is removed before the impression is taken (Figure 6.23i and j).

### **Electrosurgery** (Figures 6.14a and 6.20a)

Electrosurgery can be used to arrest gingival haemorrhage before impression taking and to establish a distinct gingival crevice, exposing a subgingival preparation margin. This technique should be reserved for unusual situations, for example where a tooth has been fractured with the fracture line extending subgingivally and an impression is required in order to make a post, core and diaphragm. Further gingival re-contouring may be carried out surgically once the crown is fitted if necessary.

### **Occlusal records**

An occlusal record is not always necessary (see Chapter 4). In some cases an intercuspal position (ICP) record is all that is required. In others a combination of retruded contact position (RCP) and left, right and protrusive excursion records, together with a facebow, may be needed.

The intra-occlusal records may be taken in a silicone material, wax, or wax and temporary cement.

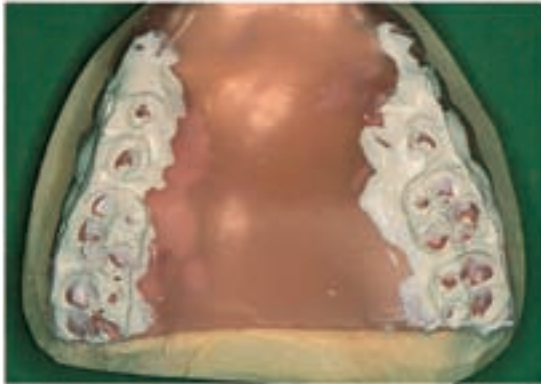### **Silicone occlusal records**

These have become the most popular record because of their accuracy and convenience. These advantages outweigh the additional cost. The materials and techniques were discussed in Chapter 4. The material can be delivered by an automix gun with a shaped nozzle so that a flat, broad band of material is laid directly from the gun over the occlusal surfaces of the lower teeth.

It is important that the record is trimmed, removing most of the buccal and lingual excess and sometimes the interdental areas so that the models can be seen to fit closely into the record (see Chapter 4).

### **Wax occlusal records**

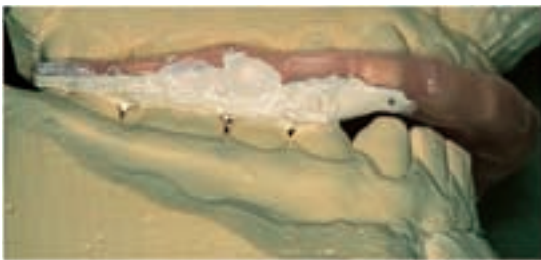Ordinary pink wax can be used, but a better choice is wax made for the purpose which is soft



**Figure 6.24**

Occlusal records.

*a* A full arch wax occlusal record modified by the addition of a rapidly setting temporary crown and bridge cement to the upper and lower surfaces. Note that the wax extends across the palate, supporting the two sides.



*b* Excess cement has been trimmed away from the lower side of the record with a scalpel so that when the casts are seated, very precise location of the lower cast within the record can be seen. Note that this patient has an anterior open bite, making location of the casts without an occlusal record difficult.

just above mouth temperature but becomes much harder when cooled. The wax is softened in a flame or in hot water and shaped to the approximate size of the study cast. It is laid on the lower teeth and the jaw is closed into the required position. The wax is allowed to cool or is chilled with water and then removed.

Wax records are liable to distort and may need to be readapted. This may be done by thorough cooling outside the mouth and relining with a temporary crown and bridge cement (Figure 6.24a and b).

### Removing temporary crowns

At the next appointment the temporary crown needs to be removed from the prepared tooth. With a weak cement this should be easy with gentle pressure applied to the margin with an excavator or similar instrument. Thicker, well

fitting crowns may be better sectioned through rather than risk damaging the margin. It is sometimes possible to carry this out without the need for a local anaesthetic.

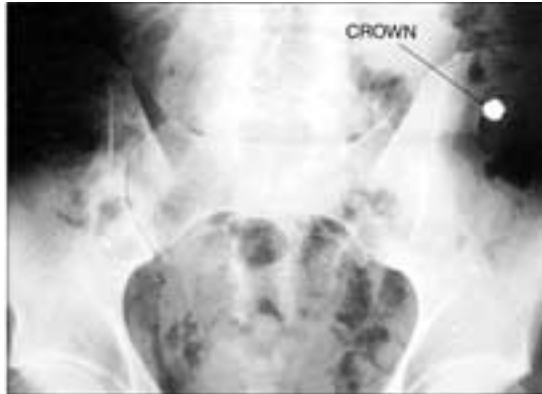Before removing the temporary crown the permanent crown should be inspected on the model to confirm it is as prescribed.

### Trying in the permanent crown

#### Safety precautions

Small slippery objects like crowns tend to slip out of gloved fingers, especially when wet. They are even more prone to slip out of tweezers, which should never be used.

The dangers of dropping a crown down the patient's throat are obvious. If it is inhaled, this is a serious medical emergency and the patient should be rapidly inverted and encouraged to



**Figure 6.25**

A crown that has been swallowed at the try-in stage. It is now at the top of the descending colon, and was passed 24 hours after this radiograph was taken. It was recovered, sterilized and cemented.

cough. If this is not successful, the patient should be immediately taken to hospital for the crown to be removed.

If the crown is swallowed, this is less dangerous – and also less dangerous than swallowing a sharp instrument such as an endodontic file. However, radiographs should usually be taken and if possible the crown recovered by the patient when it is passed to reassure the patient it has passed safely. The patient should be advised to use a sieve and running water to find the crown in the faeces. Figure 6.25 shows an abdominal radiograph with a crown in the colon.

Various precautions are possible:

- With practice and experience it is possible to control even small inlays and crowns by keeping the gloves dry and the tooth well isolated and dry. One finger should be kept behind the crown at all times. A competent dental nurse with a wide-bore high-volume aspirator should be at the ready.
- Gauze or sponge packs may be placed behind the area where the crown is being tried in. These are theoretically a good idea, but with some patients the irritation at the back of the mouth makes them consciously suppress the cough reflex so that if a foreign object drops behind the pack, the risk of it being inhaled rather than swallowed may be increased.
- The patient may have treatment in an upright position and be told to lean forward, if the crown drops, and cough it out.

- In some cases it is advisable to try in crowns under rubber dam, but it is difficult to assess the margins if clamps are used, and impossible to judge the gingival relationship or occlusion.

### **The checking procedure**

As pointed out in Chapter 5, a gold crown is tried in, adjusted if necessary and then cemented.

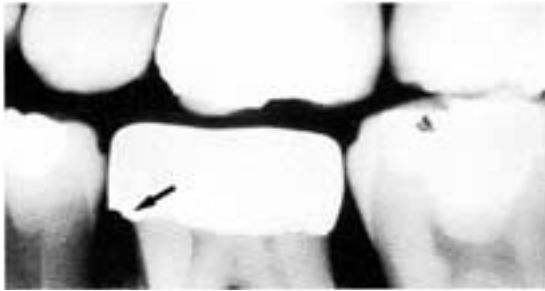
The metal part of a metal–ceramic crown may be tried in before the porcelain is added and then returned to the laboratory and retried with the porcelain before being finally cemented.

At the try-in stage the following checks should be made, together with any necessary adjustments.

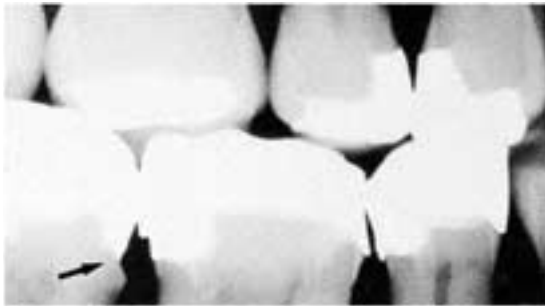### **Checking and adjusting the fit**

The marginal fit is checked by eye and with a sharp probe. Gaps, overhanging margins (positive ledges) and deficiencies (negative ledges) may be present (Figure 6.26).

A uniform gap all the way round indicates that the crown is not fully seated. Having checked for retained temporary cement or trapped gingival tissue, a firmer seating force should be applied, and if the gap persists, the contact points should be checked with dental floss. If, after any necessary adjustment to these, the crown still does not

**Figure 6.26**

*a* A crown with a large positive ledge or overhang. This should not be cemented in this condition. The distal margin is a better fit, but the surface is bulbous and overcontoured, encroaching on the embrasure space. Compare the contour of the distal surface of the crown with the mesial surface of the tooth behind.



*b* A negative ledge or short crown margin. There is no gap. All the other restoration margins on this radiograph are also overhanging or defective in some way.

seat, it should be removed and the fit surface inspected. If it is metal, burnish marks on the axial walls may show where the crown is binding. These are ground lightly with a bur or stone and the crown is retried.

If there is some improvement but not complete seating, the fit surface should be lightly grit-blasted and resealed. If no burnish marks appear, it is likely that the margins or occlusal surface are preventing complete seating. A common cause is a slightly over-trimmed die (Figure 6.27). If the inside of occlusal surface is suspected, disclosing wax (a very soft wax) is melted into the crown, which is seated before the wax sets. When the crown is removed, high spots will show as perforations of the opaque wax.

Fine powder suspensions in aerosol sprays or painted colloidal graphite are also used to show where tight crowns are binding, but they are very untidy materials.

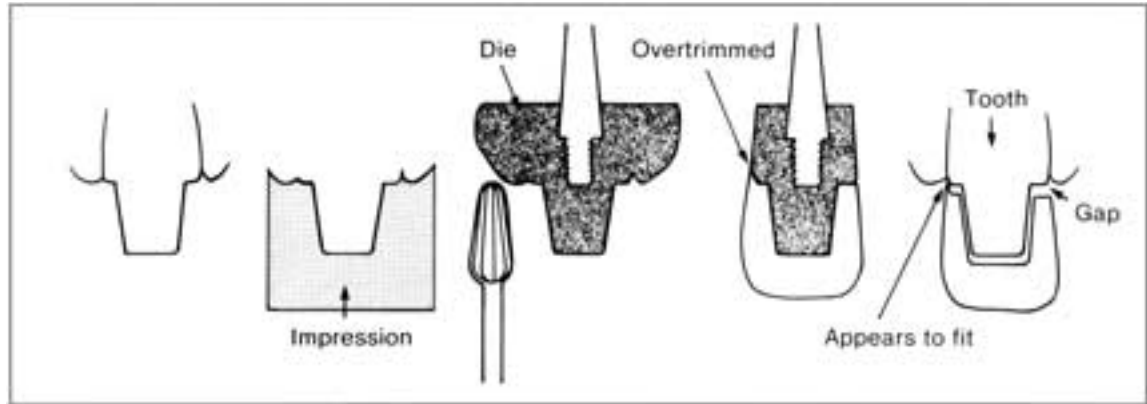
If there is a gap around only one part of the crown, it may be seating unevenly because of a tight contact point; otherwise the impression or die may have been distorted.

A positive ledge should be adjusted until the probe passes smoothly from tooth to crown without a catch. A negative ledge is a bigger problem and often means that the crown has to be remade.

### Checking retention

A crown should not feel tight. A crown for a long preparation with optimum taper, which will have excellent retention when cemented, may simply drop off the preparation when tried in. A feeling of tightness is the result of unnecessary roughness of the preparation or a casting that has been distorted. Tightness of fit is not a reliable test of retention, and tight crowns may be more difficult to cement, resulting in an open margin.

The crown should be tested for a tendency to tilt or pivot when rocked from side to side. Small pivoting movements show that the crown is not fully seated and is rocking about the contact points or on high spots on the fit surface – in which case the margins should be checked again.



**Figure 6.27**

Alternatively, there is too much space between the crown and the tooth. This may be due to the excessive use of die relief (a varnish spacer painted on to the die, avoiding the margins), an over-expanded casting or one that has had its fit surface ground.

### Checking and adjusting contact points and axial contours

Dental floss should be used to check that the contact points are neither too tight nor too slack. Tight contacts can be lightly ground a little at a time and polished; any deficiency in porcelain should have more porcelain added.

Buccal and lingual contours should not be too bulbous, the marginal area should be in line with the tooth surface to reduce plaque retention and the surface should look natural. Again, adjustments may be made by removing or adding materials and re-polishing or glazing.

### Checking and adjusting the shade

Shades that are slightly too light (the chroma too low) can be darkened by adding stain of appropriate colour and re-firing. Stain can also be used to add missing characteristics such as crack lines or mottled areas. However, if the basic hue is wrong or the chroma too dark, or the fault lies in the colour of the opaque core material or the 'dentine' porcelain, it is often not possible to change the shade sufficiently. The crown has to

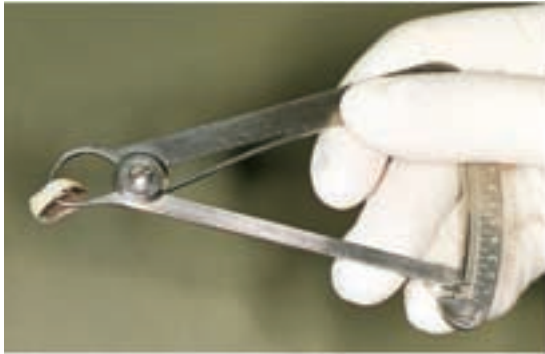be remade if it is a ceramic crown or the porcelain removed and replaced if it is a metal–ceramic crown.

A common cause of crowns not seating. The impression clearly shows the margin of the preparation but does not extend very far beyond it. It is often more difficult to distinguish the margin on the stone die than on the impression, particularly when dust from the trimming obscures vision. This leads to an over-trimmed die. To be on the 'safe side', the technician extends the crown beyond the margin, producing a bevel. This fits the die well, but when tried in the mouth the tiny bevel perches on top of the prepared margin, preventing the crown from fully seating. It may appear to fit in the over-trimmed area, but a gap will be present elsewhere.

be remade if it is a ceramic crown or the porcelain removed and replaced if it is a metal–ceramic crown.

### Checking and adjusting the occlusion

See Chapter 4 for details of occlusal adjustments. If reduction is necessary, the thickness of the occlusal surface should be checked with magnifying calipers (Figure 6.28).



**Figure 6.28**

A pair of callipers which magnify 1:10 being used to measure the thickness of the occlusal surface of a metal-ceramic crown. It is about 1 mm thick at this point.

## Cementation

When all the checks and adjustments are complete, the crown is permanently cemented. It is possible to provisionally cement a permanent crown to allow the patient to assess it for appearance and function. If this is done the temporary cement should be chosen so that the crown can be easily removed without damaging it. Usually a heavily modified temporary cement is used and the patient only left with this for a short time to reduce the risk of the crown falling off.

## Choice of cements

Cements used for permanent cementation include:

- Zinc phosphate cement
- Resin-based and adhesive cements
- Glass ionomer cement.

### Zinc phosphate cement

Zinc phosphate has been in use as a luting cement for much longer than all the others. Although its acidity has been assumed to be irritant to the pulp, literally millions of crowns have been cemented with it, with a very low proportion of clinically detectable ill effects. Patients sometimes complain of transient discomfort when the cement is setting if a local anaesthetic is not used,

but most patients need a local anaesthetic for crown cementation anyway and so this is not a major problem. However, the potentially irritant nature of the cement remains an anxiety. The pulps of some teeth fitted with crowns do become inflamed and eventually necrotic. This also happens occasionally with other cements, and it is difficult to identify the cause of pulp death. Was it the cement, the effects of preparing the tooth, or the original condition for which a crown was necessary?

Zinc phosphate has two major advantages which probably account for its continued popularity. It has a long, controllable working time and it produces the thinnest cement film, which can be as little as 10 micrometres. Of course, this is still ten times the diameter of the micro-organisms that lodge at the periphery of the cement film to form plaque.

### Resin-based and adhesive cements

A variety of resin-based luting materials are available. Although their use is increasing they are still not commonly used with conventional crowns for a number of reasons. First the truly adhesive cements containing either 4-META or a phosphonate derivative are inhibited from setting by the presence of oxygen. The margins of the restoration therefore have to be coated with an aqueous jelly material until the cement sets, and then cleaning up the surplus cement is difficult. A second reason is that, although they are initially more adhesive than the established luting

cements, they have not been used for long enough for dentists to be sure of their long-term success.

Therefore the resin-based and adhesive cements are used for luting porcelain veneers and minimum-preparation bridges (see Chapter 8), but are not yet commonly used for cementing conventional crowns. These materials are being developed rapidly and so their use may increase significantly in the future.

### **Glass ionomer cements**

Glass ionomer luting cement is popular with some dentists. It adheres to dentine and enamel, it leaches fluoride and is relatively non-irritant to the pulp. However, it has a higher solubility than other cements. It is available in capsulated form so the correct consistency of mix is always achieved.

## **Cementation technique**

### **Preparing the crown**

The crown should be completely cleaned of all traces of polish, disclosing wax, saliva and so on. This is best done in an ultrasonic cleaning bath, or if this is not available by scrubbing with a toothbrush and detergent. The crown should be thoroughly dried with blasts of air.

### **Preparing the tooth**

The tooth should be thoroughly washed with water spray and gently dried with air; it should not be over-dried, since this may damage the pulp by desiccation. The washing and drying should be left until the last minute to avoid contamination of the surface by saliva or gingival exudate.

### **Mixing and applying the cement**

The cement should be mixed according to the manufacturer's instructions. With zinc phosphate cement, slow mixing of small increments of

powder on a cool glass slab, over a wide area, will increase the working and setting time. This will also allow the pH to rise a little before the cement is applied to the tooth.

The cement is applied to the hollow part. With a complete crown this is the fit surface of the crown, while with a post it is the post hole in the tooth. When the opposite member is inserted into the hollow, the cement coats it and is extruded from the margins. If the other surface is coated with cement, for example the tooth preparation for a complete crown, it may be scraped off the surface when the crown is seated, and part of the surface left bare of cement.

The walls of a post hole may be coated using a rotary paste filler or file.

Nothing is gained by coating both surfaces. Time is lost, so that the cement becomes more viscous by the time the crown is seated, resulting in a thicker cement layer. The entire surface should be coated quickly with plenty of surplus cement. Any benefit that might be gained by applying a thin, even coat of cement is lost through the extra time taken to achieve this, with the cement beginning to set and getting thicker.

### **Inserting the crown**

The crown should be seated quickly and pressed home with firm, continuous force to extrude all the excess cement from the margins. The pressure may be applied by the operator or by the patient biting on a suitable prop, such as a cotton wool roll. Pressure should be maintained and the area kept dry with cotton rolls or absorbent pads and aspiration until the cement has set. Excess cement is also left until the set is complete and it is then removed.

## **Oral hygiene instruction and maintenance by the patient**

A final and important stage is to teach the patient how to clean and maintain the crown, and in particular how to clean the marginal area. Dental floss and an appropriate toothbrush technique should be advised.

Some patients already have excellent oral hygiene, and too much emphasis on the

importance of cleaning around the crowned tooth may result in over-enthusiastic cleaning, causing damage to the gingival tissues or to the tooth.

## **Recall, assessment, maintenance and repair**

### **Assessment**

A systematic assessment of all crowns should be made at each recall examination. This should include evaluation of the following factors.

### **Oral hygiene**

Plaque levels and gingival inflammation around the crown should be compared with similar teeth elsewhere in the mouth. If the crowned tooth is worse, the reason should be investigated and dealt with. In any case, when it is present, periodontal disease should be treated.

### **Margins**

The crown margins should be examined for positive and negative ledges and gaps, and preparation margins should be examined for secondary caries and signs of abrasive wear.

## **Structure of the crown**

This should be examined for fractures and wear, including occlusal perforations.

### **Appearance**

The appearance of the crown or the adjacent teeth may have altered since it was fitted. Any change should be assessed as acceptable or unacceptable. In the latter case the crown will usually have to be replaced: apart from grinding, little can be done to alter the crown's appearance once it is cemented.

### **Radiographs**

Periapical radiographs need only be taken if there are signs of failure or symptoms from the tooth. Routine screening radiographs for caries should be taken for the crown and for rest of the dentition at a frequency determined by the usual assessment of the patient's caries risk level.

## **Adjustments and repairs to crowns in situ**

These are dealt with in Chapter 14, together with bridges.



[WWW.HIGHDENT.IR](http://WWW.HIGHDENT.IR)

همیار دندانسازان و دندانپزشکان

---

# Part 2

# Bridges

---

[WWW.HIGHDENT.IR](http://WWW.HIGHDENT.IR)

همیار دندانسازان و دندانپزشکان

## 7

# Indications for bridges compared with partial dentures and implant-retained prostheses

The number of bridges made in the UK National Health Service (NHS) increased nearly 20-fold in the decade between 1980 and 1990. Since then the numbers have fallen although the average dentist working in the NHS still makes 34 bridges a year. Evidence from Commercial Dental Laboratories shows that there is considerable growth in the number of bridges being made privately, although detailed national figures are not available. It is probable that the overall number of bridges being made is still rising. Large increases are also reported in many other countries.

Clinical experience suggests that patients who, in the past, would have been prepared to wear a small partial denture are now reluctant to do so and ask for a bridge or implant-supported prosthesis. Implants are not available under the General Dental Services of the NHS and are generally more expensive than bridges. The result is that at present in the UK many more bridges are being made than implant-supported prostheses.

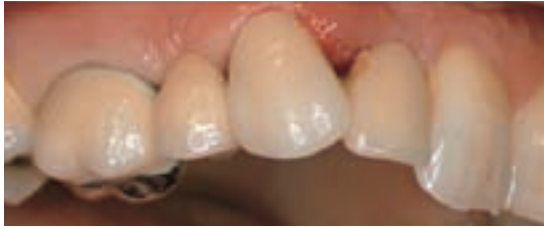## General terminology

The terminology used for bridges is sometimes rather loosely applied, and in different parts of the world the same terms are used to describe differ-

ent things. The word 'bridge' itself is used in the UK to describe a fixed appliance only, whereas in parts of the world it also includes certain tooth-borne removable appliances.

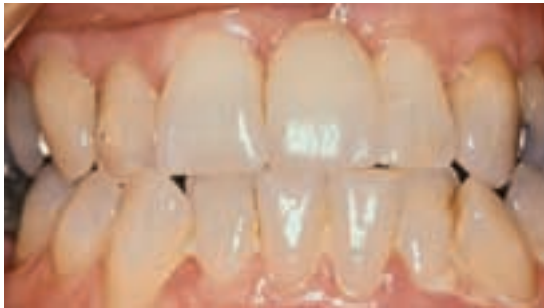The following names will be used for the various appliances. The terms in parentheses are those commonly used in the USA, although American terminology is rather variable.

- **A conventional bridge (fixed partial denture)** is an appliance replacing one or more teeth that cannot be removed by the patient (Figure 7.1a). The general term 'fixed bridge' is avoided since it implies one of the specific designs of bridge (see Chapter 8). Substantial tooth preparation is necessary for a conventional bridge. The bridge usually occupies no more space than the original dentition.
- **A minimum-preparation bridge (resin-bonded bridge, adhesive bridge, Maryland bridge)** is attached to the surface of minimally prepared (or unprepared) natural teeth and therefore occupies more space than the original dentition (Figure 7.1b).
- **A removable bridge** is very much the same as a bridge in that it is retained by crowns, is entirely tooth-supported, does not replace soft tissue and, unless it is examined closely, appears to be the same as a bridge. However, it can be removed by the patient (Figure 7.2).

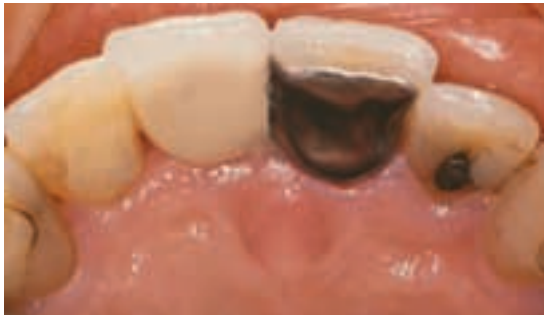**Figure 7.1**

Bridges.

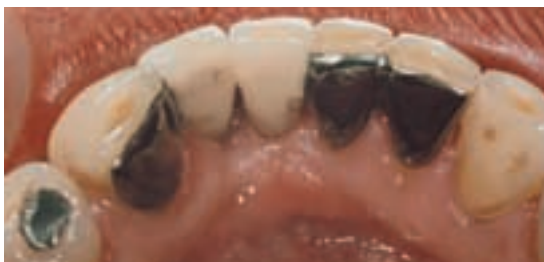*a* A conventional bridge replacing the upper right lateral incisor with a single artificial premolar tooth filling the space between the canine and first molar teeth. The bridge has just been cemented. The gingival condition around the molar abutment is good, but around the canine it is inflamed buccally as a result of irritation from a broken temporary bridge in this area.

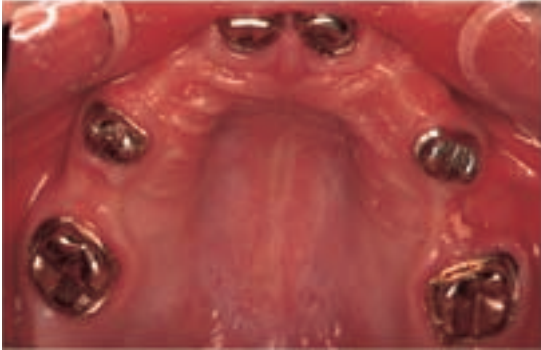

*b* and *c* A cantilever minimum-preparation bridge replacing a central incisor tooth.



*d* and *e* Two separate minimum-preparation cantilever bridges replacing two lower incisor teeth. One is supported by the canine and the other by the two remaining incisors splinted together. This design is likely to have a much better prognosis than a fixed-fixed design which would not allow any movement of the abutment teeth. The bridges had been in place for 9 years when this photograph was taken.

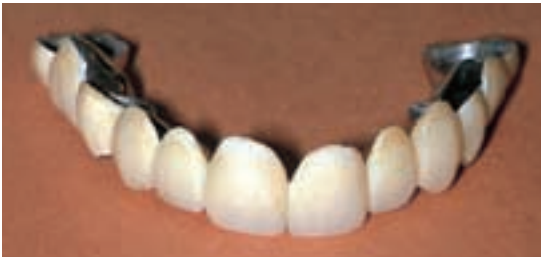



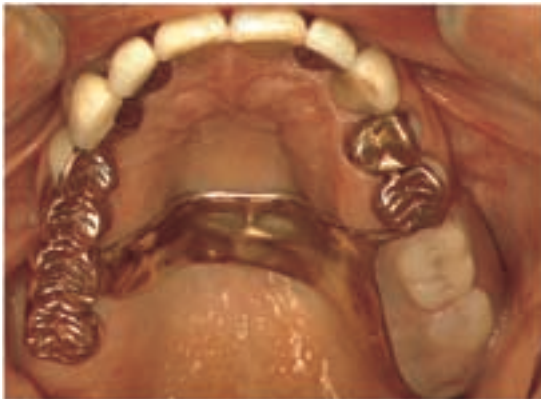**Figure 7.2**

A removable bridge.

*a* Cast copings permanently cemented to the remaining teeth. The external surfaces of these are milled parallel to each other in the laboratory.



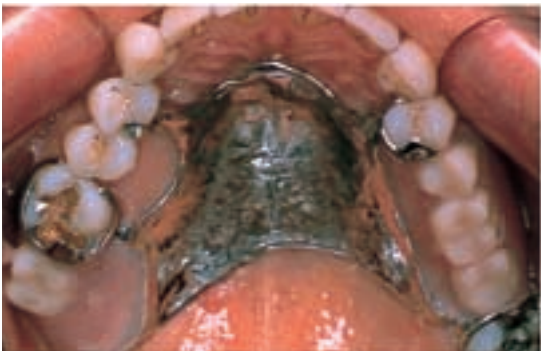*b* The removable bridge, which the patient can take out himself.




**Figure 7.3**

Partial dentures.

*a* A precision-attachment retained partial denture. In this case the two premolar teeth on the right of the picture are splinted together and an intra-coronal precision attachment is incorporated into the distal surface of the second premolar. The first molar on the left is an artificial tooth – part of a bridge – and it too contains a precision attachment. The partial denture retained by these two attachments can be removed by the patient.

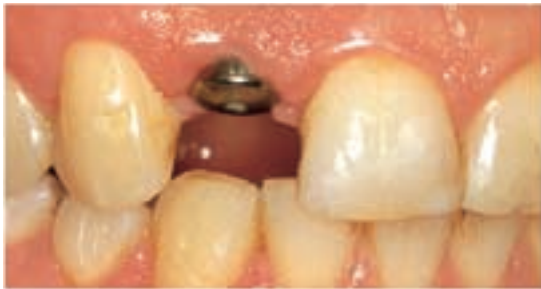

*b* A conventional cobalt-chromium partial upper denture that is tooth-supported with rests, clasps and a major palatal connector. None of the metal work is visible from the front of the mouth.



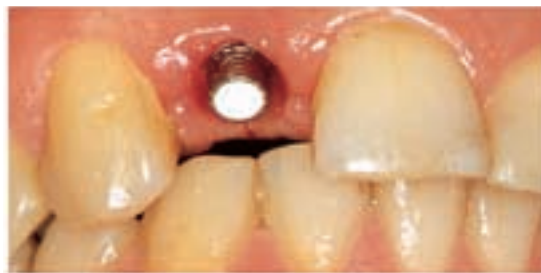**Figure 7.4**

*a* A cross-section through a typical implant. Systems vary and so this one will not be described in detail but it is typical in having four elements: from the top down the coarsely threaded screw is the implant which is screwed into a tapped hole in the bone and then covered to osseointegrate; the transmucosal abutment is smooth-sided and retained into the osseointegrated fixture by the middle-sized screw; the small screw at the bottom holds the restoration (the prosthetic elements) to the implant. There is now a wide range of prosthetic elements which will not be described here.

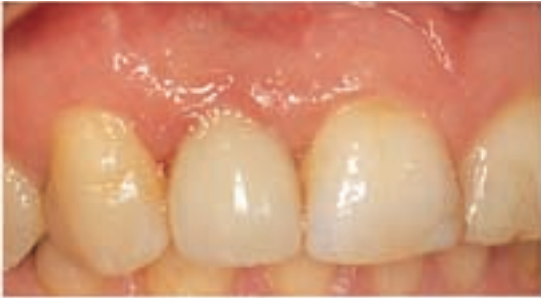

*b, c and d* A single tooth implant replacing the upper right lateral incisor.

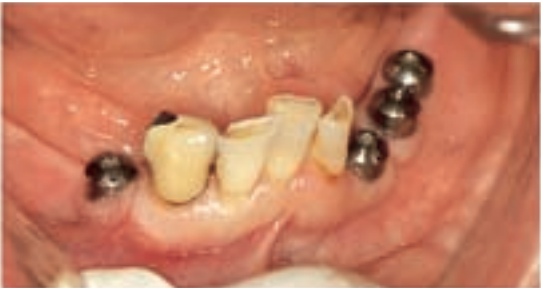*b* Shows the stage after the second surgical procedure to expose the fixture and to place the healing abutment. The healing abutment is in place and the incision line mesial and distal to it can still be seen.



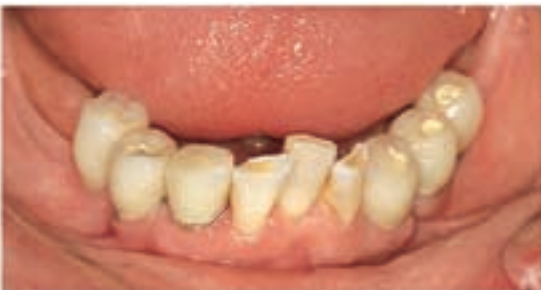*c* The healing abutment has been replaced by the transmucosal abutment (TMA).



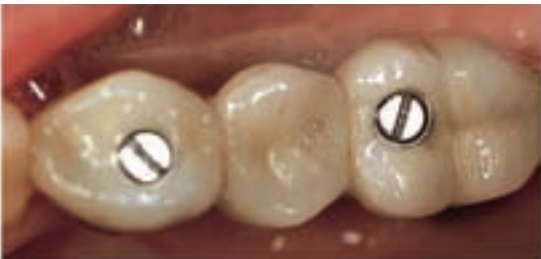d A crown has been fitted to the TMA.



e Four fixtures in the lower jaw.



f A three-unit 'bridge' has been attached to the three implants on the left and on the right, a three-unit cantilever bridge retained by the natural canine tooth and the implant has been extended with a cantilever premolar pontic.



g A three unit bridge retained by two fixtures showing the screws which can be undone if necessary by the dentist. These are covered with composite until it is necessary to gain access to the screws.



- **A partial denture** may be rested entirely on teeth, or be supported by the soft tissues, or by a combination of both. Rest seats are commonly used, but otherwise it is usually not necessary to prepare the natural teeth extensively. Partial dentures are retained by clasps, by adhesion to the soft tissues, or by dental or soft tissue undercuts (Figure 7.3b).
- **A precision-attachment partial denture** is retained by proprietary attachments and is removable by the patient. Soft tissue elements are replaced and the appliance usually has structures that pass across the oral tissues, for example across the palate or around the lingual alveolus. Natural teeth have to be prepared and crowns or other restorations made for them, incorporating part of the precision attachment (Figure 7.3a).
- **An implant-retained prosthesis** is one retained by osseointegrated implants (see Figure 7.4a). A single implant may support a single tooth prosthesis (Figure 7.4b, c and d) or a series of implants may support a prosthesis replacing a number of teeth. This is usually known as an implant-supported bridge. The patient cannot remove it, but in some cases the dentist can, by undoing the screws holding the prosthesis to the implants (Figure 7.4e, f and g). Implant-supported bridges may be small, replacing only one or two teeth, or may be larger, including replacing all the teeth in one arch. Implants may also be used to support a bar (or other attachments) on to which a removable complete overdenture can be clipped. Overdentures are beyond the scope of this book.

The term 'fixture' is sometimes used to describe the osseointegrated part of the implant, but is also sometimes used to describe the whole implant assembly. It is helpful to use the following terms:

- **Implant** to describe the part that osseointegrates and that is buried beneath the gingival tissues (in most systems) for a period of months before exposing it and inserting the
- **Transmucosal abutment (TMA)**, which is the part of the implant that attaches to the fixture and passes through the gingival tissues to the mouth. To this, is attached the
- **Restoration** which replaces the missing tooth or teeth.

## General advantages and disadvantages of replacing missing teeth

It is not always necessary to replace missing teeth, and in some cases there are positive disadvantages in doing so. At one time there was a rather naive, simplistic view that the mouth was a 'functioning machine' and that if part of it was missing, it was rather like a tooth or teeth missing from a cogwheel in a piece of machinery such as a car gearbox. This is not the case because the human body is much more adaptable and flexible than machinery engineered by man. In fact there is reasonably good evidence that, with a modern diet, it is perfectly possible to function with no molar teeth at all provided that the first and second premolar teeth and incisors are all present in the upper and lower jaws and are in occlusion. This has become known as the 'shortened dental arch'. Some patients cope very well with this but others feel that they cannot eat properly or are concerned about the appearance of the space behind the premolar teeth. With a shortened dental arch it is important that all the remaining teeth have good occlusal contact, or over-eruption and tilting will occur.

Despite this evidence, many patients would prefer to have at least some of their missing teeth replaced. It is the dentist's role, as a professional adviser, to advise the patient whether or not it is really in their best interest to have a tooth or teeth replaced. In some cases it is wise for a dentist to refuse to replace missing teeth, particularly by means that are likely to give rise to problems elsewhere in the mouth, or if the prosthesis has a poor prognosis, even if the patient attempts to insist that a replacement should be made. This is primarily for the patient's benefit but also for the dentist's. There have been a number of dento-legal cases in which dentists have been successfully sued for making prostheses, particularly bridges and implant-retained prostheses, when it was against the dentist's better judgement and the prosthesis has subsequently failed.

The first big decision that therefore must be made jointly by the dentist and patient is 'should the missing tooth/teeth be replaced or not?'

It is necessary for both the dentist and the patient – and in some cases a third party financially involved with the transaction – to be

convinced that the replacement will produce significantly more benefit than harm. The following questions must be asked:

- How will the patient's general or dental well-being be improved by the replacement?
  - What disadvantages will the replacement bring with it?
  - What is the ratio of these advantages and disadvantages?
- If the balance is strongly in favour of replacement, should the replacement be by means of:
  - A bridge
  - A partial denture
  - A removable bridge
  - An implant-retained prosthesis.
 (Of these, a bridge or a partial denture are by far the most common.)

## **Advantages of replacing missing teeth**

### **Appearance**

For many patients with teeth missing in the anterior part of the mouth, appearance is an overriding consideration. For them a replacement is certainly necessary. Just as with crowns, it is also necessary to judge the appearance of gaps further back in the mouth, taking account of the anatomy and movement of the patient's mouth.

### **Ability to eat**

Many patients manage to eat quite successfully with large numbers of teeth missing. Patients with no lower molar teeth who are fitted with well-designed and well-constructed partial lower dentures frequently leave them out because they claim that it is easier to eat without them. Some patients, though, have a genuine and persistent feeling of awkwardness if they are deprived of even one posterior tooth. As with appearance, the patient's concept of the problem is as important in deciding on a replacement as the problem itself. Generally though, the more teeth that are missing, the more important is a replacement. If a posterior tooth is to be lost it is generally sensible for the patient to live with the space for several months following extraction to determine

how essential it was before a decision is made regarding its replacement.

### **Occlusal stability**

This was discussed in Chapter 4, where it was also made clear that in many cases – although occlusal stability is lost initially when teeth are extracted – tilting and over-eruption usually eventually lead to an occlusal relationship that, although it may not be ideal and may contain occlusal interferences, is nevertheless stable. If the missing teeth can be replaced before the tooth movements occur and when tooth movements are likely, this may well be sufficient justification for the replacement. In many cases, however, the patient is first seen some years after the extraction and has a new stable relationship. Replacement of the missing teeth would therefore not improve the stability and so is not justified (see Figure 7.14). Special occlusal considerations are discussed under orthodontic retention and alterations to the OVD (see later).

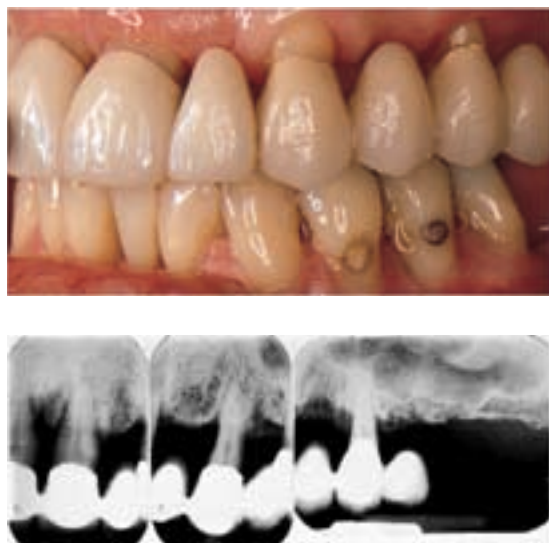### **Other advantages**

The three advantages listed above are by far the most common indications for replacing missing teeth. The following, though less common, can be extremely important for individual patients:

**Speech** Patients concerned about the quality of their speech are usually also concerned about their appearance. The upper incisor teeth are the most important in modifying speech, and so when they are missing they will usually be replaced to improve both speech and appearance.

**Periodontal splinting** Following the successful treatment of advanced periodontal disease, it may be necessary to splint uncomfortably mobile teeth. In order to produce a cross-arch splinting effect it is necessary to bridge any gaps to provide a continuous splint – whether or not there are any other indications for replacing the missing teeth (Figure 7.5).

**A feeling of 'completeness'** Some patients believe, or have been told, that there is a major

**Figure 7.5**

*a* A 12-unit bridge supported by 6 teeth with considerably reduced periodontal support. Several teeth were uncomfortably mobile before the provisional bridge was fitted. The patient was able to maintain good oral hygiene following periodontal therapy, and the provisional bridge was replaced after a year by this permanent bridge. The patient understood the reasons for the visible supragingival margins and accepted them. The bridge lasted just over 20 years before it had to be removed and the abutment teeth extracted.

*b* Radiographs of the three abutment teeth on the left-hand side for the patient shown in *a* at the time the bridge was fitted.

disadvantage to having teeth missing, even when they have no problems with appearance, eating or occlusal stability. These patients appear to receive considerable comfort from a bridge – less from a removable appliance. This feeling should not be discounted if it is held with conviction, even though the dentist may not be equally convinced of the benefits of a bridge. However, such attitudes should not be encouraged.

**Orthodontic retention** Most orthodontic treatment is stable, but it is occasionally necessary to provide a bridge partly to maintain an orthodontic result. A common example is in cases where the lateral incisors are congenitally missing and the upper canines have been retracted to recreate space for them. The main reason for replacing the missing lateral incisors is, of course, appearance, but a second reason is to prevent the canine teeth relapsing forwards again, and so the bridges must be designed to serve this purpose. The resulting appearance is usually better than attempts at converting the appearance of the canines to lateral incisors.

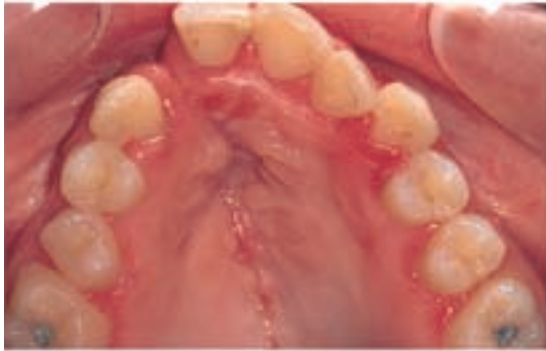Another example is in patients with cleft palates who have been treated orthodontically as well as surgically (Figure 7.6).

Orthodontic retention is a special example of an indication for tooth replacement for reasons of occlusal stability. In almost all patients who have taken the trouble to have orthodontic treatment, appearance will also be important.

**Restoring occlusal vertical dimension (OVD)** Occlusal collapse with excessive wear or drifting of the incisor teeth sometimes follows the loss of a number of posterior teeth. This is a difficult problem to treat, but in some cases the posterior teeth are replaced by bridges, removable dentures or implants that not only replace the missing teeth but restore the lost OVD, creating space for the upper incisors to be retracted or crowned as necessary.

**Wind-instrument players** Players of brass or reed instruments contract the oral musculature to form what is known as the embouchure. This allows for the proper supply of air to the instrument. Even minor variations in the shape of the teeth can affect the embouchure, and missing teeth can have a disastrous effect on the music produced by some players.

With brass instruments the mouthpiece is supported indirectly by the teeth, via pressure on



**Figure 7.6**

A surgically repaired cleft lip and palate with missing lateral incisor to be replaced by a bridge. The palatal gingival inflammation is exacerbated by the temporary denture – an additional indication for a bridge.

the lip. Clearly with these patients not only is the replacement of any missing teeth essential but a bridge or an implant-supported restoration will usually be necessary. This must be designed very carefully to reproduce as much of the original contours of the missing teeth as possible.

With reed instruments the mouthpiece is inside the musician's mouth and any pressure from it is to the palatal side of the upper incisors.

### **Disadvantages of replacing missing teeth**

#### **Damage to tooth and pulp**

In preparing teeth for conventional bridges or precision-attachment partial dentures, it may be necessary to remove substantial amounts of healthy tooth tissue. This damage, although it may be justified if the indications are powerful enough, should not be undertaken lightly. The problem is less serious if the teeth to be used to support the bridge are already heavily restored or crowned.

Whenever a tooth is prepared, there is a danger to the pulp, even if proper precautions such as cooling the bur are followed. There is sometimes an additional threat to the pulp when teeth are prepared for bridges. With some designs, preparations for two or more teeth have to be made parallel to each other, and if the teeth are slightly out of alignment, the attempt to make

the preparations parallel may involve more reduction in one part of the tooth than if it were for a crown and so endanger the pulp.

With the falling incidence of caries in many countries, and a more conservative approach to restorative dentistry, situations arise more and more commonly in which the logical abutment teeth for a bridge are sound and unrestored or have minimal restorations. To prepare these teeth would be very destructive, and this is one reason why the minimum-preparation bridge and implant-retained prostheses are becoming so popular.

#### **Secondary caries**

As with all restorations, bridges carry the risk of microleakage and caries. This risk is more significant (particularly dento-legally) if the restoration is an elective one rather than the result of caries.

#### **Failures**

Chapter 14 contains a black museum of failures among crowns, bridges and implant-retained prostheses. Provided that the bridge is well planned and executed and the patient is taught proper maintenance and is conscientious, the chances of failure are small. However, there is always an element of risk, and this must be explained to the patient.

**How long do bridges last?**

This is an impossible question to answer for the individual patient and bridge. Some start with a better chance of survival than others. Chapter 14 gives a more extensive discussion of restoration failure.

**Effects on the periodontium**

There is ample evidence that subgingival crown margins, whether or not as part of a bridge, increase the likelihood of gingival inflammation. Although there is less evidence that this progresses to destructive periodontal disease, it is an unwelcome factor. Even poorly maintained supragingival crown margins can produce periodontal effects, as can restrictions of embrasure spaces and reducing access by the presence of a bridge. The average partial denture is capable of causing even more significant periodontal damage.

Some patients, given extensive courses of treatment, even if without special oral hygiene instruction, still improve their plaque control. Presumably their increased dental awareness improves their motivation. Although this change seems to have long-lasting effects, it is obviously not a justification on its own for making bridges.

**Cost and discomfort**

Many patients regard these as the most important disadvantages in any tooth replacement. Bridges, dentures and implant-retained prostheses cannot be made other than by the individual attention of the dentist and the technician. Personal service of this type will always be expensive. The cost of partial dentures does not significantly rise in proportion to the number of missing teeth, whereas the cost of a bridge tends to do so.

Implant treatment is usually charged per fixture, irrespective of the number of artificial teeth supported by each implant. Traditionally, the charges were significantly higher than those for bridges, which are in turn higher than those for partial dentures. However, this has changed over the years, partly due to increasing costs for

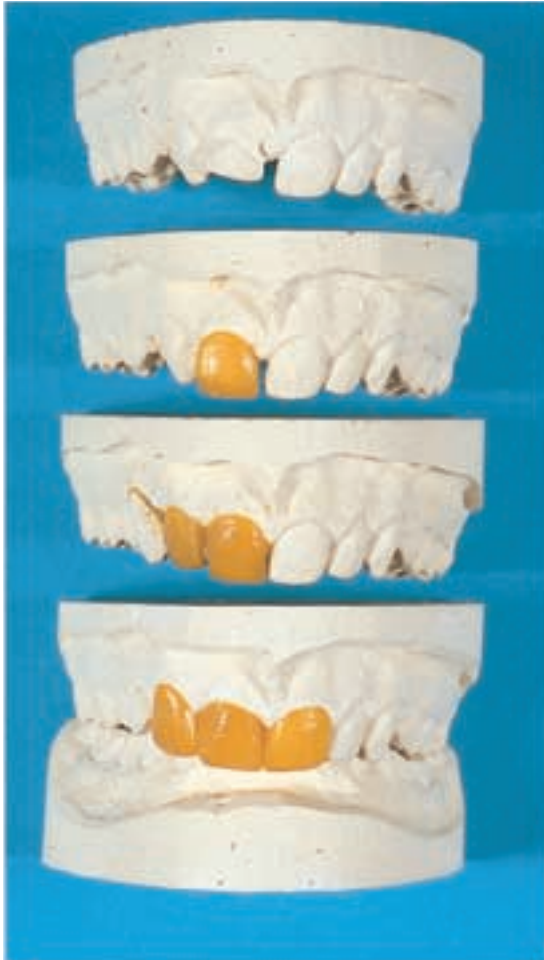
conventional bridges and increasing use of implants. The reason for this ratio is more to do with the perception by both patient and dentist of the skill and training required of the dentist and technician for each of the procedures, together with a concept that the more 'sophisticated' procedures must cost more. This approach is based on historical and traditional views and is not particularly logical. There is nothing intrinsically more difficult or demanding about any of the techniques as compared with the others. If anything, bridges are more demanding because, once they are permanently cemented, it is difficult to make any significant modifications. However, removable dentures and implant-retained prostheses that can be unscrewed and removed by the dentist give more potential for modifications after they are fitted.

Comparing typical fees and calculating approximate fees per hour for the three treatment methods of partial dentures, bridges and implant-retained prostheses, and taking the cost for replacing one tooth with a partial denture as the baseline, replacing it with a bridge would cost two to three times as much and with an implant-retained prosthesis three to four times as much, even allowing for the additional items that must be purchased for the implants.

Dental treatment is much less painful than some patients imagine, but there is nearly always some discomfort, such as holding the mouth open for long periods and difficulty in controlling fluids in the mouth. If the treatment is carried out under sedation, there are the disadvantages of the patient needing to be accompanied, being unable to drive after the appointment, and so on.

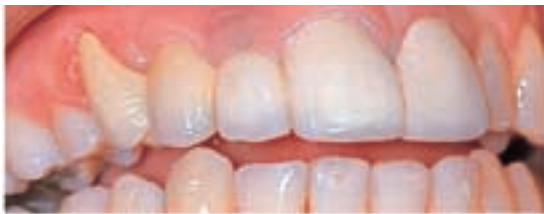**The choice between fixed and removable prostheses****General considerations****Patient attitude**

Patients show different degrees of enthusiasm for fixed and removable prostheses. Unless the patient is particularly anxious to have a bridge or implant-retained prosthesis and fully understands the implications, it is often better, particularly when a number of teeth are missing, to make a partial



**Figure 7.7**

*a* Original study cast and diagnostic wax-ups for a patient who lost the upper right central incisor in an accident in his early teens. Rather than maintain the space, the lateral incisor was moved into the position of the central incisor and the canine tooth into the position of the lateral incisor. On the patient's left the first premolar was extracted since the teeth were crowded, and so the midline was maintained. This study cast was made when the patient was 16 and was becoming very concerned about his appearance. The shape of the lateral incisor had been modified with composite, but this and the canine tooth were still unattractive. The appearance of simply crowning the lateral incisor to make it resemble a central incisor is shown in the first diagnostic wax-up. This is also not satisfactory, and so the second diagnostic wax-up shows the effects of extracting the upper right first premolar, retracting the canine tooth and the lateral incisor orthodontically and making a bridge to replace the central incisor tooth. However, the patient was not prepared to have further orthodontic treatment to achieve this ideal result, and so the bottom diagnostic wax-up shows the appearance that would be achieved by extracting the lateral incisor and making a conventional three-unit fixed-fixed bridge. This is a very destructive approach, but was justified in this case in view of the patient's considerable anxiety over his appearance.



*b* The bridge in place. The patient is happy with this appearance and considers the treatment to be successful.

denture first to see how the patient responds. It may be that the denture is satisfactory, both aesthetically and functionally. If so, the destructive and irreversible tooth preparations that may be necessary for a bridge or surgical procedures for implants can be avoided, or at least deferred.

Alternatively, if the patient is unhappy with the partial denture, he or she will enter into the arrangements for making a bridge or implant-retained prostheses with greater enthusiasm and commitment. They will have had experience of the alternative to a bridge or implant-retained

prosthesis and therefore have better information upon which to base their consent to a more interventive and expensive procedure.

Patients should never be persuaded to have bridges or implants against their wishes, and they must give fully informed consent, including enough time to reflect. Some patients take longer to make their minds up, or to plan the financial implications. It is prudent to put the summary of treatment proposed with the alternatives along with the full costs in simple, short but not patronizing written form to allow the patient time to consider the plan before starting treatment.

### Age and sex

Similar arguments apply to bridges as to crowns (see Chapter 3). However, whereas there may be no satisfactory alternative to a crown for an old or young patient, a partial denture may make a very satisfactory alternative to a bridge or implant-retained prostheses. This is particularly true for very young patients, who may not fully appreciate the lifelong implications of bridges or implants. It is better to make a minimum-preparation bridge or partial denture until the patient is mature enough to assess the relative merits of the alternatives. But a teenager with a missing incisor who cannot be fitted with a minimum-preparation bridge may be desperately unhappy about wearing a partial denture. In this case, the provision of a conventional bridge or single tooth implant as early as possible may make a remarkable psychological difference (Figures 7.4b, c and d and Figure 7.7).

At the other end of the age scale, no patient, however old, should be written off as being past having a bridge. Figure 9.4c shows an immediate insertion provisional bridge made for a spritely 76-year-old who would have been appalled at the idea of wearing a partial denture. Many patients 10 or more years older than this would have the same attitude. Figure 9.4c was published in the first edition of this textbook and the patient is still well and happily wearing the permanent bridge made when the two lower incisor sockets had fully healed. The bridge has so far lasted for more than 17 years and, like the patient (now 93), is still going strong.

### Confidence

Many patients feel more confident with a bridge than with any form of removable appliance.

However retentive a partial denture, some patients never lose the anxiety that it will become dislodged during speaking or eating. Others are not prepared to remove partial dentures at night.

Many patients do tolerate partial dentures very well, however, and it is often difficult to tell beforehand what the response will be to either form of treatment. The majority of patients who have had both partial dentures and bridges prefer the latter.

### Occupation

Sports players and wind-instrument players have been referred to earlier (see Chapter 3). Although sports players should be provided with crowns when necessary, it may be better to defer making an anterior bridge or implant-retained prostheses until the patient gives up the more violent sports, and meanwhile to provide a partial denture.

Although wind-instrument players usually need a bridge replacement for their missing anterior teeth, there are some who find that air escapes beneath and between the teeth of a bridge. They are better able to maintain a seal with a partial denture carrying a buccal flange.

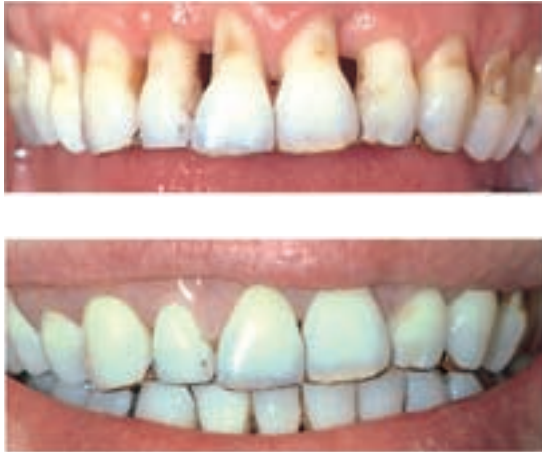Public speakers and singers who make more extreme movements of the mouth often need the confidence that comes from wearing a bridge.

### General health

Both bridges and partial dentures are elective forms of treatment, and need not be provided for people who are ill. When tooth replacement is necessary for someone who will have difficulty tolerating it because of poor physical or mental health, or when there are medical complications such as with patients who require antibiotic cover for every appointment, it is better to consider the simpler, less time-consuming form of treatment first. Having missing anterior teeth replaced, though, can boost the morale of patients recovering from long illnesses or facial trauma.

### Appearance

When a tooth is lost, alveolar bone and gingival contour are also lost, and it is never possible to disguise this fact entirely (Figures 7.1a and 9.9a). Thus no artificial replacements ever look exactly like the natural teeth, although some may be

**Figure 7.8**

*a* An unsightly appearance following gingival recession and surgery. The teeth are splinted together.

*b* A removable acrylic gingival prosthesis in place.

sufficiently realistic to deceive all except the dentist with their bright light and mouth mirror. In some cases dentures with flanges achieve this object better than bridges; in others bridges have the better appearance. When a substantial amount of alveolar bone is lost, the combination of a bridge with a separate removable buccal flange sometimes gives the best appearance (Figure 7.8).

When the loss of alveolar bone is significant and the lipline is such that it shows and is difficult to disguise easily, the ridge may be augmented surgically and the tooth or teeth replaced by a bridge or implant. The preferred material is autogenous bone – usually taken from somewhere within the patient's mouth, often the chin, or the maxillary tuberosity or the ramus – but freeze-dried bone or other artificial materials are available (Figure 7.9).

### **General dental considerations**

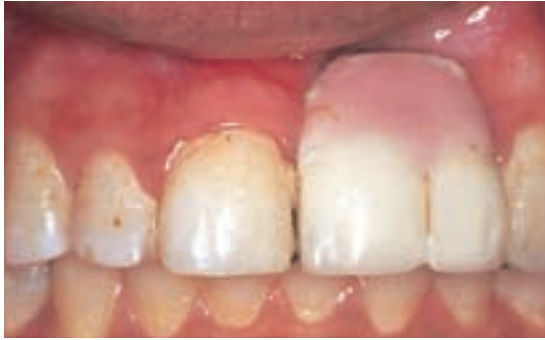Questions of oral hygiene and periodontal health were dealt with in relation to crowns in Chapter 3 and similar considerations apply to bridges. However, when there are strong indications for replacing missing teeth in a case where there has been periodontal disease and alveolar bone loss,

provided that the periodontal disease is under control it is preferable to provide a bridge whenever possible rather than a partial denture. This is because a number of abutment teeth splinted together as part of a bridge have a better prognosis than individual teeth with reduced alveolar support, which may be mobile, used as denture abutments.

When only one or two teeth are missing in the arch, a bridge or implant restoration is usually considered the better solution. When large numbers of teeth are missing, particularly when there are free-end saddles, partial dentures or implant-retained prostheses are a more logical choice. In some cases the preferred treatment is to replace one or two missing anterior teeth with a bridge and the posterior teeth with a partial denture. This has the advantage that the patient is not embarrassed to leave the denture out at night and is more confident when wearing it during the day.

Occlusal problems may indicate a bridge rather than a partial denture. For example, a missing upper incisor in an Angles Class II Division I malocclusion with the lower incisors occluding against the palate would be difficult to replace by means of a partial denture without increasing the occlusal vertical dimension (OVD) or providing orthodontic treatment; a bridge would be more straightforward (Figure 7.10).

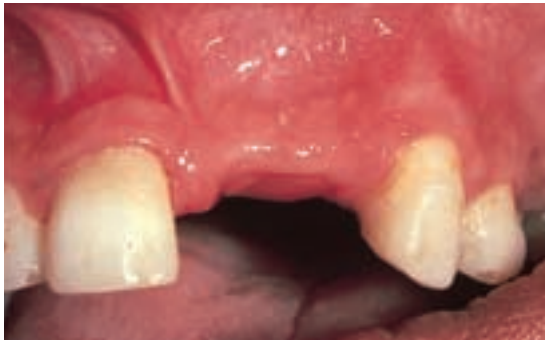



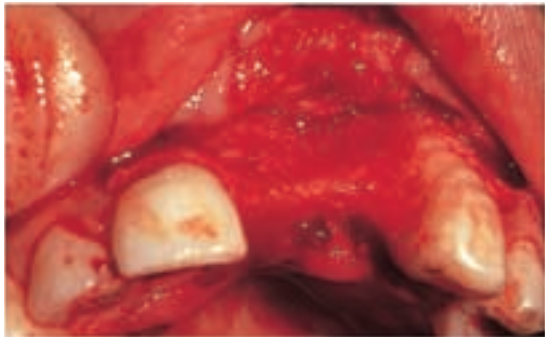
**Figure 7.9**

Surgical ridge augmentation.

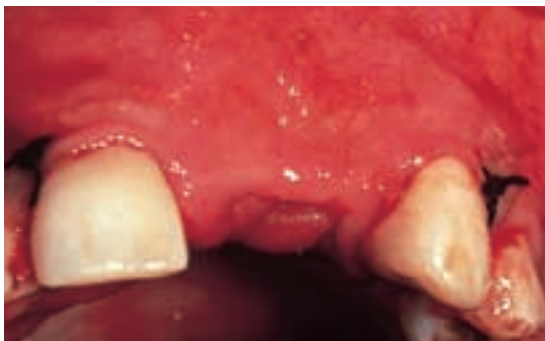*a* A minimum preparation bridge with a very unsightly and unsatisfactory flange in pink porcelain which does not match the patient's gingival pigmentation. It is also unhygienic.



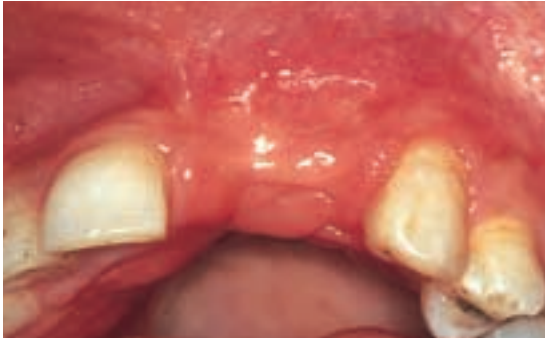*b* After removing the bridge the thin receded ridge can be seen.



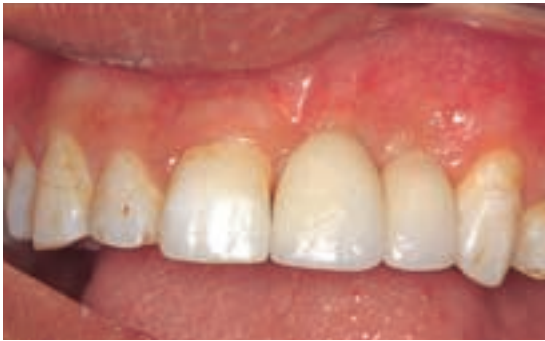*c* The alveolar ridge is exposed.



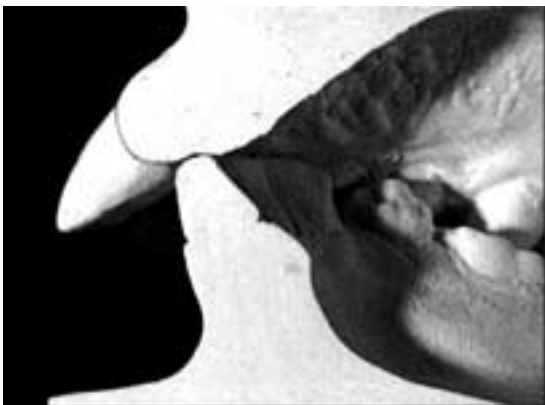
*d* After augmentation and suturing.



e The ridge healed.



f A new minimum-preparation bridge with an improved appearance of the pontics and the augmented ridge. It is also more cleansable.



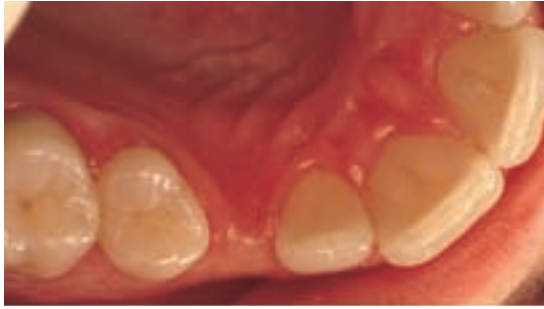**Figure 7.10**

Sectioned study casts of a patient with a complete overbite, with the lower incisors occluding against the palate. A denture would not be possible without altering the occlusion, shortening the lower teeth or providing orthodontic treatment.

### **Local dental considerations**

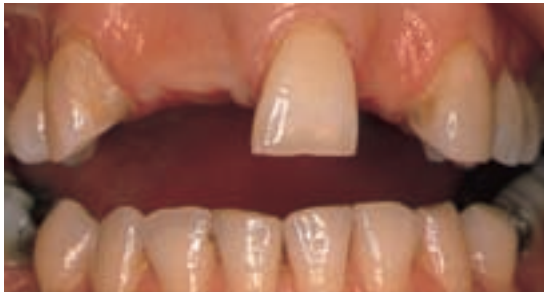The condition of the teeth adjacent to and opposing the missing teeth may help to determine whether a fixed or removable prosthesis is indicated. When the prognosis of teeth adjacent to the space is doubtful it may be better to provide a partial denture – at least in the short

term until the prognosis is clearer. The doubtful tooth could then either be used as a support for a bridge or extracted and a larger bridge or denture constructed. If the angulation or size of the teeth adjacent to the space make them unsuitable to support a bridge, it may be better to provide a partial denture rather than design an unnecessarily elaborate and complex bridge.

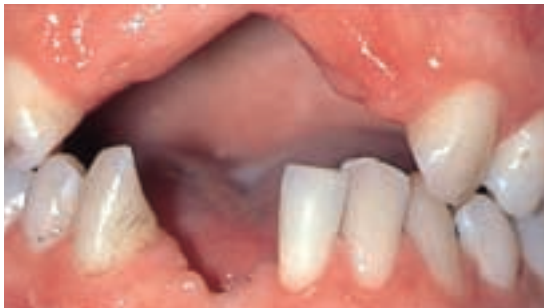**Figure 7.11**

Cases illustrating indications for bridges.

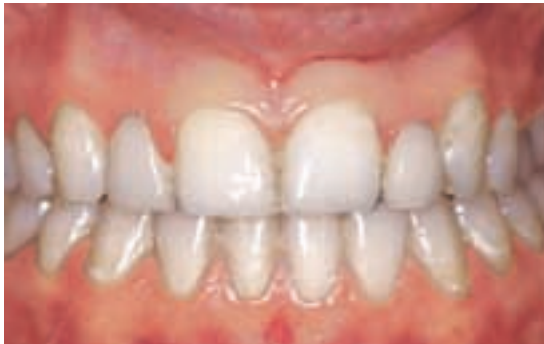*a* A small but visible space in an otherwise healthy and unrestored arch. The indication here is to improve the patient's appearance and prevent any further mesial movement of the posterior teeth, which have already reduced this two-unit space to less than a single tooth width. Orthodontic treatment to complete the closure was not possible. A minimum-preparation bridge was made.



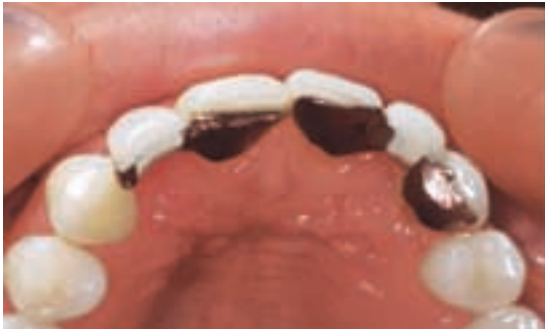*b* The patient, a professional singer, had tried a succession of partial dentures of various designs. She did not like the appearance of any of them and did not feel secure about their retention when singing. The bridge, which is shown in Figure 9.4d (page 217), has now been present for more than 30 years and has solved her problems.



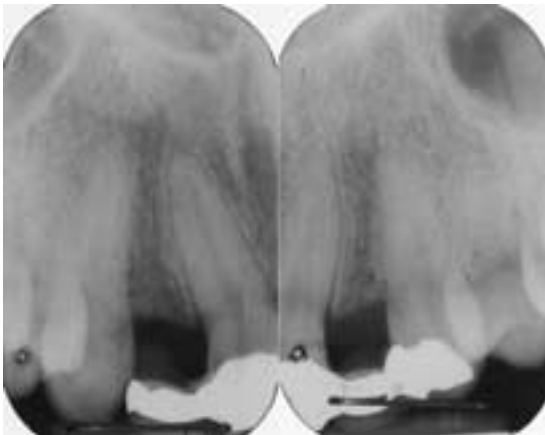
*c* Substantial alveolar bone loss together with the loss of several teeth following a motorcycle accident in an 18-year-old girl. The soft tissue support is not ideally suited to dentures. The patient was very depressed about her other facial injuries and felt unable to cope with dentures. The preparations for the lower bridge are shown in Figure 3.17h (page 72) and the finished bridge, together with the preparations for the upper bridge, in Figure 8.1a (page 198).



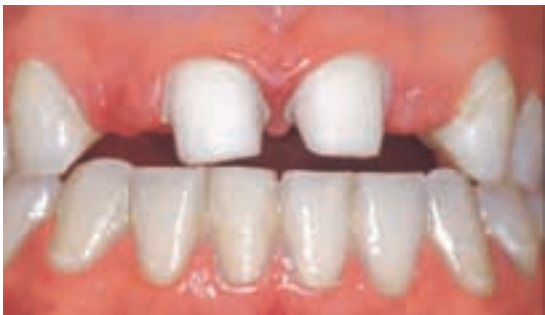*d* A patient with developmentally missing upper lateral incisor teeth replaced with minimum-preparation bridges.



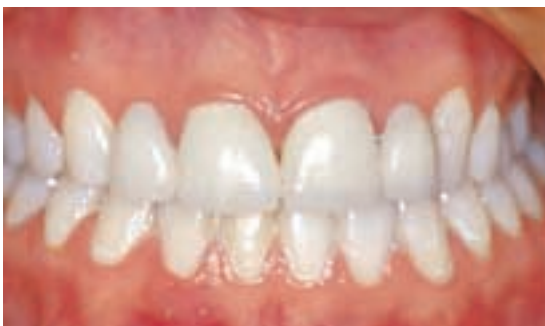e Originally both of fixed/fixed design they have repeatedly debonded and one has been converted to a cantilever design. The patient requests alternative treatment.



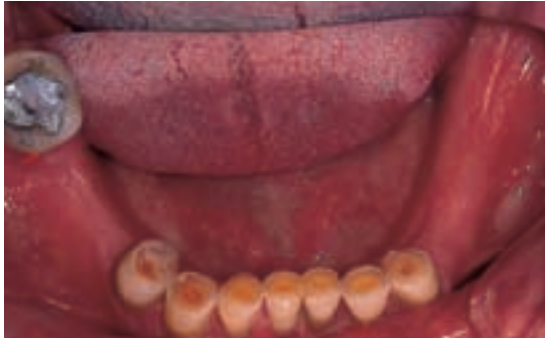f Long cone periapical radiographs show root convergence that does not allow space for implants. Orthodontic treatment to open the spaces was declined by the patient.



g The central incisor teeth are prepared for conventional metal-ceramic cantilever bridges.

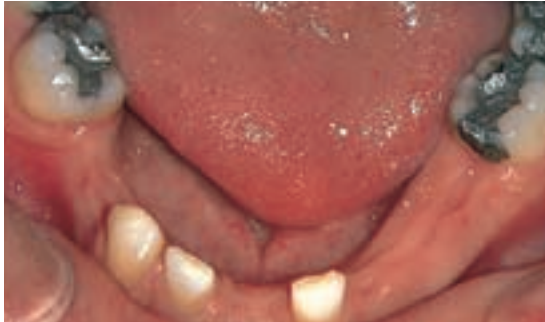

h Completed bridges.

**Figure 7.12**

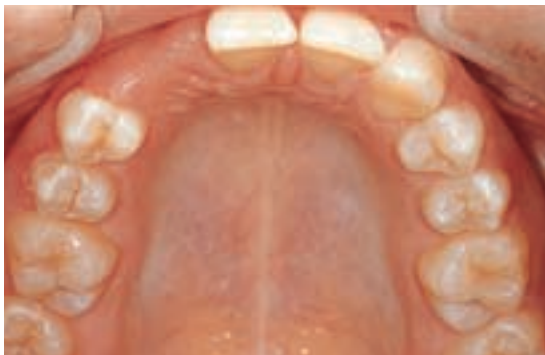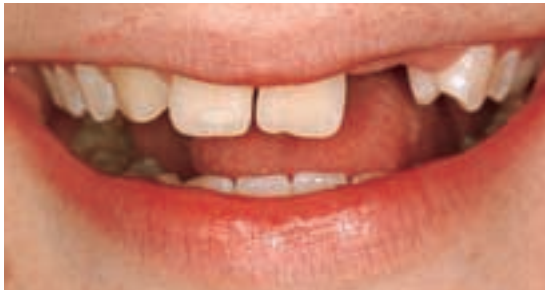Indications for partial dentures.

*a* A heavily worn dentition with short clinical crowns and no posterior teeth on one side. A partial denture is the obvious choice here.



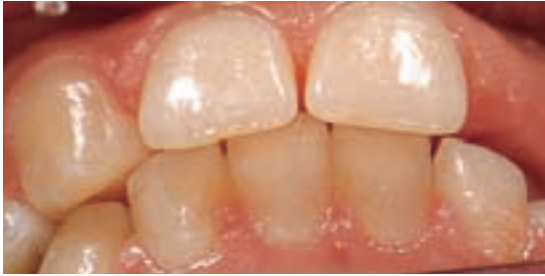*b* Several teeth missing as a result of hypodontia in a 19-year-old patient. In view of the recent extraction of the deciduous teeth together with the apparently high caries incidence judged from the number and size of amalgam restorations, and the small size of the anterior abutment teeth, a partial denture was provided. An additional problem in providing a bridge would have been the lingual inclination of the first lower molar teeth, making parallel preparation difficult. Implants would have been a possibility, probably with ridge augmentation, if funding was available.

In both *a* and *b* the indications for replacing the missing teeth are both aesthetic and functional.

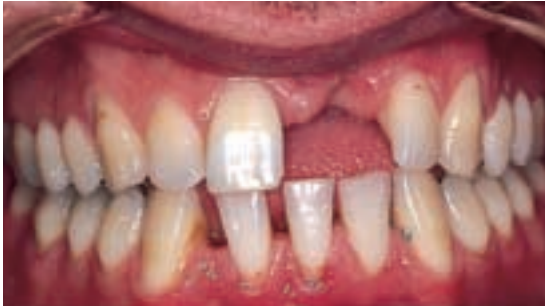**Figure 7.13**

Indications for implants.

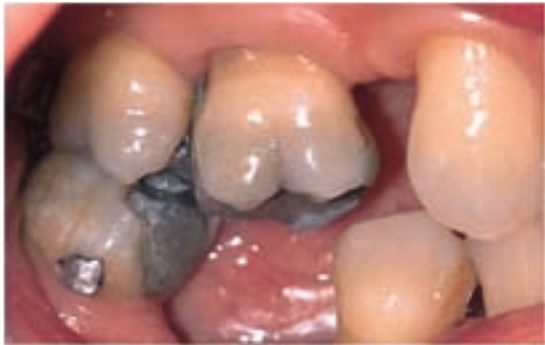*a* and *b* The upper left lateral incisor and canine teeth have been lost through trauma. The mouth is very clean and well cared for with no caries or restorations. The ridge is substantial (confirmed by appropriate imaging).



c The occlusion of the patient shown in *a* and *b*. It is unfavourable for a minimum-preparation bridge. Therefore all the indications in this case are for an implant-retained prosthesis.



*d* In this case only one central incisor tooth is missing but the gap is much greater than the other central incisor. The patient had previously had a midline diastema with which he was content. The mouth is well cared for with few restorations and a single tooth implant is indicated.



**Figure 7.14**

This patient had had these spaces for many years and, despite some mesial drift of the lower molar tooth and considerable mesial movement of the upper molar teeth – so that space for both premolar teeth was now less than half a unit – she was not concerned about the appearance, had no difficulty eating, and even these extensive tooth movements had not produced occlusal interferences. There is therefore insufficient justification to replace any of the missing teeth.

### Examples of specific indications for bridges, dentures and implant bridges

Figure 7.11 shows four cases in which bridges were preferable, and Figure 7.12 one where a partial denture was the chosen treatment and one where it might have been. Figure 7.13 shows patients for whom implant-retained bridges are indicated. Figure 7.14 shows a case where it would be better to leave the patient with no prosthesis.

### Scope of this book

This chapter has dealt with the decisions to be made about whether the tooth or teeth should be replaced and, if so, whether the replacement should be by a partial denture, bridge or implant-retained prosthesis. All these alternatives need to be considered equally at the planning stage and so are included here in some detail.

**WWW.HIGHDENT.IR**

همیار دندانسازان و دندانپزشکان

## 8

## Types of bridge

The appliances used to replace missing teeth were defined in Chapter 7. Some of the terms used for bridges are also used in relation to partial dentures.

- The **saddle** is the edentulous alveolar ridge where a tooth/teeth are to be replaced.
- An **abutment** is a tooth to which a bridge (or partial denture) is attached.
- A **retainer** is a crown or other restoration that is cemented to the abutment. The terms 'retainer' and 'abutment' should not be confused or used interchangeably.
- A **wing** is a term sometimes used for a minimum preparation retainer.
- A **pontic** is an artificial tooth as part of a bridge.
- A **span** is the space between natural teeth that is to be filled by the bridge.
- A **pier** is an abutment tooth standing between and supporting two pontics, each pontic being attached to a further abutment tooth.
- A **unit**, when applied to bridgework, means either a retainer or a pontic. A bridge with two retainers and one pontic would therefore be a three-unit bridge.
- A **connector** (or joint) connects a pontic to a retainer, or two retainers to each other. Connectors may either be fixed or allow some movement between the components that they join.

### Conventional and minimum-preparation bridges

Conventional bridges involve removing tooth tissue, or a previous restoration, and replacing it with a retainer. This may be destructive of tooth tissue and will certainly be time-consuming and expensive. The alternative, minimum-preparation bridge involves attaching pontics via a metal wing to the unprepared (or minimally prepared) lingual and proximal surfaces of adjacent teeth. The

attachment is made by an adhesive resin material, retained by the acid-etch technique to the enamel and by other means to the metal. These bridges can be used only when the abutment teeth have sufficient intact enamel.

### Basic designs, combinations and variations

There are four basic designs of bridge, the difference being the type of support provided at each end of the pontic. The same name is given to the design, however many pontics there are in the span and abutment teeth splinted at one end of the span (Figure 8.1).

The four basic designs are the same whether the bridge is a conventional or a minimum-preparation type. It is possible to combine two or more of the four basic designs and to combine conventional and minimum-preparation retainers in the same bridge (the hybrid bridge – see page 204).

Of the four basic designs, the first three may be either conventional or minimum-preparation types. Minimum-preparation versions of the spring cantilever bridge are rarely made and conventional spring cantilever bridges are only made very rarely. There are better alternatives. However, some patients still have spring cantilever bridges which need to be maintained, so dentists need to recognise them.

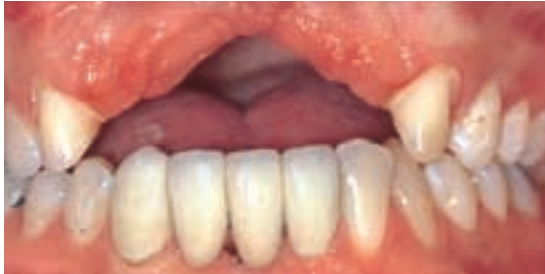### *The four basic designs (Figure 8.1)*

Only the first three designs are still made.

#### Fixed–fixed bridge

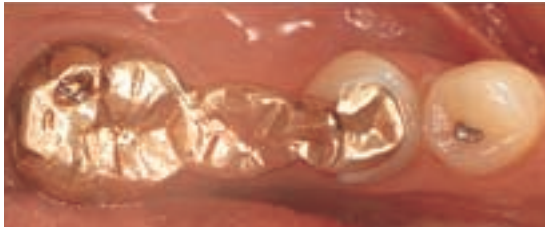A fixed–fixed bridge (Figure 8.1a) has a rigid connector at both ends of the pontic. The



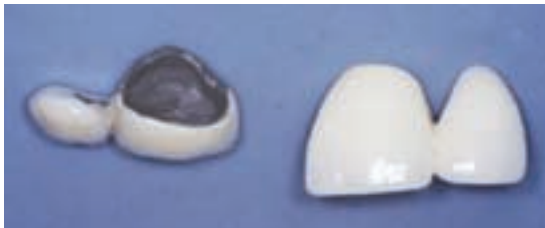
**Figure 8.1**

Four basic designs of conventional bridges.

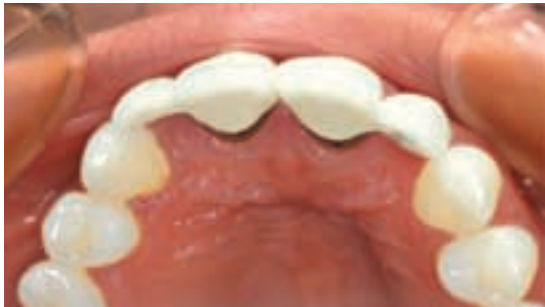*a* Fixed–fixed: both upper and lower bridges will be fixed–fixed, the lower retained by complete crowns on the canine tooth and central incisor (see Figures 7.11c and 3.17h for the preoperative condition and the preparations). The upper bridge will be retained by the canine teeth only (see page 227 for the rationale for this design). The bridge was made before implants were generally available but if they had been, a considerable amount of bone grafting would have been necessary.



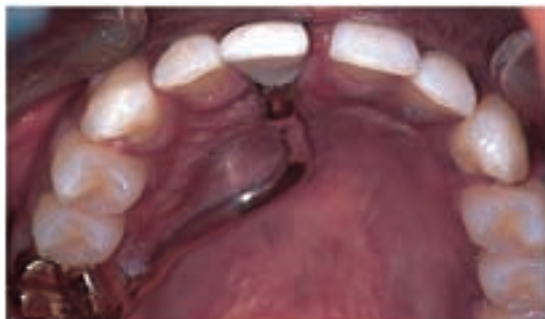*b* Fixed–movable: a DO inlay in the lower second premolar and full crown on the molar tooth. This bridge has been present for 20 years – in fact so long that the occlusal surface of the crown has worn through (see Chapter 14). The movable joint can be seen between the pontic and the minor retainer. It would not normally be as obvious as this.



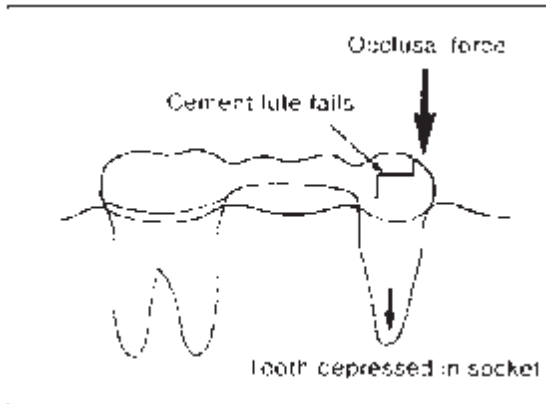
*c* Cantilever: these are the two metal–ceramic bridges made for the case shown in Figure 7.11d–h.



*d* Occlusal view of the bridges in place.



*e* Spring cantilever: the first molar tooth is the abutment tooth. There is a midline diastema, and a diastema between the lateral incisor and canine on the side of the missing central incisor. Any other bridge design would have involved closing one or both of these spaces. Today a single-tooth implant would be the preferred solution to the problem.

**Figure 8.2**

An unsatisfactory design for a fixed–fixed bridge.

A conventional fixed–fixed bridge should have all the occluding surfaces of the abutment teeth protected by the retainers. Otherwise an occlusal force directed at the unprotected area will depress the abutment tooth in its socket while the retainer is held by the bridge and the other abutment tooth. This will break down the cement lute, causing leakage. The retainer is held in place by the bridge, and so secondary caries develops rapidly (see Figure 14.8).

abutment teeth are therefore rigidly splinted together, and for a conventional bridge must be prepared parallel to each other so that the bridge, which is a minimum of three units, can be cemented in one piece. The retainers should have approximately the same retention as each other to reduce the risk that forces applied to the bridge will dislodge one retainer from its abutment, leaving the bridge suspended from the other abutment.

To minimize this risk, it is also important for the entire occluding surface of all the abutment teeth for a conventional bridge to be covered by the retainers. The opposing teeth cannot then contact the surface of an abutment tooth, depress it in its socket and break the cement lute. If this should happen, the retainer will not appear loose since it will still be held in place by the rest of the bridge.

However, oral fluids will enter the space between the retainer and the abutment preparation, and caries will rapidly develop (Figure 8.2). For example, linking a full coverage crown to a simple DO inlay would quickly result in dislodgement of the inlay with consequent caries developing underneath.

This rule does not apply so much to minimum-preparation bridges in which the bond between the retainer and the abutment tooth is much stronger. However, it is sometimes not strong enough, and debonding occurs as a result of a mechanism similar to that shown in Figure 8.2.

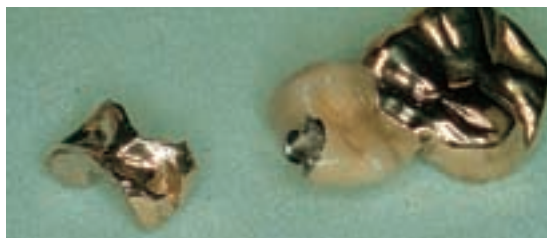The fixed–fixed design should be avoided if at all possible for minimum-preparation bridges. A number of success – and failure – surveys have shown that the cantilever design of minimum-preparation bridges with one abutment tooth is more successful with anterior bridges and a form of fixed–movable design is preferred for posterior bridges (see later).

At one time it was thought that the support for the abutment teeth at each end of a fixed–fixed conventional bridge should be similar. In other words, the root surface area of the abutments should be approximately the same. Today this is not considered necessary (see Chapter 10).

### Fixed–movable bridge

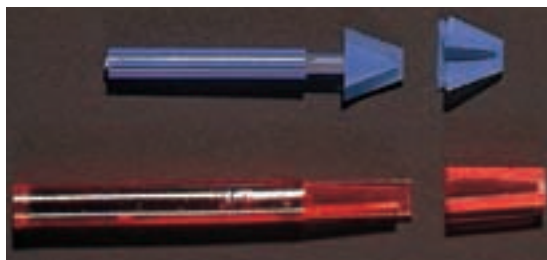
A fixed–movable conventional bridge (Figure 8.1b) has a rigid connector, usually at the distal end of the pontic, and a movable connector that allows some vertical movement of the mesial abutment tooth. The movable connector should resist both separation of the pontic from the retainer and lateral movement of the pontic (Figure 8.3a and b).

Occasionally the fixed and movable connectors are reversed, but this has a number of disadvantages. The retainer with the movable connector (the minor retainer) is smaller and less visible and so is better in the more anterior abutment tooth.

**Figure 8.3**

Fixed–movable bridges.

*a* A conventional bridge with an MOD gold inlay as the minor retainer and a full gold crown as the major retainer.

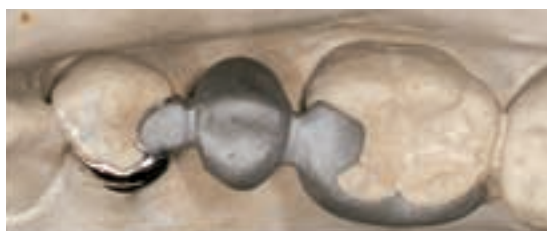

*b* Acrylic burn out patterns for movable connectors. The blue is very tapered, the red more parallel-sided.



*c* and *d* A minimum-preparation fixed–movable bridge.

*c* Shows the minor retainer in place with a depression, rather than a slot, in the distal rest. The preparations for both the major and minor retainers are within enamel.



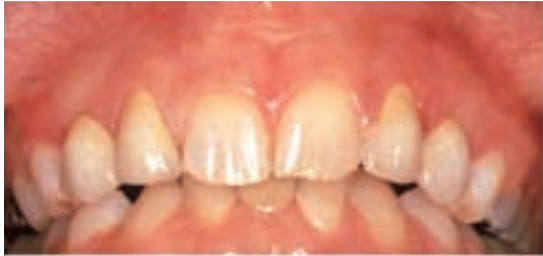*d* Shows the finger from the pontic resting on the minor retainer. This will resist axial forces on the pontic which would tend to tilt the molar abutment tooth forwards. It does not resist lateral forces but these can be made insignificant by contouring the occlusion of the pontic.

Posterior teeth commonly tilt mesially, and this tends to unseat distal movable connectors, but is resisted by mesial ones.

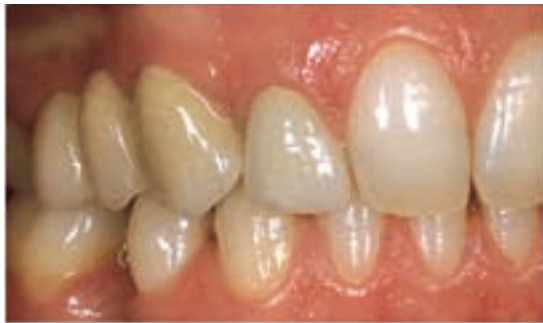The movable connector can be separated before the bridge is cemented, and so the two parts of the bridge can be cemented separately. The abutment teeth do not therefore have to be prepared parallel to each other and the retention for the minor retainer does not need to be as extensive as for the major retainer. Neither does

it need full occlusal protection. Occlusal forces applied to the tooth surface not covered by the retainer will depress the tooth in its socket, and there will be movement at the movable joint rather than rupturing of the cement lute (Figure 8.2).

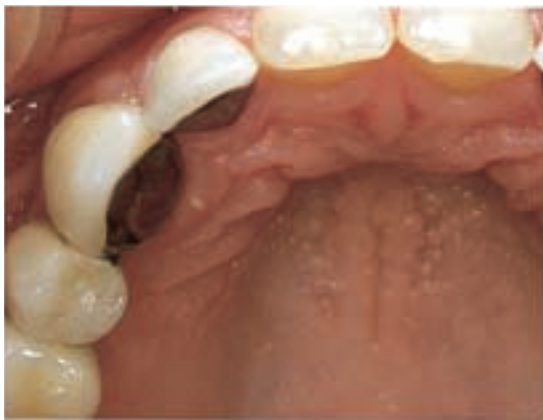A fixed–movable minimum-preparation bridge cannot have a large, dovetailed shaped movable connector (Figure 8.3a and b) without over-preparing the minor abutment tooth. Instead the

**Figure 8.4**

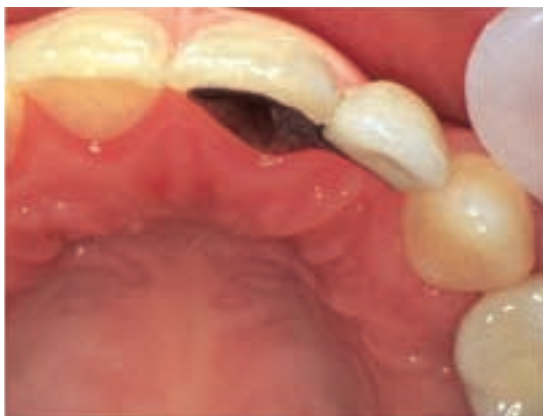*a* All-ceramic cantilever bridges. The lateral incisor teeth were congenitally missing and the deciduous canine teeth remained with good long roots. They were therefore used as abutments for these cantilever bridges until such time as the deciduous canine teeth are lost. The patient is in her early twenties and this may not be for a decade or two when implants will probably be the treatment of choice but will have to last for less time than if they were placed now.

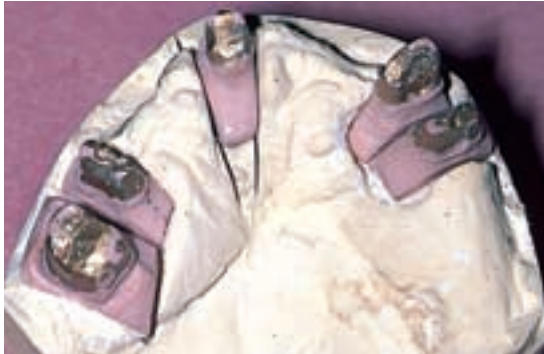

*b* and *c* A minimum-preparation cantilever bridge replacing the lateral incisor retained by the canine tooth.



*d* A similar cantilever bridge but this time retained by the central incisor tooth.

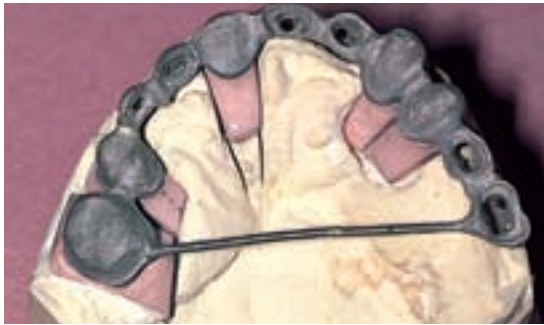



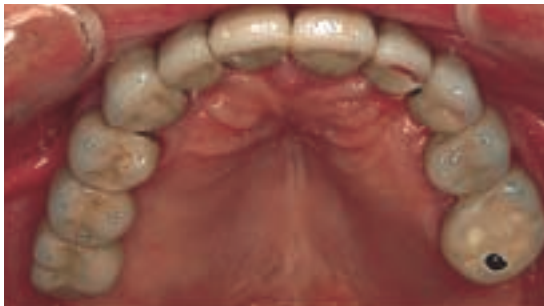**Figure 8.5**

A large splint/bridge with cantilevered pontics.

*a* The working dies.



*b* The metal framework, showing two cantilevered pontics on the right of the picture.

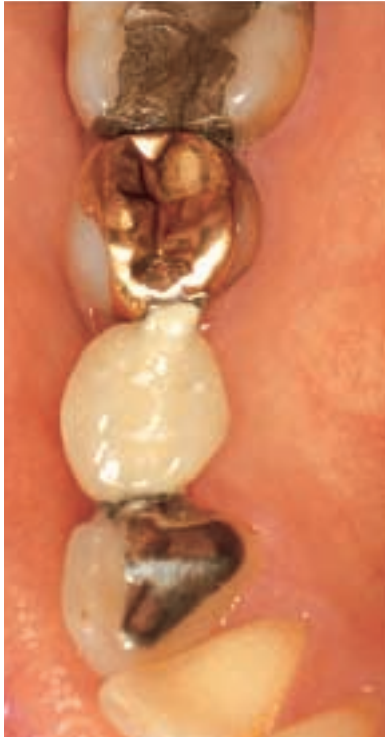


*c* The completed restoration in the mouth (photographed in a mirror so that the cantilevered pontics are shown on the left).

design, which is shown in Figure 8.3c and d, is to allow some movement of both abutment teeth, thereby reducing the risk of debonding, and to resist axial forces on the pontic. The design does not resist lateral forces on the pontic or forces tending to distract the pontic from the minor retainer. It should therefore only be used for relatively short spans in the posterior part of the mouth. However, in these circumstances it is now the preferred option.

### **Cantilever bridge**

A cantilever bridge (Figure 8.1c and d) provides support for the pontic at one end only. The pontic may be attached to a single retainer or to two or more retainers splinted together, but has no connection at the other end of the pontic. The abutment tooth or teeth for a cantilever bridge may be either mesial or distal to the span, but for small bridges they are usually distal.



**Figure 8.6**

A hybrid bridge with a conventional retainer (an inlay in the premolar tooth carrying a movable connector for a fixed–movable bridge). The other retainer on the canine is of the minimum-preparation type. Hybrid bridges should only be made fixed–movable and with the movable joint in the conventional retainer.

Two conventional cantilever bridges are shown in Figures 8.1c and d. The central incisors needed to be crowned and so a conventional rather than a minimum-preparation design was used. Also see Figure 8.4.

### Spring cantilever bridge

Spring cantilever bridges (Figure 8.1e) were restricted to the replacement of upper incisor teeth. Only one pontic could be supported by a spring cantilever bridge. This was attached to the end of a long metal arm running high into the palate and then sweeping down to a rigid connector on the palatal side of a single retainer or a pair of splinted retainers. The arm was made long and fairly thin so that it was springy, but not so thin that it would deform permanently with normal occlusal forces (i.e. exceed the elastic limit). Forces applied to the pontic were absorbed by the springiness of the arm and by displacement

of the soft tissues of the palate so that excessive leverage forces did not disturb the abutment teeth. They were made when the teeth either side of the gap were sound.

Spring cantilever bridges are no longer made and have been superseded by minimum-preparation bridges and single-tooth implants. However, a number of patients still have spring cantilever bridges and so dentists should be able to recognise them.

### Combination designs

The four basic designs can be combined in a variety of ways. In particular, the fixed–fixed and cantilever designs are often combined. In larger bridges additional cantilever pontics may be suspended from the end of a large fixed–fixed section (Figure 7.5). Similarly, it is possible to combine fixed–fixed and fixed–movable designs.

It is possible to combine a bridge or splint with a removable buccal flange that replaces lost alveolar tissue (Figure 7.8).

### Hybrid design

This term refers to a bridge with a combination of conventional and minimum-preparation retainers. There are three different hybrid designs:

- Fixed–movable with the minimum-preparation retainer carrying the movable connector.
- Fixed–movable with the conventional retainer carrying the movable connector.
- Fixed–fixed with one conventional and one minimum-preparation retainer.

The third design should **not** be used and the second only rarely. In either case, if the minimum-preparation retainer becomes debonded then it will not be possible to re-cement it without removing the conventional retainer, which may well involve destroying the bridge.

The first design is one of choice given circumstances in which one of the abutment teeth already has a restoration that could be replaced by means of an inlay or other conventional retainer and the other abutment tooth is unrestored or the restoration does not involve the surfaces to be covered by the minimum-preparation retainer (Figure 8.6). These circumstances occur surprisingly often, and so this design of bridge is now common.

### Variations

#### Removable bridges

All the designs described so far are permanently cemented in the patient's mouth. With large bridges there are disadvantages in permanent cementation in that the maintenance and further endodontic or periodontal treatment of abutment teeth is difficult, and if something goes wrong with one part of the bridge or with one of the abutment teeth, usually the whole bridge has to be sacrificed. For this reason, larger bridges, including full arch bridges, are sometimes

made so that they can be removed by the patient. The advantage of this is that cleaning around the abutment teeth and under the pontics is much easier. The bridge has to withstand handling by the patient, and so it is usually made with acrylic facings (Figure 7.2). The acrylic facings are less liable to chip if the bridge is dropped. They can also be replaced without the risk of distorting the framework as would be the case with porcelain.

### Advantages and disadvantages of the four basic designs

A comparison of conventional fixed–fixed, fixed–movable and cantilever bridges is shown on page 206. Spring cantilever bridges are not included.

A comparison of minimum-preparation fixed–fixed, fixed–movable and cantilever designs is shown on page 207.

### Choice of materials

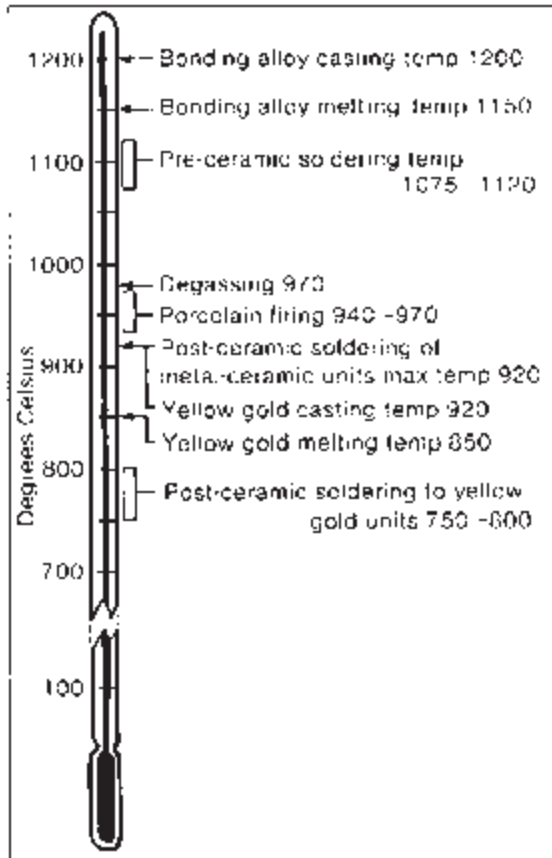
#### Metal only

Many posterior bridges, both conventional and minimum-preparation, can be made entirely of cast metal, whether they are fixed–fixed, fixed–movable or cantilever. If the retainers or pontics do not show when the patient smiles and speaks then an all-metal bridge is the best choice with conventional bridges – the material necessitates the least destruction of tooth tissue and may be the least costly. The margins are also easier to adapt to the preparations.

#### Metal–ceramic

When the strength of metal is required together with a tooth-coloured retainer or pontic, metal–ceramic is the best material.

A range of composite crown and bridge facing materials is now available, but it is too early to say whether these have an advantage over metal–ceramic materials for permanent bridges.



**Figure 8.7**

Typical temperature ranges for the metal–ceramic process. These vary according to the metal, porcelain and solder used, and with the type of furnace, in particular its rate of temperature rise.

### **Ceramic only**

The traditional all-ceramic bridge was limited by its relatively poor strength to two-unit cantilever bridges or three-unit fixed–fixed bridges but they were popular at one time and some patients still have them. With improvements in metal–ceramic materials, these all-ceramic bridges fell into disuse. However, with the development of stronger ceramic materials (see Chapter 1 and Figure 8.4), there is a resurgence of interest in all-ceramic bridges..

One advantage of the all-ceramic bridge is the ‘fuse-box’ principle (see Chapter 2). All-ceramic bridges, if properly designed and constructed, have sufficient strength to survive normal functional forces, but will break if subjected to excessive forces. This potential for fracture may save the roots of the abutment teeth from

fracturing if the bridge receives a blow. It is not uncommon for patients who lose a tooth as a result of an accident to have a further accident, either because of their occupation or sport or because, with a Class II Division I incisor relationship, their upper incisors are vulnerable to trauma. A broken bridge is better for the patient than broken roots.

### **Combinations of materials**

Many combinations are possible, but two deserve special mention:

- A metal–ceramic retainer and pontic with a movable connector to a gold inlay or other minor retainer.



## COMPARISON OF CONVENTIONAL BRIDGE DESIGN

**ADVANTAGES****Fixed-fixed**

- Robust design with maximum retention and strength
- Abutment teeth are splinted together; this may be an advantage, particularly when teeth are uncomfortably mobile following bone loss through periodontal disease
- The design is the most practical for larger bridges, particularly when there has been periodontal disease
- The construction is relatively straightforward in the laboratory because there are no movable joints to make

**Fixed-movable**

- Preparations do not need to be parallel to each other, so divergent abutment teeth can be used
- Because preparations do not need to be parallel, each preparation can be designed to be retentive independently of the other preparation(s)
- More conservative of tooth tissue because preparations for minor retainers are less destructive than preparations for major retainers
- Allows minor movements of teeth
- Parts can be cemented separately, so cementation is easy

**Cantilever**

- The most conservative design when only one abutment tooth is needed
- If one abutment tooth is used, there is no need to make preparations parallel to each other; if two or more abutment teeth are used, they are adjacent to each other, so it is easier to make the preparations parallel
- Construction in the laboratory is relatively straightforward
- Most suitable in replacing anterior teeth where, if the occlusion is favourable, there is little risk of the abutment tooth tilting.
- Easier maintenance and cleaning

**DISADVANTAGES****Fixed-fixed**

- Requires preparations to be parallel, and this may mean more tooth reduction than normal, endangering the pulp and reducing retention; the strength of the prepared tooth may also be reduced
- Preparations are difficult to carry out, particularly if several widely separated teeth are involved; the preparation is slow and the parallelism has to be constantly checked, or alternatively (and wrongly) the preparations are over-tapered to ensure that there are no undercuts and so retention is lost
- All the retainers are major retainers and require extensive, destructive preparations of the abutment teeth
- Has to be cemented in one piece, so cementation is difficult

**Fixed-movable**

- Length of span limited, particularly with mobile abutment teeth
- More complicated to construct in the laboratory than fixed-fixed
- Difficult to make temporary bridges
- The major retainer needs to be able to provide the support for pontics with longer spans

**Cantilever**

- With small bridges the length of span is limited to one pontic because of the leverage forces on the abutment teeth; if more teeth are to be replaced with a cantilever bridge, a large number of abutments widely spaced round the arch must be used
- The construction of the bridge must be rigid to avoid distortion
- Occlusal forces on the pontic of small posterior bridges encourage tilting of the abutment tooth, particularly if the abutment tooth is distal to the pontic and is already predisposed to tilting mesially.

## COMPARISON OF MINIMAL-PREPARATION BRIDGE DESIGNS

**ADVANTAGES****Fixed-fixed**

- A large retentive surface area
- A single casting and so relatively simple in the laboratory
- Can be used to retain post-orthodontic cases as well as replacing teeth

**Fixed-movable**

- Independent tooth movement is possible, particularly for the minor abutment tooth (with the movable joint). The major retainer can be designed for optimum retention, sometimes incorporating intra-coronal as well as extra-coronal elements replacing restorations
- The retention of the minor retainer need not be substantial, particularly if the movable joint consists only of a rest seated in a seat on the minor retainer. In this case there are few displacing forces on the minor retainer
- The retention of the two retainers can be very different, usually with the major retainer distally and the smaller, minor retainer attached to a premolar tooth. The retainer can be made very small, and its appearance is similar to a small amalgam restoration
- Prevents a posterior abutment tooth tilting as is sometimes the case with a cantilever bridge. The movable joint merely acts to prevent this rather than to provide any retention for the bridge

**Cantilever**

- The most conservative of all designs, usually only involving a single minimal-preparation retainer
- Ideal for replacing upper lateral incisors, using the canine tooth as the abutment, provided that the occlusion is favourable
- Suitable posteriorly when the span is short
- Easy for the patient to clean with floss passed through the contact point between the pontic and the unrestored adjacent tooth
- No need to align preparations
- Easy laboratory construction

**DISADVANTAGES****Fixed-fixed**

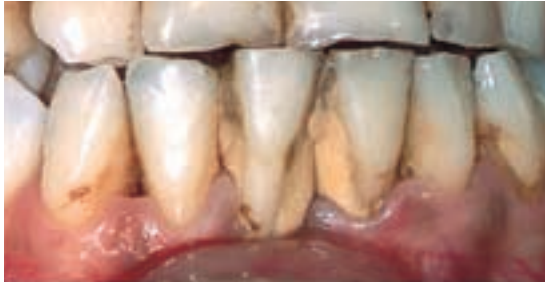- Because part of the occlusal surfaces of both abutment teeth are usually opposed by teeth in the opposing jaw, there is a tendency for them to be dislodged from the retainer, thus debonding the bridge. As the bridge will be retained there is a risk of caries developing under the failed wing
- With tilted abutments it is sometimes difficult to achieve an adequate retentive surface without substantial tooth preparation
- The retention of both retainers should be approximately equal. This is difficult to achieve when one retainer is a molar tooth and the other a premolar

**Fixed-movable**

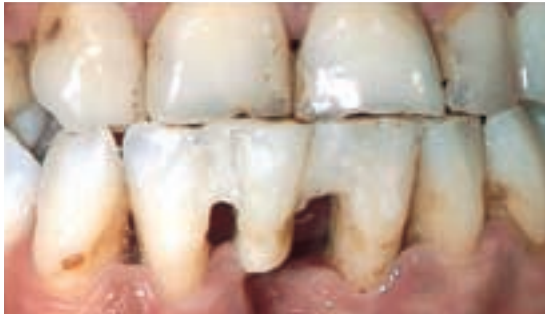- Not suitable for anterior bridges
- More difficult to make in the laboratory, requiring two separate castings
- Not suitable for longer-span bridges, where a conventional fixed-movable bridge would be satisfactory. This is because the movable joint is seldom large enough to resist lateral forces on the pontic, but will only resist axial forces by means of the rest on the minor retainer

**Cantilever**

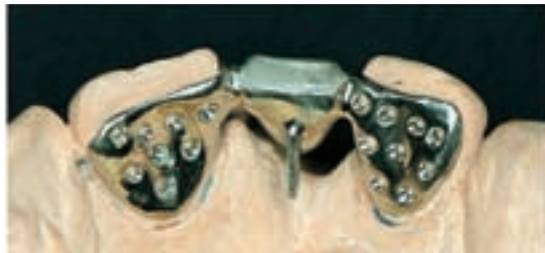- Relatively small retentive area, and vulnerable to debonding through torquing forces
- Seating of the bridge may be difficult to ensure on cementation as there may be little guidance from the tooth preparation

**Figure 8.8**

*a* This patient presented with periodontal disease and gross calculus. As an initial phase in his treatment, following removal of the calculus, the mobile lower incisor was splinted to the adjacent teeth with acid-etch retained composite. However:



*b* it was decided that the prognosis was hopeless and the root was resected. This simple and very cost-effective treatment kept the appearance reasonable while periodontal treatment continued and the socket healed. It also kept the longer-term replacement options open.

**Figure 8.9**

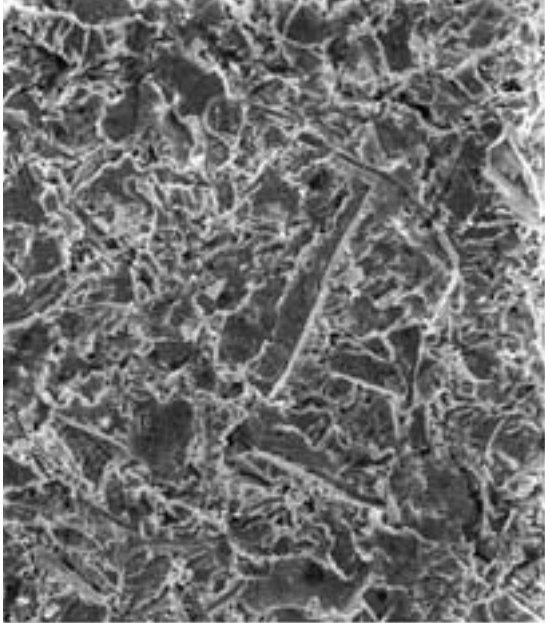
A Rochette bridge replacing one central incisor. The porcelain or composite facing is yet to be added to the pontic. The palatal spur is a handle which will be removed in due course. Conventional composite is often used as a luting cement as it is stiff enough to fill the holes. This design is still used for provisional splints and bridges because it is less traumatic to remove. The composite is drilled out of the holes to release the retention.

- An all-metal retainer (a crown or minimum-preparation retainer) towards the posterior end of the bridge with anterior metal-ceramic units.

An example is where a complete all-metal retainer would be ideal for a posterior abutment to conserve tooth tissue but the pontics will be visible and need to be of metal-ceramic material. If the design is fixed-moveable with the moveable joint mesially then the all-metal molar retainer will need to be soldered or laser welded to the metal ceramic pontics. Preparing the molar

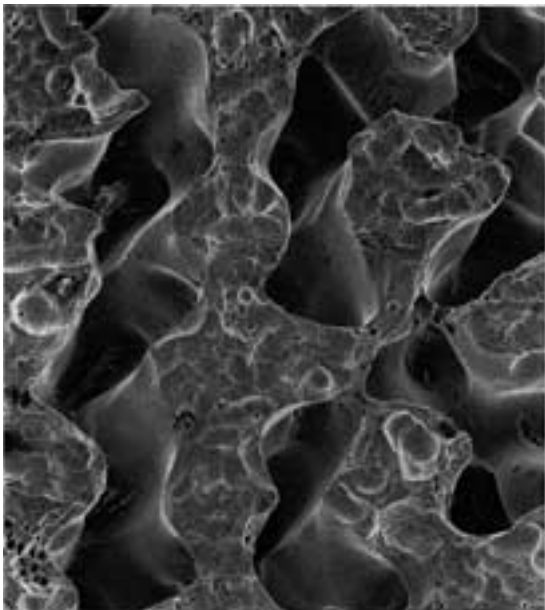
abutment for a metal-ceramic crown would be simple and would not require soldering but it would be more destructive. Alternatively, the all-metal retainer can be cast in metal-ceramic material so the whole casting can be in one piece.

The solder joint is made in a low-fusing solder after the porcelain has been added, and the bridge cannot be returned to the furnace for further adjustments to the porcelain after it has been made. Figure 8.7 shows the range of temperatures of the various components in the metal-ceramic system.



**Figure 8.10**

*a* A scanning electron micrograph (SEM) of a cast nickel–chromium metal surface grit-blasted with 50 mm aluminium oxide particles. The surface has no physical undercuts but is irregular. This is the recommended metal finish for the chemically adhesive cementing resins.



*b* An SEM of a cast nickel–chromium metal surface etched in the laboratory (the Maryland technique). The surface is very retentive but delicate.

### Types of minimum-preparation bridge

- **Direct bridges** (Figure 8.8). These may be made using the crown of the patient's own

tooth. This can often be done as a simple and rapid way of replacing a tooth lost through injury (which cannot be reimplanted) or which has to be extracted urgently. Sometimes metal mesh or wire is added to the lingual surface to

increase strength, but this is not always necessary. If the natural crown of the tooth is not available or is not suitable, an acrylic denture tooth can be used in the same way.

- **Macro-mechanically retentive bridges.** The earliest version of the minimum-preparation bridge was known as the 'Rochette bridge' after its developer who, in fact, developed the technique for periodontal splinting. They are still sometimes used for this purpose because they are less retentive than newer types of minimum-preparation bridge and so can be removed more readily. In other words they are used for provisional restorations and no longer made for permanent use. They have large undercut perforations through the cast metal plate, through which the luting composite flows. These holes are cut in the wax or acrylic pattern with a bur and are then countersunk (Figure 8.9).  
From the time of Rochette to the present day there have been a series of techniques developed. The best known of these was the 'Maryland' technique (developed at the University of Maryland) involving etching the non-precious metal surface either electronically or with hydrofluoric acid. These techniques have now been superseded. The term 'Maryland bridge' should therefore not be used as it is inaccurate for the modern type of minimum-preparation bridge.
- **Chemically adhesive (resin-retained) bridges.** With current techniques the non-precious metal surface is simply grit-blasted (sandblasted), preferably immediately before bonding (Figure 8.10a). A comparison with the etched (Maryland) metal surface, at the same magnification is shown in Figure 8.10b. The chemically active resin cement chemically bonds to the metal and the resin component micro-mechanically bonds to the roughened metal and the etched enamel surface.

### **Advantages of minimum-preparation bridges in general**

- The pulp is not put at risk from the preparation.
- The technique is mostly reversible and if the bridge eventually fails it is possible to proceed with alternative ways of replacing the missing tooth.
- Temporary restorations are not required.
- The technique is generally less expensive than conventional bridges.

### **Disadvantages of minimum-preparation bridges in general**

- As the metal plate is added to the surface of the tooth or only replaces part of it, the thickness of the tooth is increased, and may (for example in a normal Class I incisor relationship) interfere with the occlusion unless space is created orthodontically or by grinding the opposing teeth (see Chapter 11).
- The margin of the retainer inevitably produces a ledge where plaque can collect. This is a problem, especially in the replacement of lower incisors. Here plaque and calculus deposits are common on the lingual surface towards the gingival margin, and the presence of such a ledge can only make it more difficult for the patient to clean in this area.
- It is difficult to predict the longevity of minimum preparation bridges and clinical studies generally agree that although success rates are improving, in some patients their outcome is poor. Patients can be provided with spare dentures in case the bridge should become dislodged. Minimum preparation bridges can usually be re-cemented if they de-bond but patients will understandably lose faith in the bridge if this should happen regularly and alternative treatment should be considered.

## 9

# Components of bridges: retainers, pontics and connectors

Each part of the bridge should be designed individually, but within the context of the overall design. This chapter should therefore be read in conjunction with the next, since in practice the two processes – designing the bridge and its components – are done together, although it is clearer to describe them separately.

## Retainers

### Major or minor

As described in Chapter 8, all fixed–fixed and cantilever bridges have only major retainers. Fixed–movable bridges have a major retainer at one end of the pontic and a minor retainer (carrying the movable joint) at the other.

Major retainer preparations must be retentive and, with conventional bridges, must cover the whole occluding surface of the tooth. It is important to recognise the difference between the occluding and the occlusal surface.

**A major retainer** for a conventional posterior bridge should not be less than an MOD inlay with full occlusal protection. For incisor teeth it is usually a complete crown.

**Minor retainers** do not need full occlusal protection: a minor retainer may be a complete or partial crown, or a two- or three-surface inlay without full occlusal protection (Figures 8.1b and 8.3). Minimum-preparation minor retainers are also used for minimum-preparation bridges

where the occlusion is favourable (Figure 8.3c and d).

### Complete crown (full crown), partial crown, intracoronal or minimum-preparation retainers?

The choice between complete and partial crown retainers for posterior conventional bridges should always be considered and will depend upon a full assessment of all the circumstances of the case. It should not be made from habit. It will be found that even after a full assessment, 80–90% of conventional bridge retainers will be full crowns, but for the remaining 10–20% there are sound reasons for choosing a partial crown. (See Chapter 2 for a comparison of complete and partial crowns.)

Intracoronal retainers are used only as minor retainers except for very retentive MOD protected cusp inlays/onlays.

With the reduction in caries and with a more conservative approach to cavity preparation, an increasing number of potential abutment teeth have sufficient enamel available for minimum-preparation retainers to be considered. When this is so, they are usually the retainers of choice, provided that the other conditions for their use are met (see later). This is because they are the most conservative retainers, and it is wise to preserve as much natural tooth tissue as possible.

When an anterior tooth is intact a minimum-preparation retainer is more conservative of tooth tissue than a complete crown, and so is the preferred choice whenever possible.

## Materials

Minimum-preparation retainers are usually made in base metal alloys because they are strong in thin sections and they bond well to adhesive luting resins when they are freshly grit-blasted. Of the conventional retainers, an all-metal retainer is the most conservative of tooth tissue, and the simplest and usually the least expensive to produce. When appearance permits, this should be used in the posterior part of the mouth. In the anterior part of the mouth metal–ceramic is the most suitable material.

## Criteria for choosing a suitable retainer

In some cases the type of retainer will be obvious. For example, if a root-filled tooth that already has a post crown is to be used as a bridge abutment, there is little choice but to use another post-retained crown, whether as a major or minor retainer. In other cases, the full range of choice is available, and the decision on the type of retainer cannot be divorced from the decisions on the overall design and which abutment teeth to use. These three sets of considerations are dealt with separately (in Chapters 8, 10 and here), but in reality the decision-making process is not so clear-cut, and thoughts on possible abutment teeth, retainers and the overall design intermingle in the operator's mind and influence each other until a final decision on all three emerges.

The criteria for selecting a particular retainer will include:

- Appearance
- Condition of abutment teeth
- Conservation of tooth
- Alignment of abutment teeth and retention tissue
- Occlusion
- Cost

## Appearance

In some cases a complete crown will have a better appearance than a minimum-preparation retainer. Sometimes neither will be completely satisfactory.

Figure 9.1b shows an example of where a distal-palatal inlay would produce the best appearance. Figure 9.1c also shows an example of 'metal shine-through', which sometimes occurs with minimum-preparation retainers.

When several teeth are to be crowned or replaced as pontics, there is an aesthetic advantage to the bridge retainers and pontics being made in the same material (usually metal–ceramic), giving consistency of appearance.

## The condition of the abutment tooth

Frequently a minimum-preparation or partial crown retainer cannot be used because of the presence of caries or large restorations involving the buccal surface, or because of the loss of the buccal surface from trauma or other cause. In these cases a complete crown retainer is chosen.

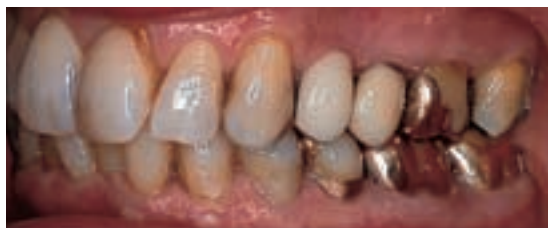## Conservation of tooth tissue

There is a natural reluctance to remove sound buccal enamel and dentine from a healthy intact tooth. This weakens the tooth, destroys its natural appearance and sometimes endangers the pulp. Therefore minimum-preparation retainers should be used whenever possible. However, if there are sound indications for a complete crown, the operator should not allow his or her clinical judgement to be influenced by an overprotective attitude to dental enamel.

## Alignment of abutment teeth and retention

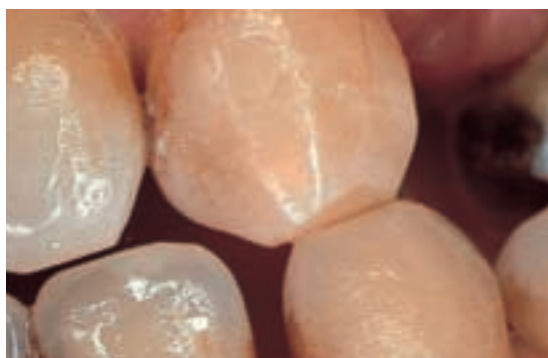When the abutment teeth are more or less parallel to each other and a fixed–fixed conventional bridge is being considered, complete crown retainers can be made. If the abutment teeth are not parallel (Figure 9.2), complete crown retainers with a common path of insertion are not feasible. They could not be made independently retentive without one or other of the teeth being devitalized.

The solution will usually be to employ a minimum-preparation bridge or a design other than fixed–fixed so that the teeth do not have to be prepared parallel to each other.

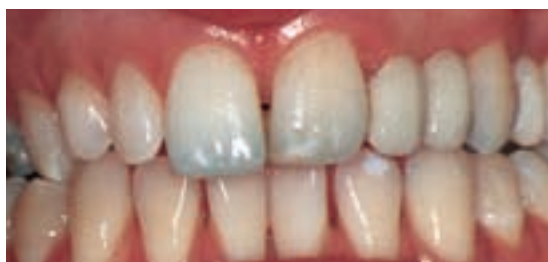**Figure 9.1**

The appearance of retainers.

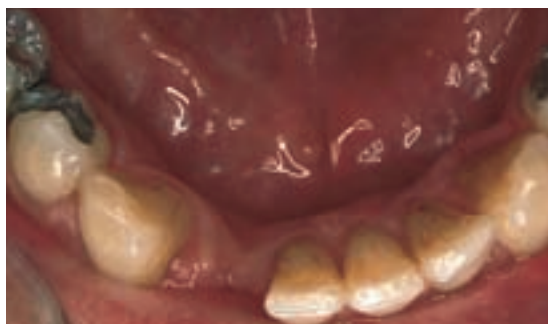*a* The canine tooth has a partial crown retainer that is barely visible from the front. The bridge has been present for many years.



*b* The upper canine tooth has an extensive incisal wear facet and pronounced buccal striae. The buccal surface would be difficult to reproduce in porcelain if a complete crown retainer were used and the occlusion was unfavourable for a minimum-preparation bridge. The design of the bridge in this case was therefore fixed–movable with a distal-palatal gold inlay in the canine tooth. An implant could also be considered.



*c* The upper central incisors both have minimum-preparation retainers. Blue 'metal shine-through' can be seen. The incisal edge of the upper left central incisor has been restored with composite, which is beginning to lose its polish. 'Metal shine-through' can be reduced by finishing the retainer short of the incisal edge, but this also reduces its retention. The problem can be minimized by using opaque luting cements.

**Figure 9.2**

Non-parallel abutment teeth. It would not be possible to make a conventional fixed–fixed bridge with complete crowns on the central incisor and canine, although it would be possible to make a minimum-preparation bridge. As the canine and central incisors are all intact the design of choice would be two separate minimum-preparation cantilever bridges; one retained by the canine and the other retained by the two central incisors splinted together, or perhaps just one central incisor depending on the occlusion and periodontal health. This would be comparable to the bridges shown in Figure 7.1c and d.



It is impossible to give in absolute terms the amount of retention necessary for any one retainer. It is reasonable to assume that the retention for a bridge retainer should be at least as great as for a similar restoration made as a single unit.

### Occlusion

In some cases the abutment teeth are sound but there is insufficient space for a minimum-preparation retainer. The choice therefore is between creating space by reducing the opposing teeth, preparing part way through the enamel of the abutment teeth, moving the abutment teeth orthodontically or a combination of these approaches. Often the best way to achieve a small amount of axial tooth movement is to use a fixed Dahl appliance (Figure 4.6). If none of these methods are acceptable then a conventional retainer will be necessary.

### Cost

Complete metal crowns and partial crowns may be less expensive than metal–ceramic crowns (see Chapter 2), and minimum-preparation retainers are the least expensive. When there are no other overriding factors affecting the choice, this is obviously important.

## Pontics

### Principles of design

Pontics are designed to serve the three main functions of a bridge:

- To restore the appearance
- To stabilize the occlusion
- To improve masticatory function.

In different areas of the mouth the relative importance of these will alter. The principles guiding the design of the pontic are:

- Cleansability
- Appearance
- Strength.

The compromise often necessary between cleansability and appearance will also vary in different parts of the mouth.

### Cleansability

All surfaces of the pontic, especially the surface adjacent to the saddle, should be made as cleansable as possible. This means that they must be smooth and highly polished or glazed, and should not contain any junctions between different materials. In a metal–ceramic pontic the junction between the two materials should be well away from the ridge surface of the pontic.

It is important too that the embrasure spaces and connectors should be smooth and cleansable. They should also be as easy to clean as possible. Access to them and the patient's dexterity should be taken into account in designing pontics.

When a conflict exists between cleansability and appearance, priority should be given to cleansability.

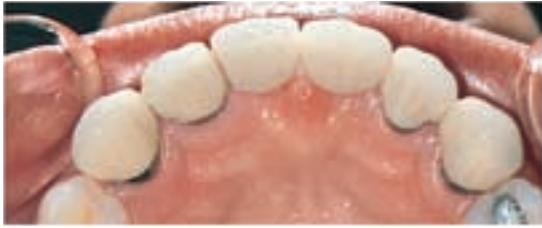### Appearance

Where the full length of the pontic is visible, it must look as tooth-like as possible. However, in the premolar and first molar region it is often possible to strike a happy compromise between a reasonable appearance for those parts of the pontic that are visible and good access for cleaning towards the ridge.

### Strength

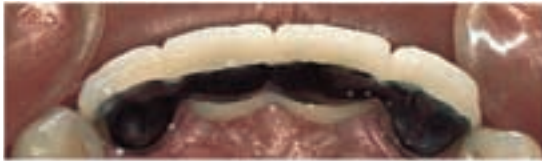All pontics should be designed to withstand occlusal forces, but porcelain pontics in the anterior part of the mouth may not of course be expected to withstand accidental traumatic forces.

The longer the span, the greater the occlusal gingival thickness of the pontic should be. Metal–ceramic pontics are stiffer and withstand occlusal forces better if they are made fairly thick and if the porcelain is carried right round them from the occlusal to the ridge surface, leaving only a line of metal visible on the lingual surface or none at all (Figure 9.3a and b).

**Figure 9.3**

The strength of metal–ceramic pontics.

*a* The central incisor pontics in this case have no metal visible on the palatal surface.



*b* When the palatal reduction of the abutment teeth is only sufficient for a layer of metal, this is often carried along the pontics as well, leaving an occluding surface entirely in metal. The porcelain, however, is carried right under the pontics so that only porcelain contacts the ridge.

### ***The surfaces of a pontic***

A pontic has five surfaces:

- The ridge
- The occlusal
- The approximal
- The buccal or labial
- The lingual or palatal.

Some of these will be similar to the natural tooth being replaced; others will be very different.

### ***The ridge surface***

This surface of the pontic is the most difficult to clean, and yet it also has a considerable influence on appearance. There are four basic designs of ridge surface (Figures 9.4 and 9.5).

#### **Wash-through** (Figure 9.4a)

Other terms used for this type of pontic are hygienic and sanitary, but the term wash-through is more descriptive and less suggestive of vitreous china bathroom fittings. The wash-through pontic makes no contact with the soft tissues and so is the easiest to clean. It is used where a pontic

is required for functional purposes rather than appearance and is most useful in the lower molar region.

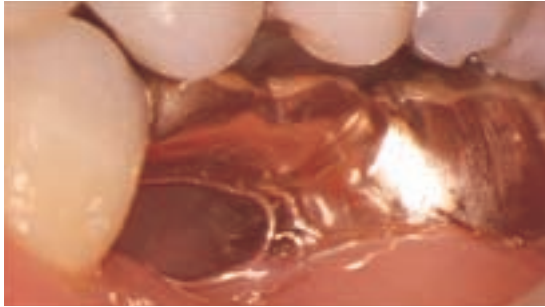
#### **Dome-shaped** (Figure 9.4b and c)

This is the next easiest to clean and is used where the occlusal two-thirds or so of the buccal surface of the pontic show, but not the gingival third. It is commonly used in the lower incisor and premolar regions and sometimes in the upper molar region.

This has also been described as torpedo-shaped or bullet-shaped, but the less aggressive term, dome-shaped, is preferred.

#### **Ridge-lap and modified ridge-lap** (Figure 9.4d, e and f)

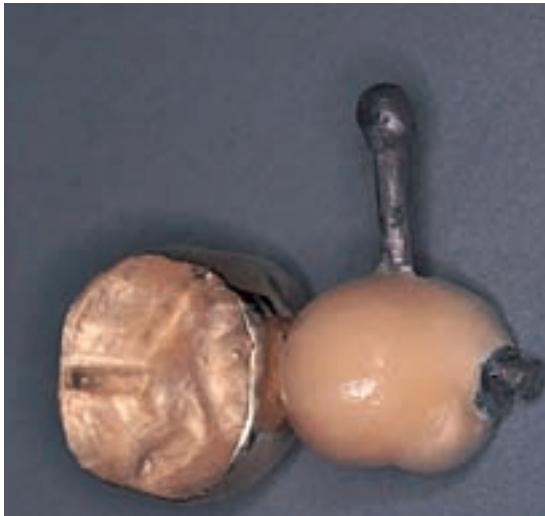The principles of this design are that the buccal surface should look as much like a tooth as possible right up to the ridge, but the lingual surface should be cut away to provide access for cleaning. Ideally the pontic should have a completely convex lingual surface, making only a line contact along the buccal side of the ridge. However, this is often impractical because of the shape of the ridge, and so the modified ridge-lap pontic, which has minimum contact with the ridge from the



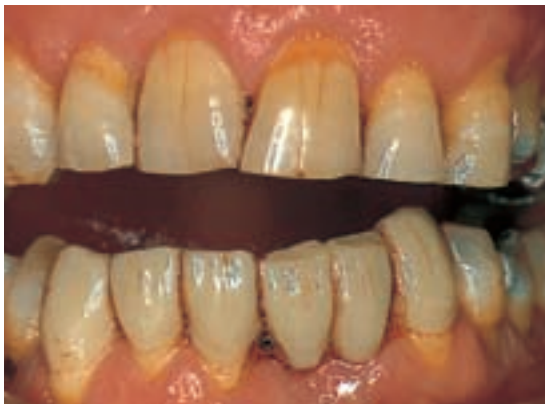**Figure 9.4**

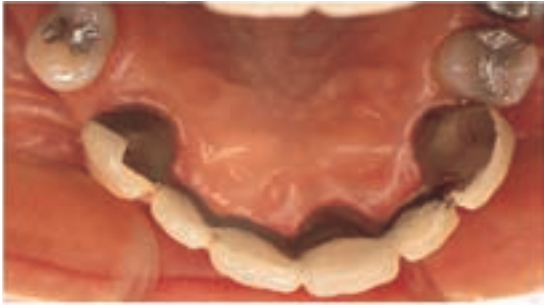
The four designs of pontic ridge surface.

*a* A wash-through pontic with a concave mesio-distal contour.

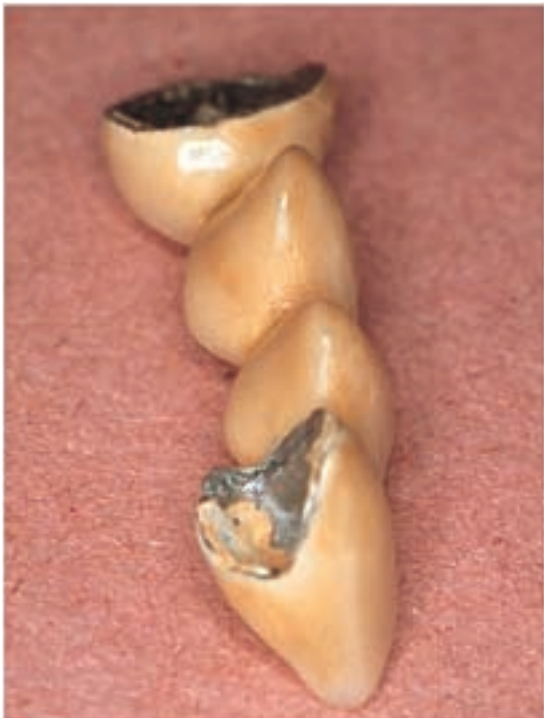
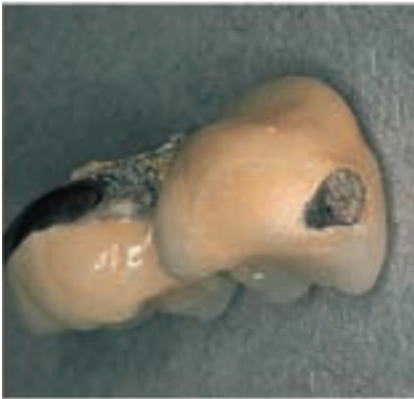
*b* and *c* Dome-shaped pontics. *b* A molar dome-shaped pontic with the male part of a movable connector and a lingual handle which will be removed after the bridge is tried in. *c* An acrylic provisional bridge fitted as an immediate replacement for the lower left central and lateral incisors, showing an application of the dome-shaped pontic.

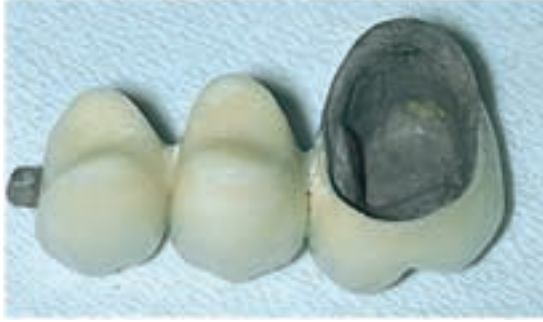



*d* and *e* Ridge-lap pontics. *d* This bridge has been satisfactory, but the patient complains of food impaction under the single lateral incisor pontic. She can sweep the other side clean with her tongue since the span is longer. *e* A modified ridge-lap pontic with contact over the buccal half of the ridge but cut away lingually. The bridge has failed because of a fractured solder joint (see Chapter 14).



*f* Typical ridge-lap pontics on another failed bridge. This time the failure was due to loss of retention. Despite the design and the smooth porcelain surface, the ridge beneath these pontics was moderately inflamed.



g Saddle-shaped pontics with well-contoured, cleansable connectors

point of contact on the buccal side up the crest, is often used (Figure 9.4e).

These designs, particularly if the pontic is fairly narrow mesio-distally, as in the case of an incisor or premolar pontic, are sometimes unpopular with patients because they find that food impacts into the space on the lingual side and cannot be readily removed with the tongue (Figure 9.4d). Besides, considerable manual dexterity is needed to manoeuvre dental floss, tape or other cleaning aid, holding it first against the pontic and then in a secondary cleaning movement against the ridge (Figure 9.5).

These pontics were designed at a time when there was a lot of concern about the effect of pontics on the soft tissues but before the significance and nature of plaque were as well understood as they are today. They are still commonly used, perhaps through habit and convention. Other designs should also be considered and are often better.

### Saddle


The saddle pontic is so named because of its shape. It has by far the largest area of surface contact with soft tissue, and so, although it was popular in the early days of bridgework, it became much less so as dentists became more concerned about the effects of pontics on ridges. Now that it is recognised that plaque can cause inflammation however small the surface area of

contact and must be removed in all cases, the emphasis in pontic design has shifted. Accessibility for cleaning and patient comfort and convenience are the important criteria, rather than the size of area of contact. Many patients prefer the saddle-shaped pontic since the lingual surface feels more like a tooth than any other design. With modern cleaning aids, such as superfloss, the ridge surface of properly designed and constructed saddle pontics is relatively easy to clean. This also requires less manual dexterity by the patient than ridge-lap pontics (Figure 9.5d).

A saddle pontic should closely follow the contour of the ridge but should be smooth on the under surface. It should not displace the soft tissues or cause blanching when it is inserted, but should make snug contact.

### *The effects of pontics on the ridge*

Sometimes when bridges are removed the area of the ridge that was in contact with the pontic has a red appearance. Biopsy studies have shown that there are always some chronic inflammatory cells in this region, but the main explanation for the redness is probably the reduction in keratinization. The surface does not have the normal stimulation from food and the tongue that stimulates keratinization elsewhere. Unless clearly inflamed or ulcerated, the redness is of little clinical consequence (Figure 9.6).



**Figure 9.5**

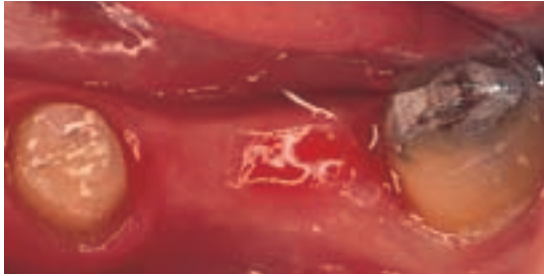
Four sectioned casts of the same patient, showing the profile of the midpoint of a lower molar edentulous area where a bridge is to be made. The profiles of four pontics are shown.

*a* A wash-through pontic with no contact with the ridge – very cleansable but poor appearance.

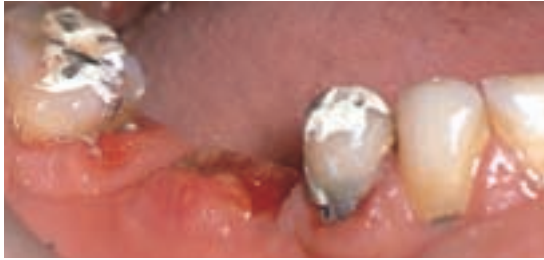*b* A dome pontic making point contact on the tip of the ridge – still cleansable and with a better appearance buccally towards the occlusal surface.

*c* A partly modified ridge-lap pontic with a buccal surface resembling a natural tooth but with minimum ridge contact. The difficulty of cleaning the lingual aspect near the ridge is obvious.

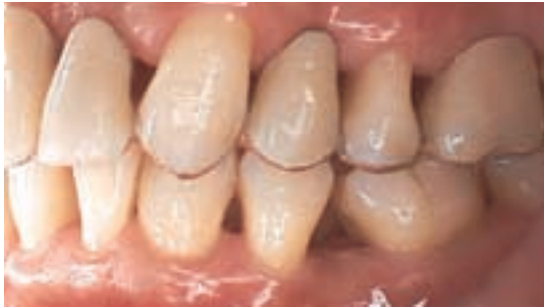*d* A full saddle pontic that, if well polished or glazed on the gingival surface, would be cleansable with superfloss. This design has the best appearance and feels more natural to the tongue.

**Figure 9.6**

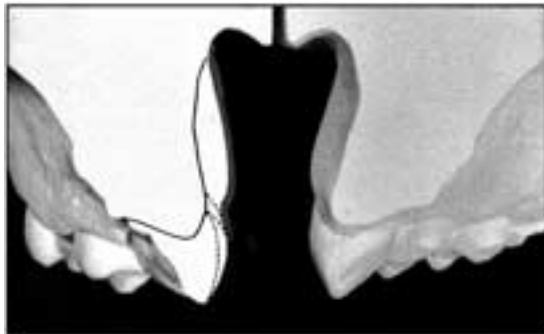
*a* Mucous membrane reactions under pontics. This area of reduced keratinization under a pontic produced no symptoms. There was no ulceration or bleeding on flossing under the pontic. Although inflammation requiring treatment at the gingival margin of the abutment teeth is present, it is doubtful whether the changes in the remainder of the ridge have had any real significance.



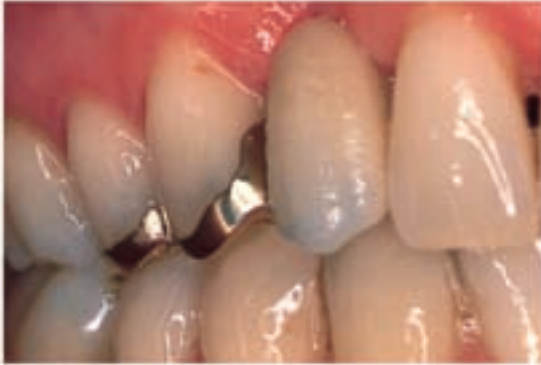*b* A much more serious case, with ulceration and a very inflamed mass of granulation tissue. This must clearly be treated in the first place by removal of the bridge. In fact no further treatment was necessary. The inflammation resolved over a 3-week period.

**Figure 9.7**

Well-contoured open embrasure spaces.

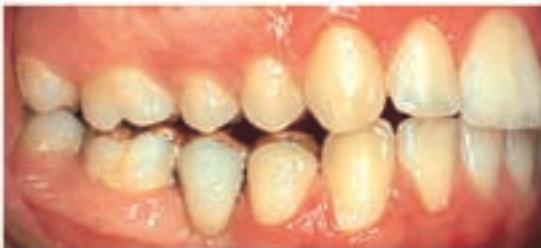**Figure 9.8**

Sections through both the lateral incisor areas of the same patient. *Left:* the lateral incisor is present. *Right:* it is missing and the alveolus has resorbed. The profile of the resorbed side has been superimposed on the other to show the extent of the resorption and three ways in which a pontic might be modified to overcome this problem.

**Figure 9.9**

Buccal pontic–ridge relationships.

*a* A pontic replacing an upper canine, where the neck of the pontic has been curved inwards to meet the resorbed alveolar ridge at the correct vertical position. The incisal two-thirds of the buccal surface have been contoured in line with the adjacent teeth so that all the compensation for the missing alveolar bone is in the gingival buccal third. (Note the excessive amount of gold shown by these two partial crowns, in contrast with those in Figure 9.7.)



*b* The same compromise has not been made with this lower premolar pontic, which instead looks too long. This would also create difficulty in cleaning under the pontic.

### **The occlusal surface**

The occlusal surface of the pontic should resemble the occlusal surface of the tooth it replaces. Otherwise it will not serve the same occlusal functions and may not provide sufficient contacts to stabilize the occlusal relationships of its opponents.

In some cases, when occlusal stability is less important (for example when the pontic is opposed by another bridge), the pontic may be made narrower bucco-lingually to improve access for cleaning. Other arguments for narrowing pontics are less convincing (see Chapter 10).

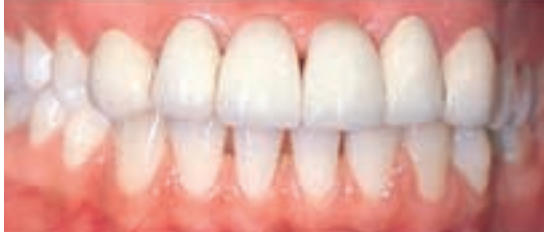### **The approximal surfaces**

The shape of the mesial and distal surfaces of the pontic will depend upon the design. With fixed–fixed bridges the approximal surface will consist partly of a fixed connector. It is important that the embrasure space between the

connector and the gingival tissue be as open as possible to ensure that there is good access for cleaning, particularly if the pontic is a ridge-lap or saddle pontic (Figure 9.7). The gingival side of a movable joint is more difficult to leave entirely smooth, and so it is again important that there should be good access for cleaning. A balance has to be achieved to ensure that there is adequate metal present to provide sufficient strength and rigidity for the connector as well as allowing open embrasures for cleaning.

The approximal surface of a cantilever bridge on its free side will simply make normal contact with the adjacent tooth, or in some cases there may be a diastema with no contact. Occasionally, where the span is very short, a cantilever pontic may be made to overlap the adjacent tooth to improve its appearance. In this case the pontic surface in contact with the natural tooth should be as smooth as possible, although it may be slightly concave. If the patient is taught to clean with dental floss, the natural tooth surface should not be any more susceptible to caries than with a normal contact point.





**Figure 9.10**

An acceptable appearance for a bridge – or is there more than one bridge?

### ***The buccal and lingual surfaces***

The buccal surface of a wash-through or dome-shaped pontic does not resemble the shape of a natural buccal surface, particularly gingivally. With ridge-lap and saddle pontics the buccal surface is intended to look as much like a tooth as possible for its entire length. The problem is that when a tooth is missing, so also is some of the alveolar bone that supported it. This means that the alveolar contour where the pontic touches the ridge never looks entirely natural, and the pontic must also be shaped unnaturally to meet the resorbed ridge. Figure 9.8 shows, by means of sections through a study cast, how the ridge contour in a resorbed saddle area necessitates a compromise pontic appearance. Figure 9.9a shows an example of this where an upper canine is missing. Figure 9.9b also shows an example of a case in which this compromise has not been made. The aesthetic result is not good and there is greater difficulty than necessary in cleaning.

No ridge–pontic relationship can ever appear entirely natural, even when the ridge has not resorbed significantly or where it has been augmented – see Figure 7.9. But at the normal distance from which teeth are seen, the illusion that the tooth emerges from the gum can be sufficiently convincing: which are the pontics and which are the retainers in Figure 9.10?

The lingual surface of a pontic will be designed as a result of deciding the ridge surface. With ridge-lap pontics, the lingual surface should be smooth and convex.

### ***Materials***

The choice for pontics is the same as for retainers. At one time there was also the choice of a

number of proprietary pontic facings. These have not been used for many years but some patients, with long-standing bridges, still have proprietary pontic facings. They are easy to recognise in contrast to metal–ceramic pontics.

## **Connectors**

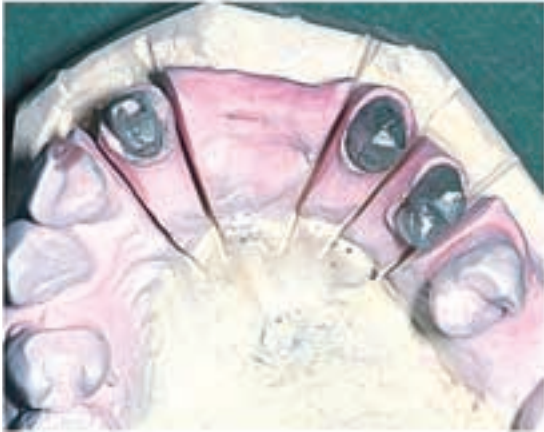### ***Fixed connectors***

There are three types of fixed connector:

- Cast
- Soldered or laser welded
- Porcelain.

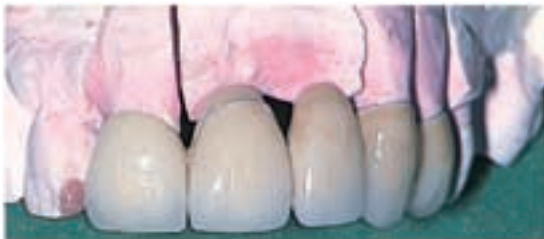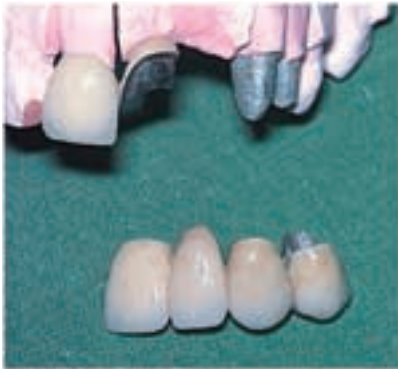**Cast connectors** are made by wax patterns of the retainers and pontics connected by wax being produced so that the bridge is cast in a single piece. This has the advantage that a second soldering operation is not required. But the more units there are in the bridge, the more accurate the casting must be. Minor discrepancies in the compensation for the contraction of molten metal that may be acceptable for single-unit casting become unacceptable when magnified several times.

Cast connectors are stronger than soldered connectors, and also it is sometimes possible to disguise their appearance more effectively. For these reasons, multiple-unit bridges are often cast in several sections of three or four units divided through the middle of a pontic. The split pontics are then soldered with high-fusing solder before the porcelain is added, so that all the connectors are cast. The solder joint produced in this way is strong both because it has a larger surface area than if it were at the connector and because it is

**Figure 9.11**

Creating a fixed-fixed design with non-parallel abutments.

*a* The central incisor could not be retracted sufficiently to be parallel to the other abutment teeth even if devitalized and with a post and core fitted. It would interfere with the occlusion.



*b* and *c* The bridge is made in two parts with separate paths of insertion, and the divided pontic connected in the mouth by cement and a screw attachment.

covered by porcelain, stiffening it. Laser welding is an increasingly popular way of linking components of bridges together. The welds achieved are stronger than soldering and the technique is quick and simple, although the equipment required is complex and expensive.

**Soldered or laser welded connectors** are used if the pontics and retainers have to be made

separately. This is necessary when they are made of different materials, for example a complete gold crown retainer with a metal-ceramic pontic.

**Porcelain connectors** are used only in conjunction with all-porcelain bridges. The details of their construction are beyond the scope of this book, but the same principles of accessibility and cleanliness still apply.

### **Movable connectors**

Movable connectors are always designed so that the pontic cannot be depressed by occlusal forces. This means that the groove or depression in the minor retainer must always have a good base against which the male part of the attachment can seat. Sometimes, with small pontics and short spans, this is the only force that needs to be resisted, and therefore the female part of the attachment, in the minor retainer, need only be a shallow depression (Figure 8.3c). This is the commonest design for fixed–movable minimum-preparation bridges.

However, with longer-span bridges the movable joint must also resist lateral forces applied to the pontic and (assuming the movable joint is mesial) distal forces on the pontic, which would separate the components of the movable connector. In these circumstances the connector is designed as a tapered dovetail-shaped slot so that the pin can move up and down a little and yet seat firmly against the base of the slot, but it cannot move laterally and the connector cannot separate. Examples of this type of connector are shown in Figure 8.3.

There are different ways of producing movable connectors. In the freehand method a wax pattern is produced for the minor retainer with a shallow depression or tapered groove prepared

in the wax, the retainer is cast and with a groove, the shape is refined with a tapered bur. The pontic is then waxed-up with a finger or ridge to fit into the depression or groove. This is cast and the two parts of the movable joint are fitted together before the bridge is taken to the chair side for trying in (Figure 8.3a).

In some cases a depression or groove may be prepared in an existing cast restoration in the mouth and an impression taken of it together with the other prepared abutment tooth or teeth.

Acrylic burn out patterns are available that may be incorporated into the pontic and minor retainer so that the whole bridge can be waxed-up in one operation and the minor retainer and remainder of the bridge invested and cast separately (Figure 8.3b, page 200).

Proprietary groove-and-ridge precision attachments in metal may also be used as movable connectors, but are generally too retentive and there is the risk that they will not permit sufficient movement. When precision attachments are used, the minor retainer should have more retention to its abutment than would be necessary if a less retentive connector were used.

Screw precision attachment connectors may be used to produce a fixed–fixed bridge by connecting two retainers that cannot be prepared parallel to each other (Figure 9.11).

## 10

# Designing and planning bridges

## Criteria for selecting a bridge design

No firm rules can be given for selecting any particular design. Bridge design is complex, poorly researched and dominated by personal opinion derived from clinical experience, or lack of it. Many of the ground rules of bridge design were laid down in the early part of the last century by teachers who were trying to rescue the subject from the purely empirical approach used until that time. Although they were a major advance on what had gone before, these ground rules were not scientifically investigated. Yet they became accepted as irrefutable and remained relatively unaltered for over 50 years, despite a growing understanding in that time of related subjects such as the supporting structures of teeth in health and disease, and of occlusion and jaw function. In the last two decades, great developments have been made in restorative materials and techniques, so that bridges now fit better, look better and are stronger. This increased understanding and technical development should affect traditional ideas of design to a considerable degree.

Clinical (and some research) evidence suggests that many of the early rules of bridge design should no longer be applied. However, this evidence is not yet sufficiently clear-cut for new, firm rules to be established, leaving today's dentists, including the authors, still having to make clinical decisions about bridge designs based on an incomplete 'evidence base'.

A number of criteria may nevertheless be used in choosing a design, although the weight given to each will vary with the circumstances and the opinions held by the operator. It is to be hoped that with further clinical research (which is urgently needed) the relative importance of these criteria will become clearer.

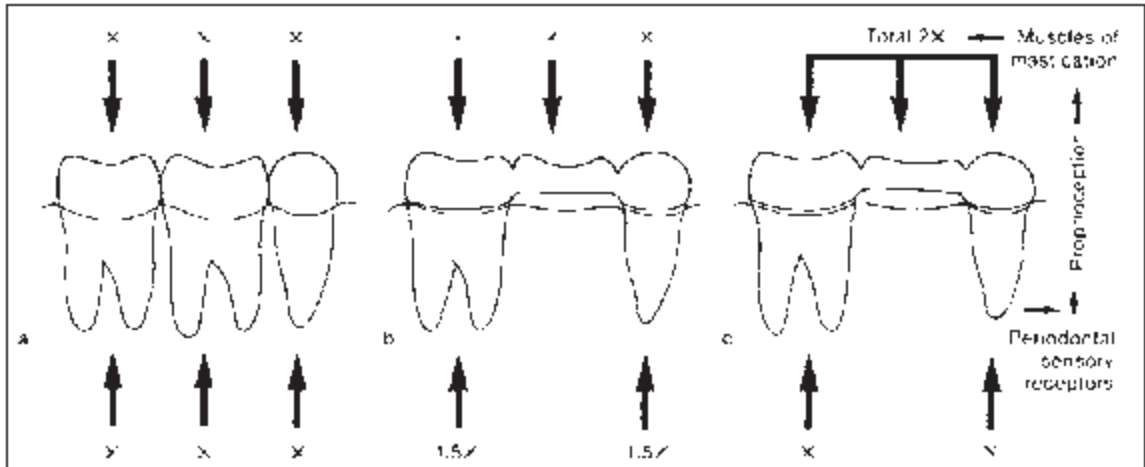
## Support

One of the best known rules for bridge design was devised by Ante and described by him in 1926. He suggested that each pontic should be supported by the equivalent of an abutment tooth with at least the same root surface area covered by bone as would have supported the missing tooth; that is, a given area of periodontal membrane could support up to twice its normal occlusal load. The root surface area of an abutment tooth covered by bone is of course reduced following destructive periodontal disease. This was a guiding principle for many years but is now regarded as little more than a guiding principle – if that.

This arbitrary, mechanical rule is similar to the engineering principles used for designing bridges across rivers. There are many reports in the literature of experiments (usually carried out in the laboratory on models or in computer simulations) relating occlusal forces to reactions in the supporting structures of teeth. The results of these experiments have tended to reinforce these mechanical ideas of how bridges should be designed.

The evidence now suggests that these principles are wrong, or at least do not tell the whole story. Provided that any periodontal disease is treated and periodontal health is maintained, and provided that the occlusal forces are evenly distributed, bridges can be successful with as little as one-quarter of the support advocated by Ante. Such bridges have been successful for many years.

The assumptions made by the engineering school of thought ignore the fact that the occlusal load on a bridge is determined not by extraneous influences, such as lorries driving across road bridges, but by the muscles of mastication. These are under the control of the neuromuscular mechanism, itself influenced by proprioception



**Figure 10.1**

Occlusal loading of abutment teeth.

a In an intact dentition an occlusal force,  $X$ , is resisted by an equal and opposite force generated within the supporting structures of the tooth.

b When a tooth is extracted and replaced by means of a bridge, engineering principles suggest that the same force,  $X$ , delivered to each of the three occlusal surfaces would require the generation of  $1.5X$  in the supporting structures of the two remaining teeth. This principle is no doubt true for inanimate objects but assumes that the occlusal force is constant.

c The occlusal force is of course generated by muscles of mastication, which are under physiological control and do not function independently. Therefore, if the supporting structures of the two remaining teeth are

only capable of generating a resisting force of  $X$ , and if they retain a full proprioceptive mechanism, once force  $X$  is exceeded, the proprioceptive mechanism will suppress the contractions of the muscles of mastication so that the force delivered to the three occlusal surfaces totals  $2X$ .

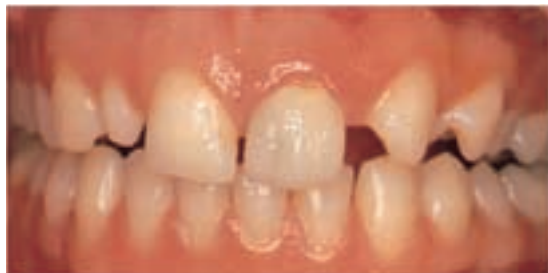This is an oversimplified version of what happens in real life. Sometimes the sensory mechanism is not intact owing to periodontal disease and alveolar bone loss. The proprioceptive mechanism may be overridden by stimuli from higher centres, producing bruxism or other parafunctional activity. The description also ignores the effects of lateral forces, which are more complex. However, the illustration serves to show that bridges should not be designed simply by using engineering principles: the biological implications must be taken into account.

from receptors in the periodontal membrane of the teeth supporting the bridge. Comparisons with road bridges are therefore meaningless.

There is plenty of evidence that occlusal loading is modified by the presence or absence of natural teeth and by their condition. For example, patients can generate 10 times as much force between upper and lower natural teeth as they can between upper and lower complete dentures, where the force is resisted by mucous membrane. It is false logic to assume that increasing the

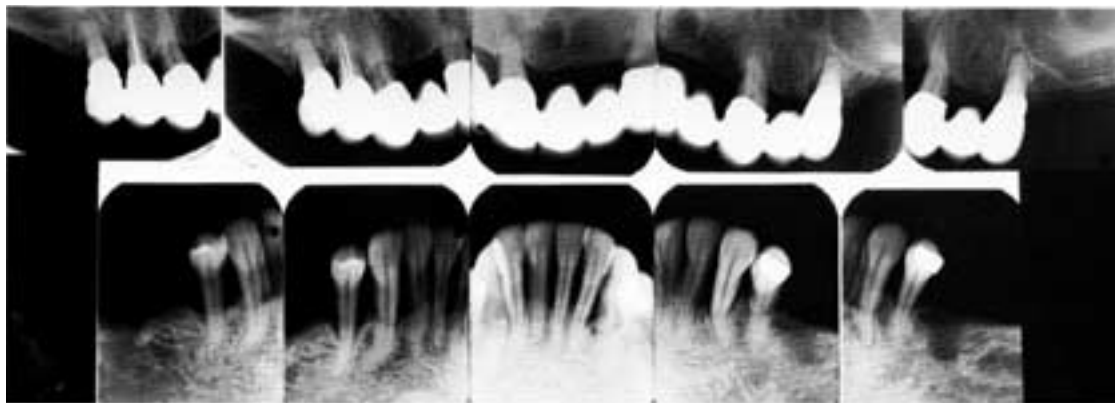occlusal area of a tooth by adding a pontic to it will inevitably increase the occlusal loading on that tooth. However, forces in an 'unnatural' direction, for example rotational or leverage forces, may not be resisted so well. There is not the same inbuilt mechanism to perceive and control these forces (Figure 10.1).

Teeth will also adapt to increasing load physiologically with changes to the periodontal ligament, which thickens to cope with the extra load. The bone support for a tooth will be stable with

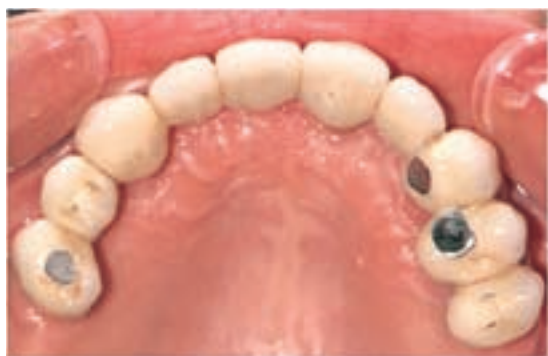**Figure 10.2**

Abutment support and length of span.

*a* A tiny pontic is needed here, and any of the available abutment teeth, which have no alveolar bone loss, would provide more than enough support.



*b* Radiographs of the six abutment teeth supporting the 10-unit bridge in *c*. All the abutment teeth have less than half their original bone support. For the remaining lower teeth this is also much reduced, but the periodontal treatment has been successful and there has been no increase in bone loss or further mobility.



*c* The bridge has been satisfactory, with no further bone loss, but the terminal abutment on the left of the picture has had to be root-treated through the retainer. The bridge, which was 9 years old when this photograph was taken, is rather bulbous.

increasing function and loading as long as the patient maintains oral hygiene and no inflammation is present.

These considerations are often less important in designing small bridges than they are with large bridges. Figure 10.2a shows a case where the span is so small that any of the available abutment teeth would meet all the traditional criteria for support; while in the case of Figure 10.2b a bridge could not be provided if Ante's law were to be observed. Figure 10.2c shows the bridge for the

same patient. It has been successful for many years.

An example of a bridge design that is sometimes unnecessarily destructive because it relies in part on Ante's law for its justification is the replacement of four upper incisor teeth when the canines and first premolar teeth on both sides are used as abutments. Not only is this destructive, it also creates embrasure spaces between the splinted abutment teeth, which are difficult to clean. The premolars are less satisfactory

abutments than the canines, and add little to this design. It has been said that occlusal pressure on the pontics, which are in front of a straight line between canine abutments, would produce a tilting force on the canines. However, in a canine-guided occlusion these same teeth will withstand the entire force of lateral excursions and yet often remain the firmest teeth in the arch. Figures 8.1a and 11.6a show two cases where the canines alone have been used very satisfactorily as abutments. This design, using the two canine teeth as the only abutments, can now be regarded as the normal design for a bridge to replace the four incisor teeth in either the upper or lower jaw. It is not necessary and is indeed counter-productive to include the first premolar teeth.

The best guidance that can be given for the present is that abutment teeth with healthy periodontal tissues are well able to support a (theoretical) increase in loading in an axial direction, because the load is limited by the natural body defence mechanism.

However, they are not so well able to withstand twisting or levering forces. This means that large bridges of fixed-fixed design can be made with very limited numbers of abutment teeth. The curvature of the bridge around the arch reduces the leverage and twisting forces so that all forces are in the long axis of the abutment teeth (Figure 10.2c). This is the principle of 'cross-arch splinting', and it may be extended so that in ideal circumstances long cantilever extensions of several units may be carried by such bridges (Figure 8.5). However, these long cantilevers cannot be supported by individual abutment teeth. They would produce a leverage or twisting force on the abutment tooth causing movement of the tooth in the same way as an orthodontic appliance, or they would loosen the tooth.

The application of these principles of support is illustrated in a series of examples at the end of this chapter, and more practical advice on selecting abutment teeth is also given later in the chapter.

### **Conservation of tooth tissue**

The most conservative design is a minimum-preparation bridge. This is therefore the design of choice whenever possible.

All conventional bridges are potentially destructive, and some are immediately so. For example Figure 10.3 shows a case in which a bridge was made before the introduction of minimum-preparation bridges. The bridge has remained stable and satisfactory. A conventional bridge necessitated extensive preparation of sound tooth tissue of the lower left canine. A cantilever design with only one abutment tooth was a conservative approach at the time rather than fixed-fixed or fixed-movable designs that would have involved more abutment teeth. Today the design would only be used if the canine needed a crown in any case or was unsuitable for a minimum-preparation retainer.

### **Cleansability**

This is a critical consideration. Some bridges fail in the short term because of poor retention or the appearance is unsatisfactory; however, more bridges fail in the medium term because the design does not take sufficient account of accessibility for oral hygiene procedures. Not only should access be possible, it should be easy – to help the average, rather than the highly committed patient.

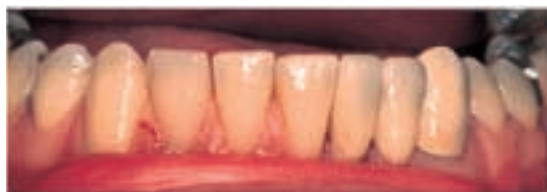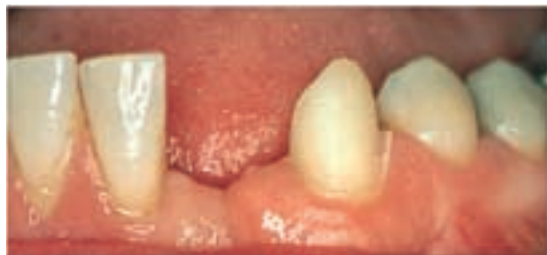Abutment teeth towards the front of the mouth are easier for patients to clean than those further back, partly because of access and partly because the bucco-lingual width of the contact areas is greater with posterior teeth. Chapter 14 includes advice on cleaning bridges.

Figure 9.7 shows well designed, accessible embrasure spaces which are easy to clean.

### **Appearance**

This is the criterion which is often the one of greatest concern to the patient. Some patients have unrealistic expectations and it is sometimes necessary to persuade the patient that a compromise in favour of cleansability over appearance is important for the survival of the bridge. Figure 9.7 illustrates this.

Figure 9.1b illustrates the way in which the appearance of the bridge is often one of the factors in determining its design. If a conventional fixed-fixed or distal cantilever design had been

**Figure 10.3**

*a* and *b* A cantilever bridge with a single lower canine abutment tooth and two incisor pontics (only one tooth is missing). One reason for this design was to avoid preparing the lower incisors. This bridge was made before the days of minimum-preparation bridges or implants, which might now solve this problem. It has, however, been successful for many years, with no rotation, mobility or bone loss.

used it would have been necessary to make a complete crown for the upper canine. This would probably not have been as attractive as the natural tooth. A fixed–movable design with a distal-palatal inlay in the canine carrying a slot for the movable connector as the minor retainer would mean that the appearance of the buccal surface of the canine would be left undisturbed.

The ideal would be a minimum-preparation retainer on the canine supporting a distal cantilever pontic, but the occlusion was unfavourable for this. Another possibility would be a single tooth implant which would not involve the canine at all.

Thus consideration of support, a conservative approach to tooth preparation, cleansability and appearance led to a decision in the case illustrated in Figure 9.1b to make the bridge fixed–movable rather than fixed–fixed or cantilever.

## Planning bridges

### **Collecting information about the patient**

Chapter 5 includes a detailed review of the history and examination of a patient for whom crowns are being considered. The same approach

should be taken with a patient for a bridge. There are, however, a number of additional considerations relating to bridges. These are listed below and should be read in conjunction with the relevant paragraphs in Chapter 5.

### **Consideration of the whole patient**

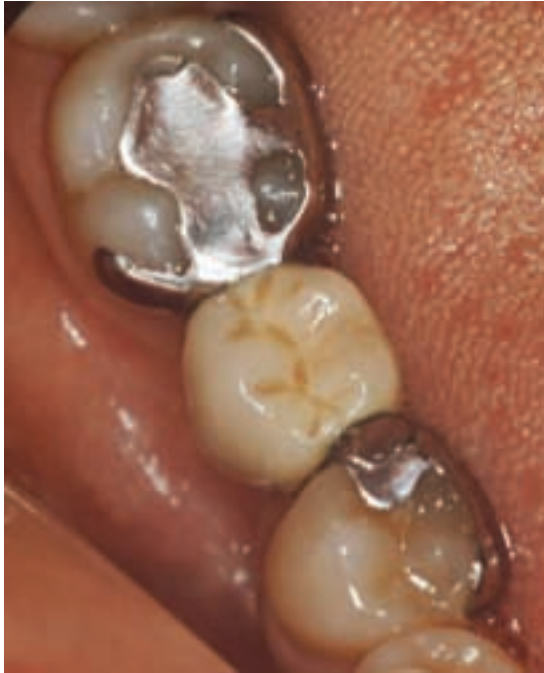With crowns, the choice may be between crowning a tooth or extracting it, and the decision may well be to make a crown even though many factors, for example, the patient's age, attitude to treatment or oral hygiene are less than ideal. With bridges, there is often the alternative of a partial denture, a minimum-preparation bridge or a conventional bridge or an implant, and so it may not be necessary to make so many compromises. If there is any doubt, it is better to make a partial denture first.

### **Clinical examination**

#### **Assessing abutment teeth**

Abutment teeth for minimum-preparation bridges should have sufficient enamel for the retainer,





**Figure 10.4**

Minimum-preparation retainer incorporating an intra-coronal element replacing an MO amalgam. This is a very strong and retentive retainer.

although small composite restorations can be included in the area covered by the retainer. Composite restorations should not be partly covered.

For posterior teeth the retainer may be designed to replace small restorations (Figure 10.4). This increases the enamel bonding surface area intracoronally as well as extracoronally.

For anterior abutment teeth there must either be sufficient clearance for the minimum preparation retainer between upper and lower teeth or it must be possible to create space, preferably by a type of Dahl approach or, more destructively, by adjusting the opposing tooth or preparing the abutment tooth within enamel.

Using the Dahl principle it can be acceptable to cement a conventional or minimum-preparation bridge high and allow for it to create tooth movement. With a minimum-preparation bridge the contact should be onto the retainer not the pontic so that the bridge is not dislodged before the occlusion stabilizes. This is not the same as a 'high' filling, as the retainer is cemented onto an intact external surface and the patient will not experience pulpitic symptoms.

Very thin, translucent incisors are not always suitable as abutment teeth for minimum-prepara-

tion bridges because the metal 'shines through' spoiling the appearance (see Figure 9.1c).

Preferably none of the metal of the minimum-preparation retainer should show but this should be assessed and if metal will show, for example an occlusal rest on a lower premolar tooth, then the patient should be warned about this in advance. Short incisor spans are almost always treated by cantilever bridges, preferably of the minimum-preparation design. This is the preferred option and should be considered first and only if there are problems with it should alternative designs be considered.

With short posterior spans an option is to consider a cantilever design with a single abutment, again preferably of a minimum-preparation design. However, the occlusion must be carefully assessed. Occlusal forces on a cantilever pontic will produce leverage forces on the abutment tooth and tend to tilt it. This is not the case with anterior abutments where the forces are not axial or substantial. The limit is normally a premolar width pontic supported by a molar tooth with a favourable occlusion or perhaps a pontic cantilevered distally from a premolar abutment for reasons of appearance when the pontic will be unopposed or opposed by a denture.

When an anterior span is longer it is preferable to use separate cantilever bridges rather than a fixed–fixed design for reasons described earlier (Figures 7.1d and e).

It is not uncommon for all four incisor teeth to be missing either in the upper or lower jaws. This may be due to trauma or multiple failed restoration in a caries-prone patient or periodontal disease. The canine teeth are often in reasonable condition in these cases and so the preferred option is frequently a fixed–fixed design with the canine teeth as the only abutments.

With larger posterior spans the preferred option is a fixed–movable design, either minimum preparation or conventional and with properly designed movable joints (see Chapter 9) long span fixed–movable bridges are very successful. There is little reliable survey evidence of the relative success rates of long span fixed–movable and fixed–fixed posterior bridges. But what there is, together with clinical evidence suggests that, with appropriate abutment teeth, the fixed–movable design is preferred unless there is a need to splint the teeth (see later). With longer spans the potential advantages of implant-supported restorations increase as the complexity and risks of bridges increase. However, many patients cannot pay for multiple implant restorations and if this is the case and a bridge would have a poor prognosis the only alternatives are to leave the space unrestored or provide a partial denture.

Any tooth that can be crowned can also be considered as an abutment tooth for a conventional bridge, but the abutment tooth may have to withstand forces from different directions than one crowned as an individual tooth (Figure 3.7).

Teeth with active periodontal disease should not be used as abutment teeth until the disease has been successfully treated. However, many teeth with reduced alveolar support following successful treatment of periodontal disease can be used. They are commonly splinted to other abutment teeth to give mutual support.

Some dentists prefer to avoid root-filled teeth or teeth needing post crowns because of the chances of fracture of the roots. However, this risk exists whether or not the tooth is used as an abutment tooth. It may even be reduced if the tooth is used as one of a number of abutment teeth in a larger bridge, so that the force of a blow to the tooth is shared by the other

abutments. Given the choice between a tooth with a post crown as an abutment and a perfectly sound tooth, it is more conservative of tooth tissue to use the former. Although some surveys (mostly out of date and relating to obsolete post systems) have shown a higher incidence of failure with post crowns than other forms of retainer, these figures are similar to the failure rate for individual post-retained crowns.

There may be no suitable alternative abutment to a root-filled tooth, and the choice is then between using the tooth or not making a bridge.

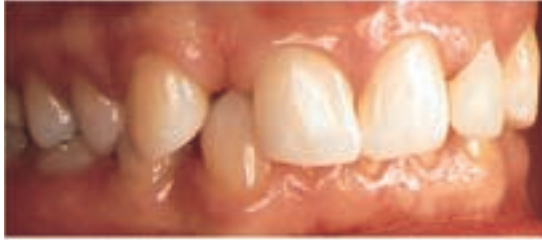Many successful bridges have been made using root-filled abutment and post and core supported retainers. Success will depend upon the amount of residual dentine present and the occlusal loads on the bridge as well as the stability of the posts.

### Length of span

Any design of bridge may be used for short spans of one premolar or incisor width. Simple minimum-preparation cantilever bridges might still be possible for longer upper anterior spans using either the canine or central incisor as the abutment tooth, but the palatal surface of the pontic should be designed so that it shares the guidance with the other teeth and does not carry it exclusively.

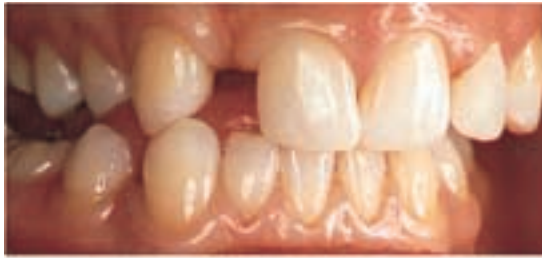### Occlusion

Not only should the occlusion of the remaining teeth be assessed, as described in Chapter 4, but the potential occlusion of the pontic with the opposing teeth should also be assessed. In some cases the occlusal relationships of the potential abutment teeth will help determine which should be used and which design of bridge is suitable. Figure 10.5 shows two cases: one suitable and one unsuitable for a simple cantilever bridge replacing the upper lateral incisor, with the canine as the only abutment tooth. The difference between them is the way the lower incisors relate to the space when the mandible is moved in the protrusive lateral direction. In the second case two abutment teeth will be necessary: either the canine and the first premolar with a cantilever design, or the canine and central incisor with a fixed–fixed or fixed–movable design.

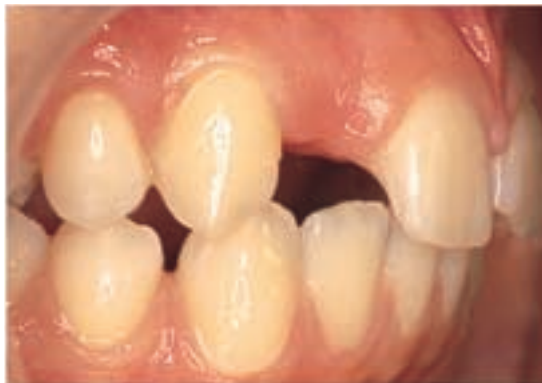**Figure 10.5**

Occlusal assessment.

*a* A missing lateral incisor with deep overbite. The lower canine tooth touches the palate and the palatal surface of the upper canine. There would be insufficient space for a minimum-preparation bridge without minor orthodontic treatment or some reduction of upper or lower canine teeth.



*b* The same patient in a right lateral excursion. The occlusion is canine-guided and the lower teeth are clear of the upper lateral incisor space, so that a simple cantilever bridge with the canine as the sole abutment would not apply unfavourable forces to the pontic. Even with some tooth reduction, this would still be the least destructive design. Alternatively the bridge could be made without any tooth reduction or tooth movement, leaving the retainer high in the occlusion – acting as a Dahl appliance. The occlusion of the patient shown in Figure 8.1c is similar.



*c* In this case the lower incisor passes through the upper lateral incisor space in right lateral excursion, such that group anterior guidance will be inevitable.

### Shape of ridge

The contour of the saddle area will be taken into account in determining whether a bridge with a movable buccal veneer or a partial denture should be made (see Chapters 7 and 8), or whether surgical ridge augmentation should be considered (Figure 7.9).

When a bridge is to be made, the shape of the ridge will affect the appearance of the pontic, and if this is likely to be a critical factor, in other words if the neck of the pontic shows and the patient is

very concerned about their appearance, then one of the procedures described below should be followed to ensure an acceptable final result.

### Predicting the final result

The final appearance of the bridge can be predicted using the study casts, by various intra-oral trials or by means of a provisional bridge. Sometimes combinations of these methods are

necessary. In straightforward cases the dentist and technician will have a good idea of what the final bridge will look like, but the patient will be less clear. The prediction is therefore for the patient's benefit. In other cases where there are unusual features, the dentist and technician may not realize the full aesthetic implications of attempting to make a bridge, or their understanding may be different. In these cases the patient is likely to be even more confused.

Many patients who complain about bridges after they are fitted are unhappy with their appearance. Not only is it good planning to predict the final appearance of the bridge and seek the patient's acceptance before starting, but a record of the predicted appearance may also be useful from a dento-legal point of view should the patient eventually complain.

As well as the appearance of the final bridge, potential difficulties in preparing the teeth should be predicted when possible. These include problems with retention and path of insertion, and the possibility of endangering the pulps of the abutment teeth.

### Study casts

A second study cast should be poured of the arch in which the bridge is to be made. It is sufficient simply to cast the alginate impression a second time, if it can be removed from the initial cast intact. Alternatively, two impressions should be taken or the study cast duplicated in the laboratory.

The second study cast may be used for trial preparations to predict the problems outlined above as well as problems of the individual abutment preparation (Figure 5.3b, c and d). The prepared study cast may be used to make a trial or diagnostic wax-up of the bridge to show to the patient. This is particularly useful when the shape of the abutment teeth will be altered by the retainer crowns or where orthodontic treatment is planned prior to bridge construction.

There are usually alternative means of replacing missing teeth and these change the appearance in different ways. Figure 5.3 shows modified study casts illustrating two ways of changing the appearance that would be difficult to describe to the patient. Neither is ideal, and so the patient must be warned that compromise is necessary.

The work should not be started until the patient understands and accepts this.

If the patient is to be shown the study cast, it is best to produce the wax-up in ivory-coloured wax, or to duplicate the waxed-up cast. The patient can thus look at a cast without the distraction of the contrast between the artificial stone and coloured wax. Most find it easier to compare the second, modified study cast with the first, rather than with themselves, partly because study casts look so artificial to them that they are better comparing two similarly artificial objects, but also of course because they have difficulty in relating a study cast, which is how others see them, to a reversed, mirror image of themselves. Other precautions are detailed in Chapter 5. It is however, difficult for the patient to interpret the potential clinical result from a diagnostic wax-up and ideally an intra-oral trial should be provided for patients where extensive changes to their teeth are planned.

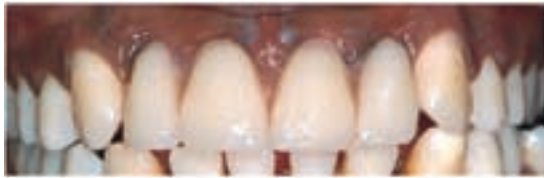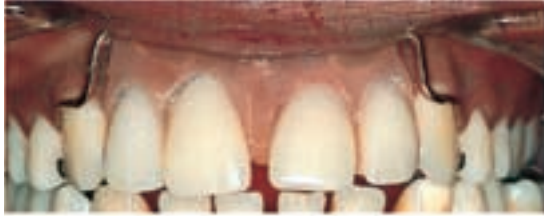### Intra-oral trials

#### Partial dentures

Many patients who are to have anterior bridges already have a partial denture. If the appearance of the artificial tooth on the denture is satisfactory and can be duplicated in a bridge, no further trial is necessary. An impression of the denture in the mouth should be taken to guide the technician on the appearance required. However, if the denture carries a buccal flange, it is wise to try a denture tooth or teeth in the mouth without a buccal flange, usually attached to a simple wax or shellac base, to show the patient the effect (Figure 10.6). The change can be dramatic. This form of intra-oral trial is suitable only when the shape of abutment teeth is not to be changed.

#### Other reversible intra-oral modifications

The size and shape of potential abutment teeth can be increased by the temporary addition of wax or composite. In some cases a denture tooth representing a pontic can also be temporarily attached to adjacent teeth by means of composite. This is particularly useful when there is an



**Figure 10.6**

An intra-oral trial.

*a* A partial denture replacing four incisor teeth, which is to be replaced by a bridge. There is a buccal flange and a midline diastema.

*b* Denture teeth set on a wax baseplate being tried in to ensure that the patient is happy about the appearance of pontics without a buccal flange or the midline diastema. Periodontal treatment will be provided before a bridge is made. The bridge will be six units, with the upper canines as the two abutment teeth.

incisor space which is larger than the missing tooth. The design will usually be a cantilever from one or other of the adjacent teeth leaving a residual space. If the patient is not willing to have orthodontic treatment to reduce the space to the appropriate size, then showing them the appearance of the diastema will give them the information to consent to having one. Again an impression should be taken of the temporary pontic to guide the technician. With extensive restorations a matrix can be taken from a diagnostic wax-up and a labial slip made in the mouth over the teeth using temporary crown and bridge materials to give the patient a better idea in the mouth of the anticipated appearance.

### Temporary and provisional bridges

Once the preparations for a conventional bridge have been made in the mouth, it is possible to make a provisional bridge in the laboratory with acrylic or other materials. These provisional bridges are rather more permanent than temporary bridges (usually made at the chair side), which are only intended to last for 2 or 3 weeks while the permanent bridge is being made. This is comparable to temporary and provisional crowns (see Chapter 6).

One of the purposes of a provisional bridge is to allow further modifications to the shape of the bridge for aesthetic reasons or as modifications to the occlusion until both the dentist and patient

are satisfied with the result. These modifications are then incorporated into the permanent bridge. The provisional bridge can also be removed and adjusted to allow periodontal or endodontic treatment as necessary.

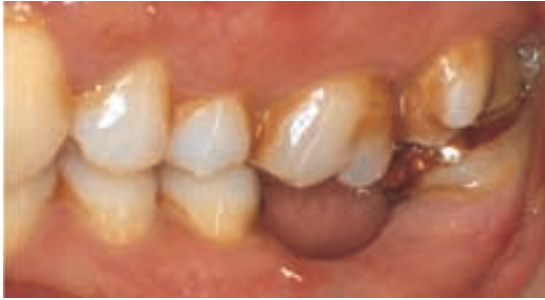A provisional bridge can also be used to confirm that the selected abutment teeth are adequate to support the bridge. For example, if the abutment teeth demonstrate increasing mobility or the provisional bridge continually debonds it may indicate that the abutment teeth are not suitable for long-term use and alternative approaches should be considered.

An example of the use of a provisional bridge is as an immediate insertion replacement of a tooth or teeth to be extracted. If the permanent bridge is to be a conventional design, the abutment teeth are prepared and the provisional bridge made before the extraction – the preparations being protected by separate temporary crowns.

If the permanent bridge is to be a minimum-preparation design, a Rochette design may be used to facilitate removal and modification as the extraction socket heals.

### Practical steps in choosing a bridge design

So far, all the discussion of bridge design has been rather theoretical and somewhat inconclusive.

**Figure 10.7**

The upper first molar has over-erupted. It should either be intruded to the original occlusal plane orthodontically or ground level to the occlusal plane prior to a lower bridge being made. This is in order to avoid occlusal interferences in lateral excursions.

This is inevitable, since designing bridges is still rather more of an art than a science. It is based partly on the clinical experience of the dentist, which will vary from person to person, and on the clinical condition of the patient, which again will vary. However, the design process has to start somewhere. Examples at the end of this chapter illustrate the logical steps in this process.

### **General approach**

A list should be made of all the likely designs for a bridge in the case being considered. This should include the potential abutment teeth and their retainers, together with the basic design of bridge (conventional, minimum-preparation, cantilever, fixed–movable, fixed–fixed and so on). In a simple case when the dentist is experienced, the list can be made mentally. For the less experienced and for more complex cases, it is helpful to write it down.

Every design should be considered in turn and advantages and disadvantages listed. In some cases, the optimum design will be obvious from this procedure. In others, further investigations with modified study casts, intra-oral trials or provisional bridges may be required.

### **Details of stages in the design process**

#### **Selecting abutment teeth**

After the general examination of the patient and whole mouth, individual potential abutment teeth

should be examined and a note made of the presence of caries or restorations and the extent and quality of any restoration present.

The periodontal state should be examined, including the presence of plaque and other deposits, gingival bleeding and periodontal pockets.

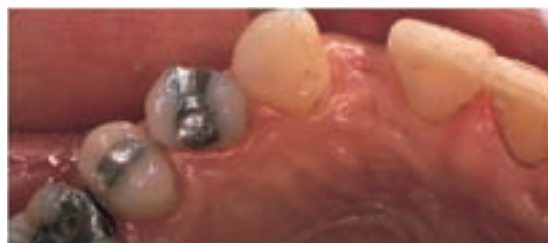The vitality and mobility of the tooth should be tested and a periapical radiograph obtained.

Usually any major problems with the individual tooth should be dealt with first by appropriate treatment, but sometimes the more sensible solution is to extract the tooth and replace it as an additional pontic on the bridge rather than retain a dubious tooth as an abutment when its presence may well jeopardize the future of the whole bridge. An example of this is where three lower incisor teeth are already missing and the fourth has very little bone support. The lower canines are sound and will make good abutment teeth. They will have to be used in any case to support the bridge. Including the remaining incisor will not add significantly to the support of the bridge and may well detract from its long-term prognosis.

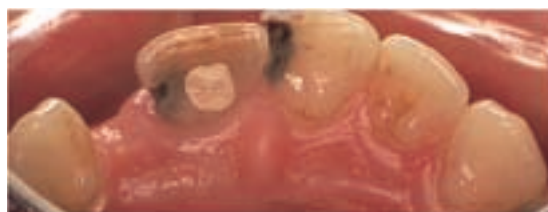A judgement must be made as to the prognosis of all the teeth in the vicinity of the bridge and in the rest of the mouth to reduce the risk of another tooth having to be extracted shortly after the bridge is made.

#### **Selecting the retainers**

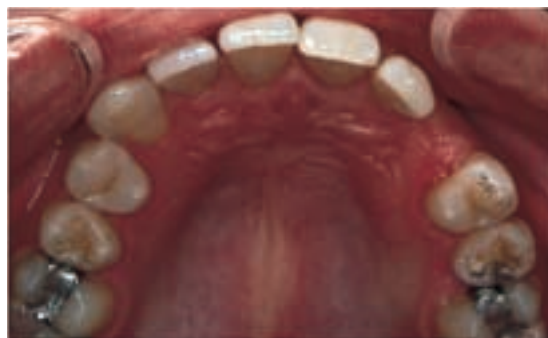The list of potential alternative retainers will include minimum-preparation, complete and partial crowns retainers. The choice of a crown is inevitable when the tooth is already heavily



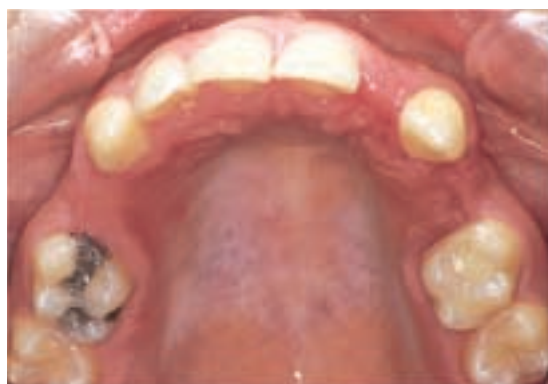a



b



c



d

**Figure 10.8**

Bridge designs for single missing incisors.

*a* A missing upper lateral incisor with rotated canine and first premolar teeth. There is a Class II Division II incisor relationship with a deep overbite and minimum overjet. This means that no space is available for a minimum-preparation bridge attached to the central incisor without orthodontic (or Dahl) treatment or some tooth reduction. The occlusion is satisfactory for a simple cantilever bridge using just the canine tooth as the abutment, and its rotation could be corrected with a complete crown and a conventional bridge. The first premolar has a failed amalgam restoration, which will be replaced separately with a composite restoration to improve the appearance.

*b* Another missing lateral incisor, this time with one discoloured, non-vital, root-filled central incisor and a large mesial carious lesion in the other. The central incisors are also misaligned. The canine is sound. The choice here is between (in order of preference):

- Making a cantilever minimum-preparation bridge retained by the canine and restoring the two central incisors independently, possible by bleaching the root-filled central incisor.
- To restore the carious incisor and crown the root-filled incisor, bringing it into line with the other tooth and using the crown as a conventional retainer for a cantilever pontic.
- If it is considered that the root-filled central incisor would not be an adequate abutment alone for a cantilever bridge, both central incisors could be crowned and splinted together to support the cantilever pontic.

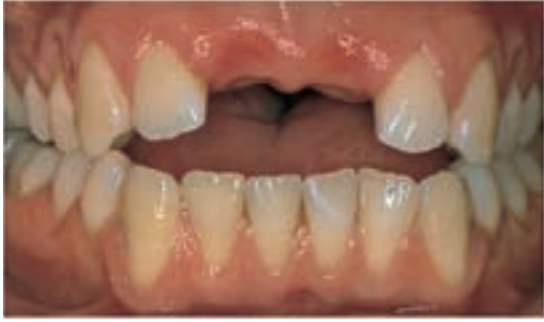*c* A missing upper canine tooth. These are difficult to replace by bridges when the occlusion will be guided by the pontic in lateral excursions, and in these cases several abutment teeth may be necessary. By grinding the lower canine slightly and leaving the pontic slightly short, it was possible to maintain group function in this patient rather than produce canine guidance by the pontic. The two premolar teeth were connected as abutments for a three-unit cantilever bridge. This design was chosen in preference to a fixed-fixed bridge so that preparing the sound, matching and well-aligned incisor teeth could be avoided.

A fixed-movable design with an inlay in the distal surface of the lateral incisor would not have been practicable, because the angulation of the lateral incisor would prevent a common path of insertion between the first premolar and a groove in an inlay in the incisor. This design would have been possible (although not desirable) if the lateral incisor had been more proclined.

A fixed-fixed minimum-preparation bridge could be considered, but not a cantilever design as both adjacent teeth would be poor abutments.

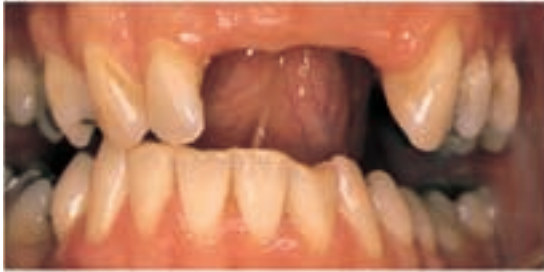*d* A complicated case. If the only tooth missing was the upper lateral incisor then the ideal design would probably be a cantilever minimum-preparation bridge from the canine tooth. However, this tooth is needed to help retain a bridge replacing the two premolar teeth. Therefore the design to replace the lateral incisor consisted of a minimum-preparation bridge cantilevered from the central incisor. The two premolar spaces were both restored by minimum-preparation, fixed-fixed bridges with the canine and first molar teeth as abutments.

These were made in the days when fixed-fixed minimum-preparation designs were generally used. Now the design would be fixed-movable on both sides with the canines supporting the major retainers with fixed connectors and movable joints distally. On the right-hand side of the picture the molar tooth would have a minimum-preparation retainer with a rest seat supporting a finger from the pontic, resisting axial forces on the pontic. On the left the minor retainer would be a gold inlay replacing the MO amalgam restoration – in other words a hybrid bridge.

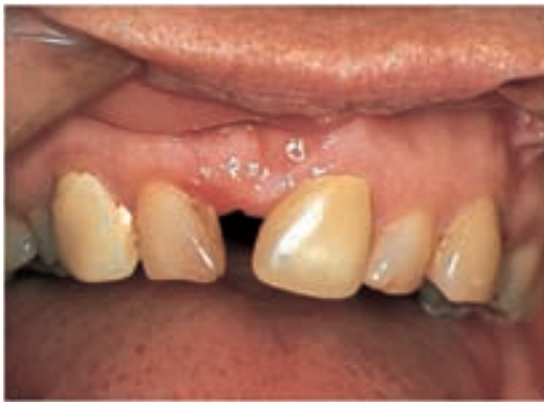**Figure 10.9**

Replacing more than one tooth.

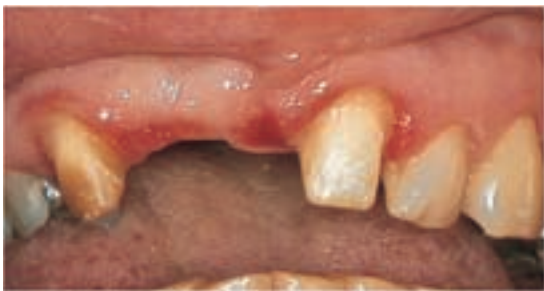*a* With an anterior open bite and normal lateral incisors, a four-unit fixed–fixed minimum-preparation bridge with the lateral incisors as the abutment teeth would be satisfactory. There is no need to include the canine teeth. This design is also acceptable in some cases where there is normal occlusion between the anterior teeth, but the left and right lateral excursions are canine-guided. In such cases the design may be minimum-preparation or conventional.



*b* Even with three incisors missing, with the occlusion being protected in right lateral excursion by a sound canine (shown here), the lateral incisor may be used as the only abutment on the right side for a five-unit fixed–fixed conventional bridge. The bridge could be extended to include the right canine, giving additional support and a more symmetrical appearance, but this would make the embrasure space between the lateral incisor and canine difficult to clean and would be unnecessarily destructive.

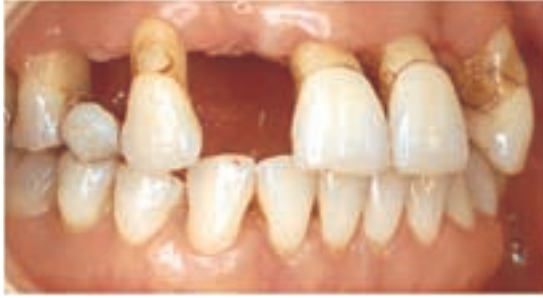

*c* and *d* The central incisor space is now reduced to approximately one-quarter of its proper width, although this is somewhat difficult to judge since the left central incisor has an acrylic crown. The right canine also has an unsatisfactory acrylic crown. Trial wax-ups showed that a satisfactory appearance could be obtained by extracting the non-vital lateral incisor and making a four-unit fixed–fixed bridge. Both central incisors and the lateral incisor pontic would be small, but would give a better appearance than two large central incisors with the midline offset even further. The alternative of orthodontic treatment prior to bridgework was offered to the patient and declined. This is a similar problem to that of another patient, shown in Figure 7.7.

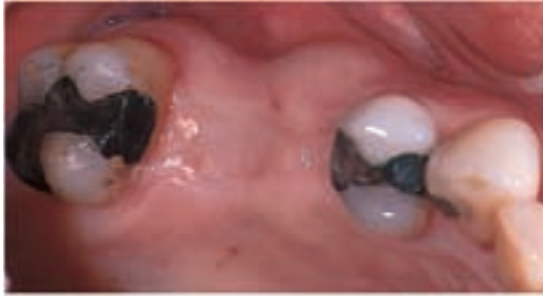

*d* The upper lateral incisor has been extracted and the two abutment teeth prepared. It is now clear that there will be sufficient space for the planned treatment. A provisional bridge will be fitted and periodontal treatment provided before impressions are taken for the permanent bridge.





e Existing crowns and a bridge following extensive, successful periodontal treatment and the extraction of the lateral incisors. None of the remaining teeth are satisfactory abutments for simple small bridges, and a partial denture replacing the lateral incisors and the totally unsatisfactory premolar pontic would be damaging to the periodontal tissues. A splint/bridge incorporating the principle of cross-arch splinting is indicated here.



f Sound restored abutment teeth and a span that will accommodate one premolar and one molar pontic. The buccal surface of the premolar is sound and of good appearance, and so one design could be a fixed-movable conventional bridge with a complete crown on the molar tooth and an MOD inlay (without cuspal coverage to avoid showing gold) in the premolar. The movable joint will be accommodated in the distal box of the inlay. A hybrid bridge would not be suitable, since the restoration in the molar tooth is too large for this tooth to have a minimum-preparation retainer.

restored. The choice between a minimum-preparation retainer and a crown will depend upon whether the abutment teeth have restorations in them, the occlusal clearance and the appearance of the abutment teeth. If the only difficulty with minimum-preparation retainers is the lack of occlusal clearance, it may be possible to create sufficient clearance by the means described in the caption to Figure 10.5.

### Selecting the pontics and connectors

The design of pontics and connectors is the responsibility of the dentist and not the technician. Detailed instructions should be given to the technician, particularly on the contour of the ridge surface of the pontic (see Chapter 9). When the technician is unfamiliar with the dentist's usual requirements, the details of the design should be drawn and sent to the technician as part of the prescription for the bridge. Where a metal-ceramic pontic is to be made, the dentist

should indicate where the porcelain should be finished. In some cases an all-porcelain occlusal surface is required; in others the porcelain covers only the buccal surface and buccal cusp, leaving the remainder of the occlusal surface in metal. Again, this should be specified.

### Planning the occlusion

Details of this stage were given in Chapter 4. The first decision to be made is whether to articulate study casts and, if so, whether it is necessary to use a simple hinge or semi-adjustable articulator. With small bridges it is helpful to mount casts on at least a simple hinge articulator. With most large bridges a semi-adjustable or fully adjustable articulator should be used.

The second decision is whether any occlusal adjustment is necessary prior to tooth preparations for the bridge. With posterior bridgework it is often necessary to adjust an over-erupted opposing tooth (Figure 10.7). The anticipated

**Alternative designs for a bridge to replace an upper lateral incisor**

Design	Abutment(s)	Retainer(s)
1 Cantilever	Canine	Minimum-preparation
2 Cantilever	Canine	Crown
3 Cantilever	Central incisor	Minimum-preparation
4 Cantilever	Central incisor	Crown
5 Cantilever	Both central incisors	Minimum-preparation
6 Cantilever	Both central incisors	Crowns
7 Fixed-fixed	Canine + central incisor	Minimum-preparation
8 Fixed-fixed	Canine + central incisor	Crowns
9 Fixed-movable	Canine + central incisor	Minimum-preparation
10 Fixed-movable	Canine + central incisor	Crowns
11 Fixed-movable	Canine + central incisor	Minimum-preparation + crown

The most common designs are at the top of the list but all the designs, and others, are used in appropriate circumstances.

occlusal relationship of the pontic with the opposing teeth may influence the basic design of the bridge as well as the details of the occlusal surface of the pontic; although this step is listed as the final one in the sequence, and it is usually considered last. If the bridge design is influenced by it, it will be necessary to introduce feedback loops to earlier stages.

### **Examples of the bridge design process**

Figures 10.8 and 10.9 give practical examples and the reasons for the choice. Some alternative designs, and the reasons for rejecting them, are also given.

Dentists will inevitably become biased in their selection of bridge designs by their own experience of clinical success and failure. Indeed, the bias of the authors may be detected, for example,

in Figures 10.8 and 10.9. Care should be taken to prevent this bias overriding more substantial clinical criteria.

As another example, the above list sets out alternative designs for the replacement of one upper lateral incisor. Some of the suggestions on this list are uncommon and would not be used other than in exceptional circumstances. In some cases, however, the upper lateral incisor would be replaced as part of a much larger bridge/splint. In that case all the remaining upper incisors and probably teeth further back in the arch would also be included. So the list could be extended further to show an even greater variety of potential abutment teeth, and extended further still to show the choice of materials.

The important point is to show the large range of designs possible and the dangers inherent in falling into the habit of only using a limited range of designs. Each case has a unique combination of features and a specific design should be chosen to address these.

**WWW.HIGHDENT.IR**

همیار دندانسازان و دندانپزشکان

## II

# Clinical techniques for bridge construction

This chapter should be read in conjunction with Chapter 6. Many of the techniques are identical, and so this chapter will deal only with those that are peculiar to bridges or where a different emphasis is necessary.

## Preoperative procedures

All the planning stages described in Chapters 5, 6 and 10 should be undertaken. In particular, the shade should be taken and an impression for the opposing cast made. The following additional preoperative procedures may also be required.

## Occlusal adjustment

It is more often necessary to carry out an occlusal adjustment in preparation for a bridge than for crowns. Indications for this are identified in Chapter 4. A new impression must be taken for the opposing jaw if this has been adjusted, since the study cast will obviously no longer be accurate.

Additional space for anterior retainers can be produced by using a Dahl appliance (see Chapter 6).

## Preparations for a temporary bridge

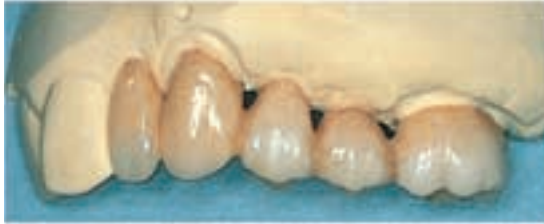For a conventional bridge it must be decided whether a temporary bridge will be made or whether the patient will be left with individual temporary restorations to protect the abutment

teeth. When the patient has a satisfactory temporary denture and especially if the design is a cantilever or fixed–movable conventional bridge or any design of minimum-preparation bridge, it is often better to make separate temporary restorations rather than a temporary bridge. When the design is fixed–movable and the paths of insertion of the retainers will not be parallel to each other, it may be impractical to make a temporary bridge. Besides, when a minor retainer such as a distal-occlusal inlay is to be made for a fixed–movable bridge, the temporary bridge (which will be fixed–fixed) may loosen at the minor retainer.

However, in many cases, particularly for larger fixed–fixed conventional bridges, a temporary bridge is essential to protect the abutment teeth and to retain their relationship with each other and the opposing teeth. Temporary bridges may be made in one of two ways: either by one of the chair-side techniques described in Chapter 6, or by making an acrylic temporary bridge on the study cast, using the trial preparations, and then relining and adjusting this at the chair side as necessary.

If a chair-side technique is to be used, a trial wax-up on the study cast should be made and duplicated (by means of an alginate or elastomeric impression) to make a stone cast. A vacuum-formed PVC slip or a silicone putty matrix can then be produced (Figure 6.17). Alternatively, a silicone impression of the waxed-up study cast may be used directly in the mouth to make the temporary bridge.

Figure 11.1 shows a laboratory-made temporary bridge, constructed before the teeth are prepared so that it can be adapted and cemented at the tooth preparation visit. Techniques for



**Figure 11.1**

A laboratory-made temporary acrylic bridge (see also Figure 9.4c).

constructing chair-side temporary bridges are described later.

## Preparing the abutment teeth

### *Preparations for minimum-preparation bridges*

Since the introduction of minimum-preparation bridges there have been fluctuations in fashion as to the degree of tooth preparation that should be carried out. Initially very little preparation was undertaken, and then over the next few years various authors recommended more and more extensive preparation with finishing lines, seating grooves at right angles to the path of insertion and location grooves in the line of the path of insertion all being advocated. Some dentists even went as far as using operating microscopes and complicated paralleling devices.

There is very little evidence that any of these produce significant benefit. With this lack of evidence the only sensible approach is to limit tooth preparation to those aspects where there is a logical reason to prepare the tooth (see later).

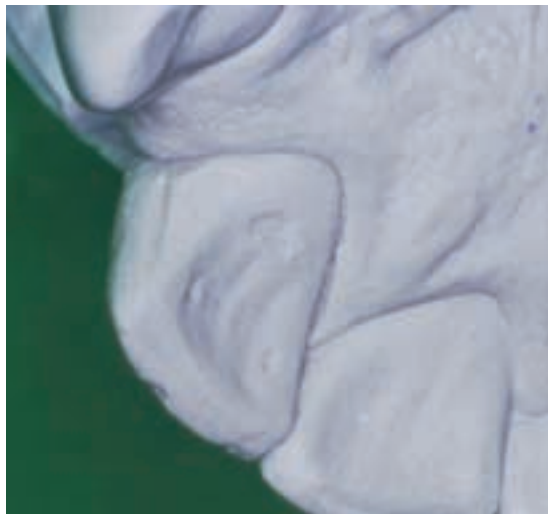There is no justification for producing a finishing line near to the gingival margin of either anterior or posterior teeth. Some dentists have advocated this in order to identify where the technician should complete the wax-up. It is not justified to prepare enamel for this purpose which can be achieved equally well by drawing a line on the study model with a pencil. Gingival margin preparation is also advocated to reduce the thickness of metal at the surface and therefore the

discrepancy between the retainer surface and the enamel which might be plaque-retentive. Usually the enamel cannot be prepared to a sufficient depth to allow a straight-line junction between the retainer and the tooth surface without encroaching on dentine. It is better to make the margin of the retainer a millimetre or two away from the gingival margin so that access for cleaning is easy.

One danger of overpreparing teeth for these types of retainer is that if the retainer becomes debonded but the bridge is held in place by other retainers, features such as grooves tend to become carious more rapidly than unprepared enamel surfaces and, because the dentine is closer to the base of the groove, it too becomes carious with the result that a further minimum-preparation retainer is not possible. There is also less enamel to bond to and all resin cements bond better to enamel than to dentine. Therefore the preparation should be within enamel and the use of a local anaesthetic is discouraged to allow the patient to warn the dentist when the dentine is being approached.

However, some tooth preparation is usually necessary and the principles that should guide the operator in deciding what this should be are:

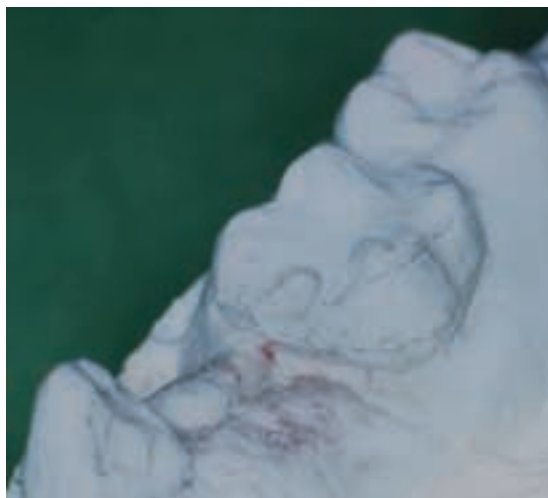- The maximum surface area of enamel should be used for retention of major retainers, avoiding the incisal edges and potential 'shine through' of the metal framework (Figure 9.2c).
- The bridge should seat positively so that it can be held firmly in place without movement against the resistance of rubber dam while the cement is setting. For anterior teeth this should be a small horizontal notch with the base at right angles to the path of insertion of the



**Figure 11.2**

Preparations for minimum-preparation bridges.

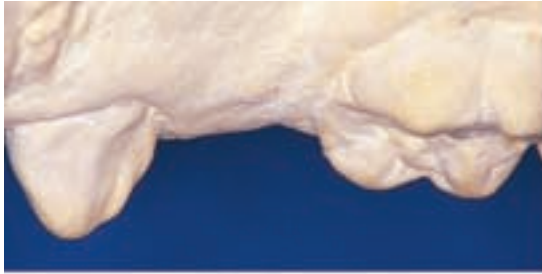*a* A shallow rest in the cingulum and minor preparation to the mesial surface with a shallow slot. This defines the extent of metal wrap-around possible without metal showing labially.



*b* A mesial rest seat on a molar tooth with minor preparation to the palatal surface to allow the metal framework to extend over the maximum surface area.

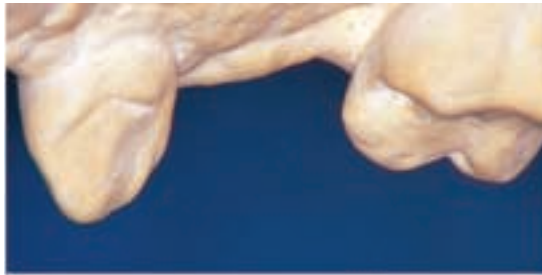


*c* Incorporating an MO preparation into a minimum-preparation retainer.



**Figure 11.3**

*a* The lingual view of an incompletely erupted upper canine tooth to be used as an abutment for a minimum-preparation bridge.



*b* Crown lengthening has been carried out to give a greater surface area and a horizontal seating ledge has been prepared at the cingulum to stabilize the retainer firmly while the bridge is being bonded. This size of ledge is all that is necessary for the purpose.

bridge. The notch should be entirely in enamel and need only be 2 or 3 mm wide (Figure 11.2a). With posterior retainers this purpose is usually served by preparing a shallow rest seat in enamel (Figure 11.2b) or alternatively by replacing a small restoration (Figure 11.2c).

- Preparation may be necessary to allow an adequate thickness of retainer when the occlusion is unfavourable. It is sometimes possible for the framework of a minimum-preparation bridge to be cemented 'high' to achieve space in the same way as a Dahl appliance works.

The maximum enamel surface area can often be achieved with anterior bridges without any tooth preparation other than a seating ledge (Figure 11.3).

Figure 11.4 shows a section of an unprepared molar tooth (Figure 11.4a), together with a pattern for a minimum preparation retainer without preparing the tooth (Figure 11.4b) and after preparing the tooth (Figure 11.4c). In both Figure 11.4b and c there is inevitably a change of contour at the margin of the retainer, which must be kept clean by the patient. In this, and many cases, there would be no advantage in preparing this axial surface. It has been suggested that a finishing line indicates to the technician where the

retainer is to finish. This is a completely unjustifiable reason, because the same indication could be given by the dentist drawing the retainer outline on the study cast.

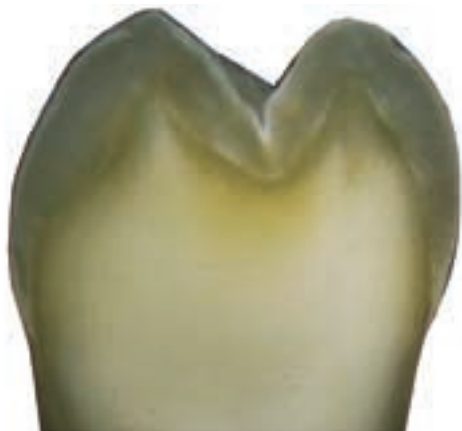## **Preparations for conventional bridges**

### **Paralleling techniques for conventional preparations**

A fixed–fixed conventional bridge requires two or more teeth to be prepared in a common path of insertion. Special techniques are used to ensure that there are no undercuts and yet each individual preparation is as retentive as possible. These are listed in increasing order of complexity.

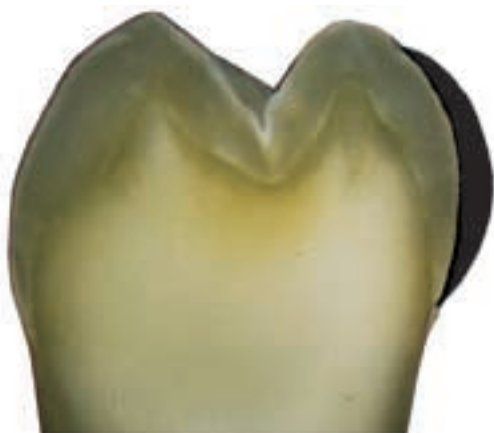#### **Paralleling by eye**

Two or three teeth close together can be made parallel by eye. The clinician will become more adept at doing this with experience, and should concentrate on developing the skill, in the first place on study models. The inexperienced operator should *always* practice on study models before preparing the teeth.

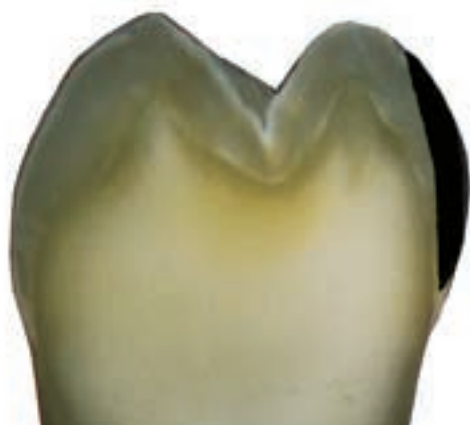**Figure 11.4**

Posterior minimum-preparation retainer design.

*a* A section through an extracted molar tooth.

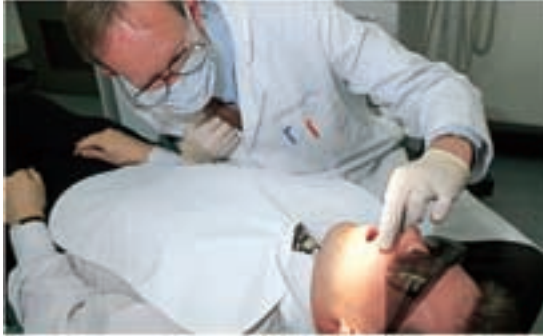

*b* The tooth has not been prepared and the retainer will be bonded directly to the enamel surface. The junction at the gingival margin should be well clear of the gingival tissue



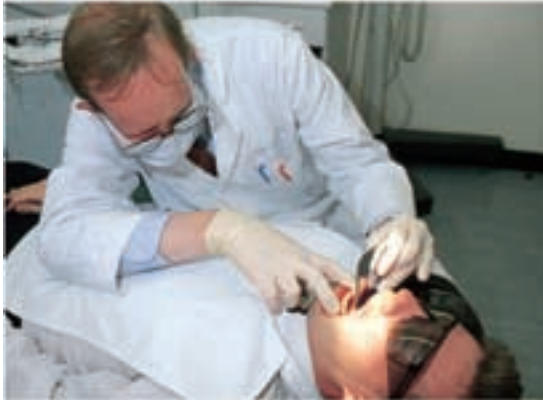*c* There has been some preparation, entirely within enamel, and so the retainer is partly within and partly outside the original tooth contour.



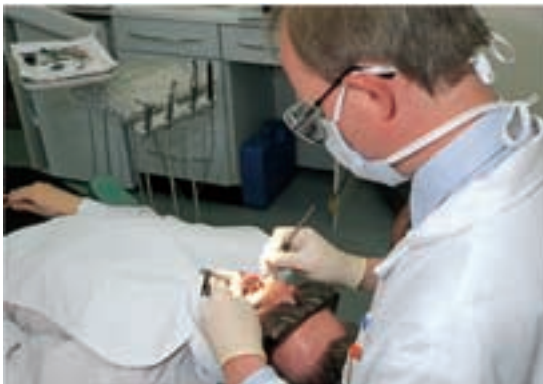**Figure 11.5**

Clinical methods of assessing parallelism of bridge abutment preparations.

*a* Using direct vision, from a distance with one eye closed when, for example, upper canine teeth are being prepared for a fixed–fixed bridge.



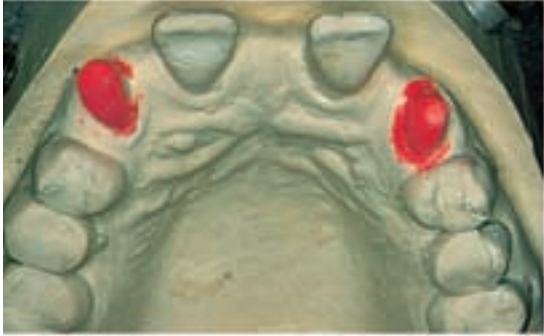
*b* Using a full arch mirror for the same purpose in the lower jaw. Full arch mirrors are used in clinical photography and many of the photographs in this book were taken with one of these large mirrors.



*c* Using a straight probe as an 'intra-oral surveyor'. The operator must stay very still other than moving the probe round the abutment teeth in a controlled fashion. This, on its own, may not be enough but gives a guide to the presence of undercuts. Operators who make a significant number of bridges develop considerable skill in this technique.

In the anterior part of the mouth it is possible to see along the long axis of the teeth by direct vision. Only one eye should be used, since binocular vision can 'see around' undercuts. Figure 11.5a shows a dentist assessing the path of insertion of the upper canine teeth, which are being prepared for a bridge replacing the four

incisor teeth. It helps to look from as far away as possible. It may also be useful to make a small pencil mark on the two surfaces that may still be undercut. An assessment of parallelism or undercut can then be made by closing one eye and moving the head so that one of the pencil marks just disappears and then continuing to

**Figure 11.6**

Surveying preparations.

*a* Initial preparations have been carried out on the upper canine teeth in the mouth and this cast has been made from an alginate impression. The two preparations have been varnished. The bridge will be a six-unit immediate-insertion provisional bridge, and the two remaining incisors with extensive alveolar bone loss will be extracted.



*b* The preparations are surveyed with a fine rod, and the cast is trimmed until they are parallel. Trimmed areas show up in contrast to the untouched varnished areas. Similar reduction is carried out in the mouth. The process may need to be repeated.

move the head until the other pencil mark appears.

In the lower jaw and in posterior parts of the mouth large mirrors are useful to show all the preparations in the same field. Parallelism cannot be assessed satisfactorily when two or more preparations can be seen only by moving the small mouth mirror. Many of the photographs in this book have been taken in larger, front-surface-reflecting mirrors (Figure 11.5b).

It is also helpful to use a straight probe like a laboratory surveyor, but in the mouth. The probe is placed against one of the prepared tooth surfaces, and then, held rigidly, it is moved over to the other abutment tooth without its angulation being changed. This is not a completely

reliable guide of course, and will detect only fairly gross undercuts or over-taper, but many clinicians do find it useful (Figure 11.5c).

The risk of not striving for near parallelism is that excessive taper between abutment teeth is more likely to result in de-cementation somewhere on the bridge.

### Extra-oral survey

With larger bridges and when teeth are prepared on both sides of the arch, the simplest and most reliable method of assessing parallelism is to take a simple impression (usually in alginate) once the basic reduction has been carried out on all the

abutment teeth. The impression is cast at the chair side in a fast-setting plaster, usually with an accelerator such as alum added. The cast is then surveyed at the chair side and further preparation carried out as required (Figure 11.6). The procedure may be repeated several times with more difficult cases or with large numbers of abutment teeth. When the abutments are satisfactory for the path of insertion, the final smoothing and finishing of the preparations is carried out.

### **Paralleling devices for crown preparations**

Many of the devices available are cumbersome, unreliable or extremely expensive. One of the simpler ones consists of a stainless-steel mirror with vertical lines scribed on it. This is placed buccally or lingually and used to assess the mesio-distal parallelism of abutment preparations. It cannot be used for the buccal-lingual surfaces. Another device consists of a clear plastic disc with a pin passing through it. This is held against the occlusal surfaces and can be moved around, acting as a surveyor. These two devices may be useful, but the inexperienced dentist is better advised to master the basic techniques of surveying by eye and extra-oral surveying

### **Making temporary and provisional bridges**

Temporary bridges are made at the chair side or more rarely in the laboratory and are expected to be used clinically for a few weeks while the permanent restorations are made. Provisional bridges are used when longer-term temporary restorations are required, usually while occlusal or appearance issues are resolved and time is needed before the permanent restoration is provided. They may also be used where endodontic or periodontal treatment needs time to be assessed or while implants are integrating. They are normally laboratory-made.

### **Choice of material**

Chair-side temporary bridges are made with one of the materials designed for the purpose.

Laboratory-made temporary bridges are made with similar techniques to those described for crowns in Chapter 3. However, long-term provisional bridges often need reinforcement to strengthen the span and this can be achieved by the technique described in Chapter 6 using light-cured composite and quartz-fibre reinforcement. Alternatively a simple metal casting may be made using an impression of the prepared teeth and this can be faced with composite or acrylic. However, the occlusal surface and margins should be acrylic or composite so that adjustments can be made either by removing or adding material if necessary. Modern temporary crown and bridge materials are sufficiently resistant to wear for this to be possible.

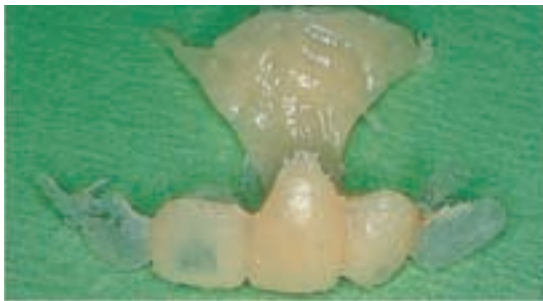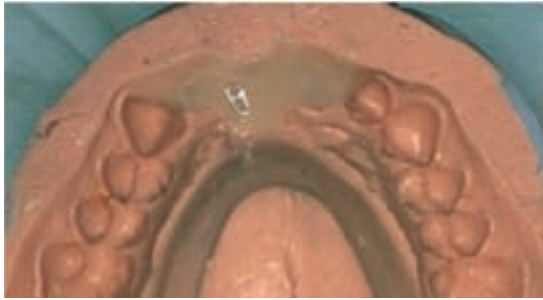
### **Choice of technique**

#### **Chair-side construction**

The majority of temporary bridges can readily be made at the chair side, often in less time than it takes to modify a laboratory-made temporary bridge, and of course avoiding the additional laboratory cost.

The chair-side technique illustrated in Figure 11.7 is similar to the temporary crown techniques shown in Figures 6.17 and 6.18. The mould may be an impression of a study cast with the pontic made from a denture tooth, or it may be a vacuum-formed PVC slip. In many anterior bridges, though, the patient is already wearing a temporary denture, and it is sufficient to take an alginate or silicone impression of the arch with the denture in place and use this to make the temporary bridge. This is the technique illustrated in Figure 11.7. The excess material flowing into the areas of the impression previously occupied by the denture can be removed with an acrylic bur in a straight handpiece, once the plastic has set and the temporary bridge has been removed from the mouth.

For posterior bridges, where there is often no temporary denture, but where the appearance of the pontic is not important, an impression may be taken (with nothing in the saddle area) before the teeth are prepared, and used to make individual temporary crowns for the abutment teeth.

**Figure 11.7**

Chair-side temporary bridge construction.

*a* An alginate impression is taken before the preparations are started, with the temporary denture in place. The alginate is removed from the buccal sulcus area to facilitate reseating in the mouth before the temporary crown and bridge material is put into the impression.

*b* The plastic temporary bridge removed from the mouth. The material has flowed palatally into the space left by the plate of the denture. This can now be removed together with the thin flash over the adjacent unprepared teeth. The almost-transparent buccal-incisal surface of the upper right central incisor retainer shows that more preparation of the abutment tooth is needed here or the retainer will be too thick. To a lesser extent the same is true at the tip of the upper left lateral incisor. These modifications should be made to the preparations before the impression is taken.

### Laboratory-made provisional bridges

If the provisional bridge is to last for more than a week or two, if it is large or if its appearance is particularly important, then a laboratory-made provisional bridge is preferable to a bridge made at the chair side.

One technique is to make preparations of the abutment teeth on a study cast so that when the full-scale preparation is done in the mouth the temporary bridge will be a loose fit. If the preparations on the study cast are completed to full depth, it will be impossible to duplicate them exactly in the mouth, and the provisional bridge will not seat.

If full-scale trial preparations have been made to assess parallelism, this cast may still be used to make a provisional bridge, the prepared teeth on the study cast are covered with a spacer of tin foil, or the fit surfaces of the bridge are enlarged with a bur in the laboratory before the bridge is returned to the chair side. The bridge

is waxed up and processed in the laboratory using conventional acrylic techniques (Figure 11.1).

Once the abutment teeth have been prepared in the mouth, the provisional bridge is tried in and will usually need to be relined with a higher acrylic.

The technique using an accurate working impression of the prepared teeth to make a provisional bridge is more reliable, and often produces a better marginal fit but takes an extra appointment. This is necessary, however, if a metal casting is to be incorporated for extra strength (Figure 11.8).

Cast metal and composite provisional bridges (and crowns) have become popular with some dentists. They are strong, fit well and have a good appearance. However, the laboratory costs are high, sometimes nearly as much as permanent restorations. When they are used, all the surfaces which may need to be adjusted must be in composite which can be ground and added to with more composite. This is sometimes difficult,



**Figure 11.8**

A long-term, immediate-insertion, metal/composite provisional bridge in heat-cured acrylic incorporating a metal casting.

for example, when the palatal surface of an upper incisor abutment has been prepared with a chamfer for a metal–ceramic retainer there will not be enough room for metal–composite. This means that the laboratory will make a metal palatal surface which will be difficult to adjust and which negates the purpose of a provisional restoration. An all-acrylic or composite provisional restoration would be better. Before making a metal–composite provisional restoration there should be a cost–benefit analysis compared with less expensive alternatives.

### **Cementing temporary and provisional bridges**

Temporary bridges should be sufficiently retentive not to cause trouble between appointments, but it should be possible to remove them without excessive force or damage. The temporary crown and bridge cementing materials are supplied with a modifying paste that may be combined in varying proportions with the base and catalyst pastes to weaken the final mix. Modified cement is recommended with large or very retentive bridges. Experience will guide the operator as to the correct proportions for the particular bridge and the particular cement; 50% or more of the total mix may consist of the modifying paste.

Provisional bridges may also be cemented with temporary crown and bridge cement, but usually without modifying paste because they need to last longer. Temporary cements are easily fractured

with ‘sudden’ loading such as with a bridge remover (see Chapter 14). The cement remaining on the preparation can easily be removed as it is not adhesive.

### **The working impression**

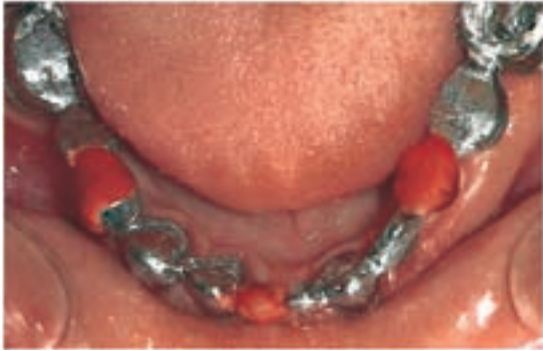Any of the impression materials or techniques described in Chapter 6 are suitable for bridges. With fixed–fixed bridges it is often an advantage to have two working casts, one with removable dies for making the individual retainers and one that is not sectioned and therefore preserves the full contour of the saddle area together with the relationship of the abutment teeth and adjacent teeth. With good die location and a small bridge, an unsectioned model is not necessary, but with larger reconstructions where the dies have to be removed and replaced often, some die location systems tend to wear, allowing movement of the dies. Then a solid model may be necessary. By ensuring the correct relationships between abutment teeth the solid model is used to confirm the bridge will seat easily in the mouth, the correct contacts to the soft tissues and the contact points with the adjacent teeth.

All bridges should be made with full arch working impressions for maximum stability of the occlusion.

For short span bridges a stock tray is normally adequate but for extensive or complex bridges a special tray is better. Figure 6.4 shows the construction of special trays.

**Figure 11.9****Localization**

*a* The metal framework for a three-unit metal–ceramic bridge. This has been tried in the mouth and found not to fit. When sectioned diagonally through the pontic, the separate retainers fitted, and so it was relocalized in the mouth and soldered before the porcelain was added.



*b* A large bridge, cast in four sections, being localized in the mouth with fast-setting acrylic. To stabilize it, a bar (a long bur shank is the right stiffness) will be attached across the back with more acrylic.

## Occlusal records

For the choice of appropriate occlusal records, see Chapter 4. The larger the bridge, the more time-consuming is any occlusal adjustment at the chair side, so a semi-adjustable (or fully adjustable articulator) should be used, together with the appropriate occlusal records.

## Trying in the metal framework or separate units

Metal–ceramic conventional bridges should be tried in at the metal stage. Experienced operators making small bridges, who are familiar with their technician's work, sometimes omit this stage, but this is inadvisable under other conditions.

Metal–ceramic bridges of up to six units are often cast in one piece. When they are tried in, all the checks listed in Chapter 6 should be made, and if the framework is acceptable, it may be

returned to the laboratory for the porcelain to be added.

If the framework does not seat, and once obvious causes have been eliminated, such as tight contact points or air blows on the fit surface of the casting, it must be assumed that the relationship between the abutment teeth is the problem. This may be wrong either because the abutment teeth have moved since the impression was taken (perhaps because a temporary bridge was not provided) or because the die location is at fault. If this is suspected, the bridge should be divided and the separate components tried in. It is better to saw through the bridge with a fine fretsaw cutting diagonally through one of the pontics rather than through a connector (Figure 11.9a). This gives a larger surface area for the bridge to be re-soldered, and the solder joint will be covered by porcelain, which will further strengthen it. If the separate units fit, the bridge is relocated (see below) and soldered with a high temperature solder or laser welded before the porcelain is added. It is advisable to retry the bridge again.

If, once the bridge is sectioned, some of the retainers fit and others do not, a further impression is needed. This will be of the unsatisfactory abutments, with the satisfactory retainers and the attached parts of the pontic left *in situ*. They will be a guide to the technician in waxing-up the repeated sections. A further retry and localization in the mouth is necessary before soldering.

With larger bridges not cast in one piece, the separate sections should be tried in before localization and soldering.

Bridges made in other materials are usually completed and not tried in as separate units. Posterior all-metal bridges are necessarily relatively small, as are anterior all-porcelain bridges. Where metal units are to be soldered to metal–ceramic units, it is possible to try in the separate retainers before the connectors are soldered.

### Localization techniques

Full arch impressions should be taken almost universally for bridges and so there is little need for localization of individual retainers. However, problems still arise, as outlined in the previous section, with the fit of one-piece castings. It may also be difficult to get a single impression of all the teeth at once, especially when large bridges are made in the lower arch. The tongue makes it difficult to obtain a dry field on both sides of the arch at the same time. In these cases separate impressions of groups of abutment teeth are taken and related to each other with a localization technique.

An overall impression of the castings in place may be used for localization. A rigid elastomeric material such as polyether must be used, since softer materials distort when the casting and dies are seated in the impression. Sometimes, it is necessary to cement the retainers with a very weak cement or petroleum jelly to keep them in position while the localizing impression is taken. An alternative is to use acrylic with a paint-on technique. When adjacent retainers are to be located or a cut pontic re-soldered, it is sufficient simply to clean the surfaces, paint a fast-setting cold-cure acrylic over the surface and allow it to harden before withdrawing the bridge (Figure 11.9b).

### Try-in and trial cementation of finished bridges

The checking procedure is as described in Chapter 6. In some cases the bridge does not fully seat and the operator may suspect that the teeth have moved, particularly if a metal stage try-in was satisfactory. Rather than sectioning the bridge again, it may be left in the mouth for a few hours, preferably with no cement, or with petroleum jelly and zinc oxide powder (which does not set) to prevent oral fluids from irritating the exposed dentine. If after a few hours the bridge has not seated, the next stage is to use a silicone 'seating' cement which does not set fully and flows under pressure. These cements will retain the bridge for 24 hours while full seating occurs. Once full seating has occurred it can be cemented with a very weak temporary crown and bridge cement with a large proportion of modifier. Bridges cemented in this way may be left for days or even weeks to settle before being finally cemented. This should be done routinely with larger bridges.

The advantages of trial cementation are that, as well as possible improvements in marginal fit, the patient has a chance to become accustomed to the appearance and feel of the bridge, which can still be modified out of the mouth if necessary. Any problems with the occlusion are likely to show themselves and can be dealt with before the bridge is permanently cemented.

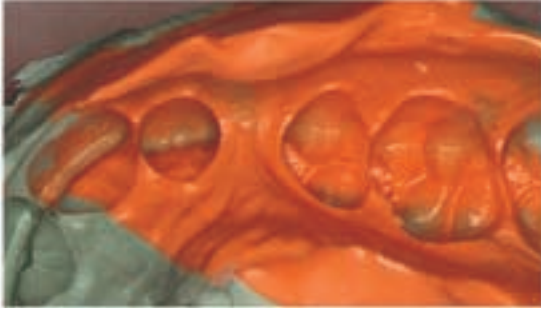Trial cementation should not be attempted with all-porcelain bridges or the minor retainers of fixed–movable bridges. Trial cementation is not possible with minimum-preparation bridges.

### Permanent cementation

#### Minimum-preparation bridges

This depends on the technique used to make the bridge and the luting cement. The commonest types are now those with grit-blasted fit surfaces luted with an adhesive resin, or Rochette (macro-mechanically retentive) bridges or splints cemented with a conventional, chemically cured composite material. These are used when it is likely that they will have to be removed atraumatically.

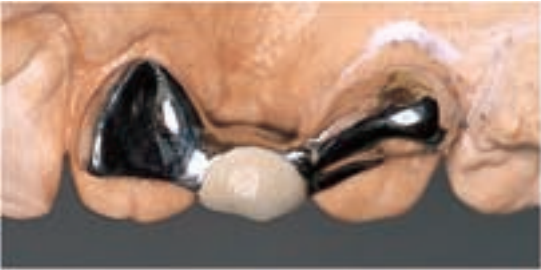Figure 11.10 shows the luting process for a grit-blasted bridge.

**Figure 11.10**

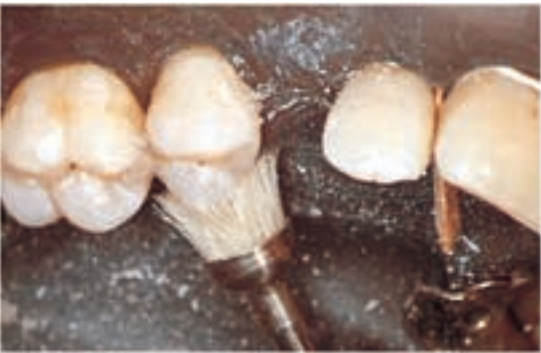Clinical technique for a minimum-preparation bridge.

A fixed–fixed design was used as the canine pontic was in occlusion in lateral excursion. It was decided that a cantilever bridge supported by either abutment would not be sufficiently robust to withstand the occlusal forces.

*a* The working impression.



*b* The metal framework and pontic on the model. This is tried in the mouth and adjusted before etching or sandblasting. It should not be retried after etching, or the delicate etched surface will be damaged. The design is fixed–fixed because the tooth being replaced is an upper canine that will be in occlusion in lateral excursions. A cantilever bridge from the premolar would not have been adequate with this occlusion, and there was insufficient space to make a movable connector in the lateral incisor without excessive tooth preparation.



*c* Polishing the abutment teeth with pumice and water after applying rubber dam.

### Summary of clinical techniques for minimum-preparation bridges

The stages in the construction are usually as follows (Figure 11.10):

#### First appointment

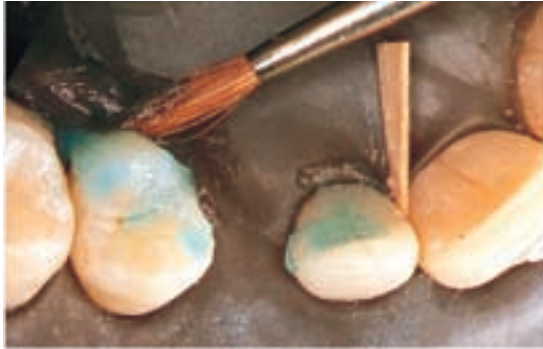- Thoroughly scale and polish the abutment teeth (and the remainder of the mouth of course)
- Carry out any necessary tooth preparation

- Take an accurate working impression in an elastomeric material and other records, for example the shade and an impression of the opposing teeth – although these should have already been done at the planning stage.

#### Laboratory stage

- Make the metal framework and pontic – the pontic is usually metal–ceramic. Grit-blast the fit surface of the retainer(s).

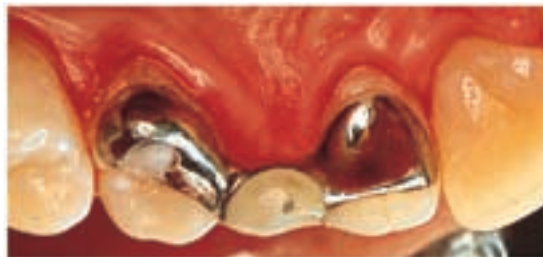



d Phosphoric acid gel applied carefully with a paint-brush or with a syringe to the areas to be covered by the retainers.



e Luting the etched bridge with a chemically cured composite specially made for the purpose. It would have been a good idea to place some floss between the abutment and the adjacent teeth before cementing the bridge. Pulling this through the contact points before the cement set would have helped to remove excess cement. If the bridge had been sandblasted and luted with an adhesive resin, the margins would be coated with gel to exclude air while the cement set.



f Immediately after removing the rubber dam.

### Second appointment

- Try in and if necessary adjust the bridge
- Re-grit-blast the fit surface with a chair-side grit-blaster, or if one is not available, it is worth returning the bridge to the laboratory if the fit surface has been contaminated with saliva or rubbed too hard against the tooth surface. *Not taking care over this stage is one of the commonest causes of failure of the bond*
- Re-polish the enamel surfaces to which the bridge is to be cemented, apply rubber dam and acid-etch the enamel surfaces (if the luting cement used requires this)
- Cement the bridge with a bonding resin made specially for the purpose, and remove excess cement from the margins
- The set of some bonding resins is inhibited by air and so a water-soluble gel is applied to the margins until the bonding resin is fully cured
- The manufacturer's setting time must be strictly adhered to and very firm, very still pressure applied for the whole period. If your fingers do not go white and hurt a bit you have not done it properly. *Slight movement of the bridge while the cement is curing is another common cause of failure.*

## Success with minimum preparation bridges

In the early days minimum-preparation bridges failed commonly and developed a poor reputation with some dentists. This attitude has lingered on to some extent and some dentists still do not make minimum-preparation bridges. However, all the surveys of properly made bridges with modern designs and materials now show good success rates and it is likely that these success rates will improve.

If you or one of your family needed a tooth replaced, would your first choice be a minimum-preparation bridge, a conventional bridge or an implant?

Minimum-preparation bridges only work if they are done properly but then they work well. Both authors of this book have made minimum-preparation bridges which have been successful for more than 20 years.

The golden rules for success are:

- Proper control of moisture from saliva or the humidity of the patient's breath using rubber dam.
- A dry supply of air for the three-in-one syringe. Some air supplies are contaminated by moisture. This can be checked by blowing air at a clean sheet of paper. If the air supply is contaminated it should be repaired or an alternative air supply used.
- The bridge should be tried in before the rubber dam is applied and then re-grit-blasted immediately before bonding. If there is a laboratory on hand this is straightforward. If there is not then it is worth investing in a chair-side grit-blaster.
- Framework of adequate rigidity so that no flexing occurs.
- Well planned design – cantilevers and fixed–movable designs work better than fixed–fixed designs.
- Adequate bonding areas.
- Proper adjustment of the occlusion.

## The cementation of conventional bridges

This differs from crowns only in that with fixed–fixed bridges the surface area of the

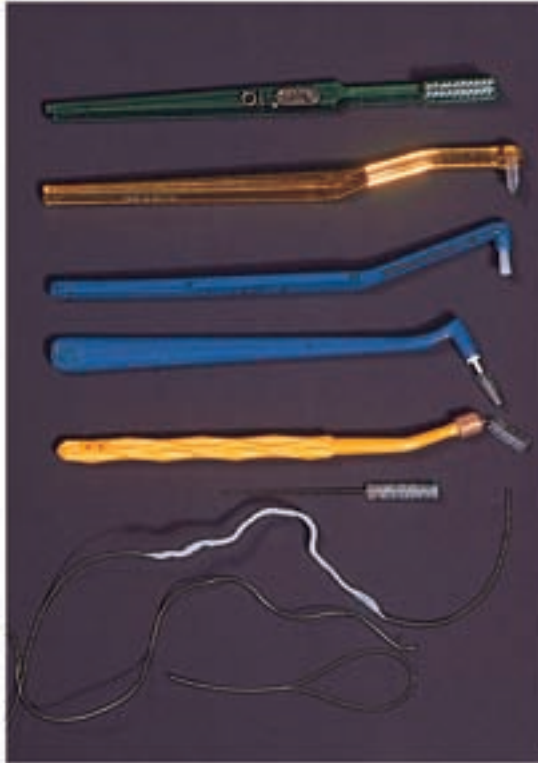combined abutment preparations is larger than an individual crown and so the hydrostatic pressure of the unset cement is greater. Greater force therefore has to be applied to seat the bridge fully.

Because of the difficulty of cementing large bridges and the need for a long working time before the cement starts to set, zinc phosphate cement is still the most popular for large bridges. Its working time can be extended considerably: the mixing slab is cooled, very small increments of powder are added at a time, and mixed for a long period (approximately 90 seconds). Ready proportioned cement in a plastic syringe is also available and is mixed in a mechanical vibrator. If the syringe is used straight from the refrigerator, a consistent, slow-setting, air bubble-free mix is obtained.

For preparations with nearly parallel walls the technician may use an additional layer of die-relief varnish on the axial walls. This increases the cement film thickness in this area without increasing it at the margins, and so reduces hydrostatic pressure during cementation. With multiple preparations it is also important that a dry field is maintained across all teeth. The dentist should always be in control of the seating of the bridge with finger pressure, getting the patient to bite into a cotton wool roll is not acceptable.

## Oral hygiene instructions and maintenance

This is particularly important with bridges, and in some cases the techniques will be entirely different from those the patient has been taught to date or for crowns. The areas where different cleaning techniques may be needed are between the pontic and the ridge and the gingival margins of the abutment teeth beneath the connectors. The technique will depend upon the design of the ridge surface of the pontic, the part of the mouth where the bridge is situated and the patient's manual dexterity. With ridge-lap and saddle pontics, superfloss, dental floss or tape should be threaded through an embrasure space and then passed under the pontic to clean it and the ridge. The furry section of superfloss makes cleaning under pontics much easier (Figures 9.5 and 11.11).

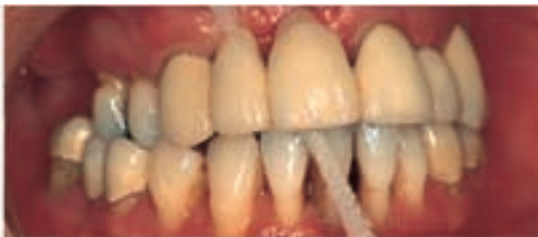

**Figure 11.11**

*a* Cleaning aids for use with bridges. This is only a small selection of products which are available. New cleaning aids are being developed and introduced all the time.

*From the top:*

- a soft toothbrush with two rows of bristles that can be used around dome and ridge-lap pontics;
- two single tuft interspace brushes – these are often too stiff except in very large open embrasure spaces;
- two 'bottle' brushes with multiple small lateral tufts that are useful for medium-sized embrasure spaces;
- a 'bottle' brush with a simple wire handle;
- superfloss, the most useful of the bridge cleaning aids – this has a stiffened end, right, and a furry section that is very useful for cleaning under pontics, and especially under smooth saddle pontics;
- regular floss, which can sometimes be passed through embrasure spaces to clean under pontics; but when this is difficult it is used in conjunction with;
- a floss threader, a flexible nylon loop with a stiff end that passes easily between tight embrasure spaces.



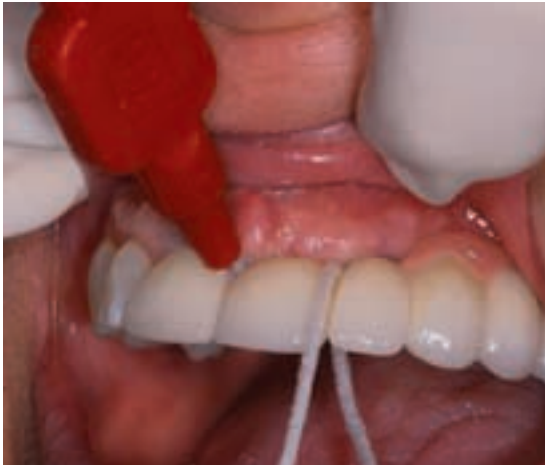*b* Superfloss being used to clean beneath the upper pontic.

Wash-through and dome-shaped pontics are usually cleansable entirely with the toothbrush, although in some cases a bottle brush is better.

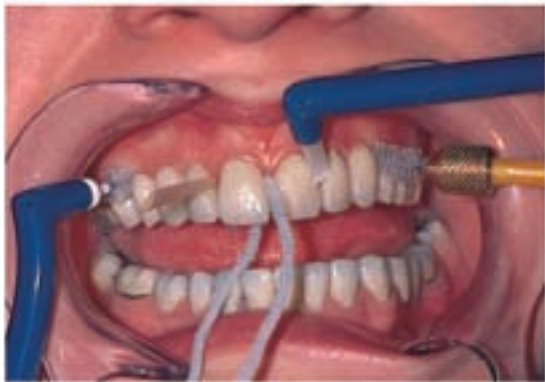Oral hygiene instruction should be given at the same appointment as the bridge is cemented. The patient should be seen again in 1 or 2 weeks to ensure that the new cleaning techniques are successful. At this stage it may be helpful to use disclosing tablets or solutions. At the same

appointment the occlusion and the retainers should be checked.

It is advisable to see the patient at regular intervals when the full range of checks of margins, gingival health, cleaning, occlusion and the mechanical integrity of the bridge are made. Chapter 14 deals with repairs and modifications to bridges where these checks reveal any problems.



c Superfloss being used in an embrasure space together with a different design of interspace brush (the TeePee brush).



d The clinical use of some of the cleaning aids shown in *a* and *b* – they would not normally all be used at once!

**WWW.HIGHDENT.IR**

همیار دندانسازان و دندانپزشکان

## **Part 3**

# **Implants, splints and maintenance**

---

[WWW.HIGHDENT.IR](http://WWW.HIGHDENT.IR)

همیار دندانسازان و دندانپزشکان

## 12

## Dental implants

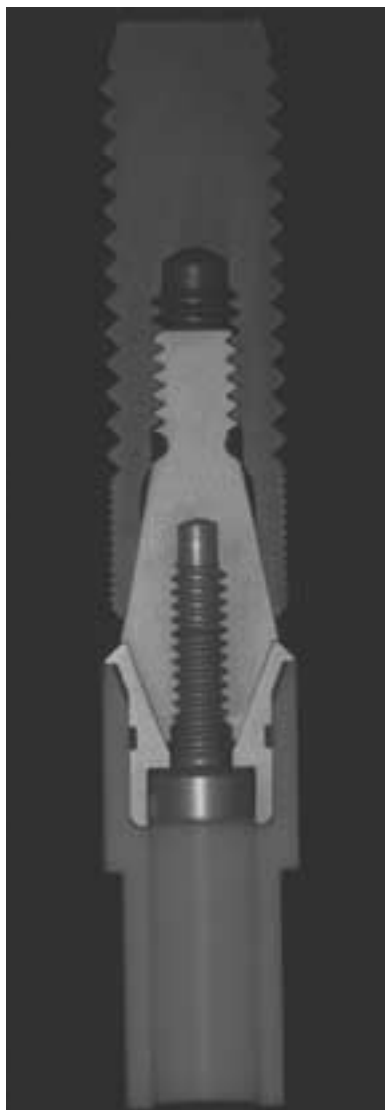
**The purpose of this chapter**

This chapter is not a comprehensive text on the use of titanium osseointegrated implants but is intended to give sufficient information to allow the reader to make reasoned decisions regarding the alternative techniques to replace a missing tooth or teeth. A second purpose is to allow dentists to properly inform patients regarding choices and maintain patients who may have implants. The choice of an implant-supported restoration as opposed to a bridge, denture or nothing must be made with the patient fully understanding the implications including the risks involved and possible complications. Implant dentistry is a specialist subject and dentists should be properly trained before offering them to patients. Dentists who are not properly trained or have only been on a short course of a few days should not place implants without supervision.

**Basic principles**

Pure titanium is highly bio-compatible and has an affinity for bone. If placed in direct contact with undamaged bone cells, fresh bone will be deposited on the titanium surface and this can be a stable, dynamic bond between bone and titanium. Dental implants are normally titanium cylinders with a coarse external thread and an internal threaded space which allows for a restoration to be attached to the implant (Figures 7.4a and 12.1). An implant restoration is produced in three parts:

- The implant (sometimes called the fixture), which is placed in the residual alveolar bone.
- The abutment, which is attached to and removable from the implant, extending through the soft tissues and giving support to the restoration.
- The restoration, which can be a single tooth crown, a bridge or a removable denture.



**Figure 12.1**

A section through an Astra implant, representative of implants with a conical or internal connection between implant and abutment. The basic components are similar to those described in Figure 7.4a.



The implant is placed into the bone and is normally left for 3 months to allow the bone to grow on the surface before the abutment is attached and the restoration placed so that it is stable enough to be able to resist occlusal loads. Treatment therefore normally extends over several months and involves surgical and restorative stages.

### Osseo-integration

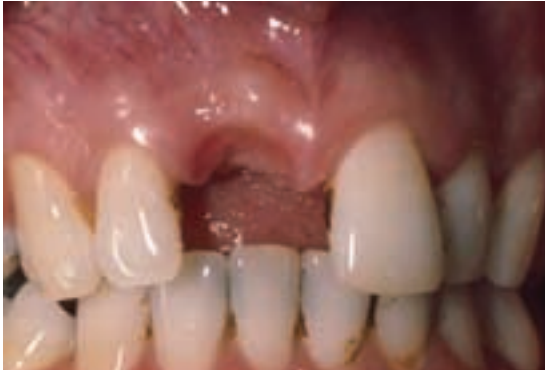The process whereby the titanium implant is fused into the alveolar bone is termed osseointegration. It is a process similar to ankylosis with a direct physical attachment between titanium and bone. The surface finish of the titanium surface is important in affecting the speed and degree of bone apposition on the titanium surface with slightly roughened surfaces (40–80 microns), similar to sandblasted or acid-etched surfaces working better than very smooth or very coarse surfaces. The following features affect the integration process:

- The bone must be in very close contact with the titanium on insertion, so the hole cut to receive the implant must be an exact size so the implant is a tight fit.
- The titanium surface must be uncontaminated. Commercially pure titanium rather than alloys or other metals integrates with bone best.
- The bone must not be damaged, particularly by heating while the hole is prepared, as this will damage the osteoblasts and prevent osseointegration. A rise of only 3–4°C above body temperature may be detrimental and so copious irrigation and the use of gentle pressure on sharp drills is essential when the bone is being drilled.
- The volume, density and vascularity of the bone are important. There needs to be adequate bone to surround the implant on all aspects. Very dense bone is easily heated on preparation and may well be avascular and it can be difficult to achieve integration. Equally very atrophic bone with little density can also be avascular and affords little support for the implant. Patients who smoke heavily often have less vascular alveolar bone and have been shown to have a higher rate of implant failure.
- During the osseointegration process the implant should be stable, as movement (particularly if it is subject to occlusal loads) will prevent bone formation and lead to a fibrous union between implant and bone. The external surface of the implant is therefore threaded to stabilize it immediately on insertion. Ideally the implant should extend from the more dense outer cortical plate of bone to the opposing side, as the internal medullary bone is often of poor density and offers little support for the newly placed implant.

### General indications for implants

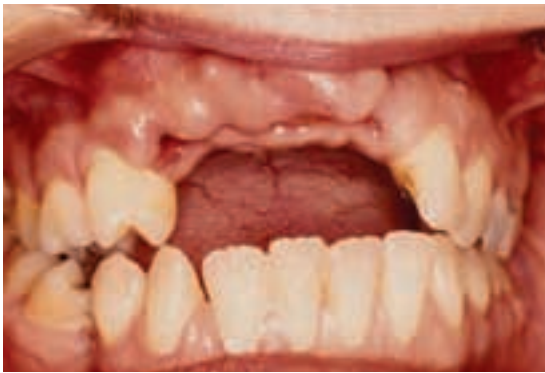As part of any decision process, all possible options for a situation must be considered. If a tooth needs to be replaced it is sensible to consider the simplest and least invasive option first such as a minimum-preparation bridge or a removable denture. If adjacent teeth are already crowned or require restoration they may benefit from the provision of crowns and therefore a conventional bridge becomes the option of choice. Implants become the prime option when:

- With a spaced dentition where placement of bridges is impossible without significantly changing the other teeth (Figure 12.2a).
- Where key abutment teeth are missing, for example if a canine tooth is missing, making conventional or minimum-preparation bridges difficult (Figure 12.2b).
- There are no suitable abutment teeth, for example with hypodontic patients where only deciduous teeth are present, or for a posterior distal free end saddle situation (Figure 12.2c).
- With long spans where conventional bridges may not have adequate support.
- When disturbance of extensive existing restorations becomes more complex or expensive than using an implant (Figure 12.2d).
- Where key potential abutment teeth are compromised, such as teeth with posts and cores present (Figure 12.2e).
- The adjacent teeth are unrestored (Figure 12.2f).

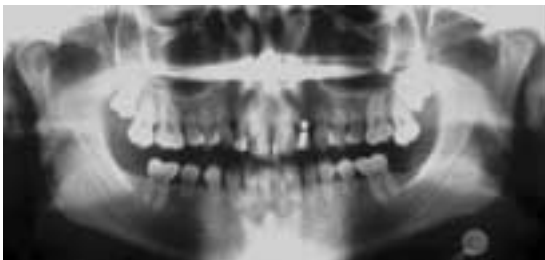

**Figure 12.2**

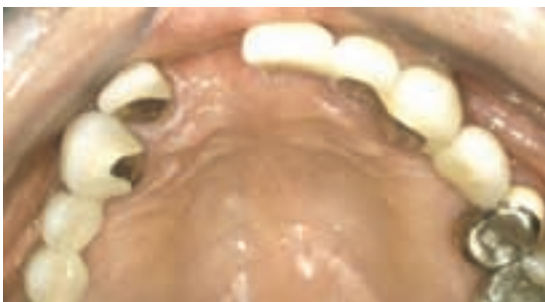*a* A missing right central incisor tooth in a patient who had spacing between their natural teeth. Replacement of the tooth with a bridge would necessitate alteration of the size of several teeth.



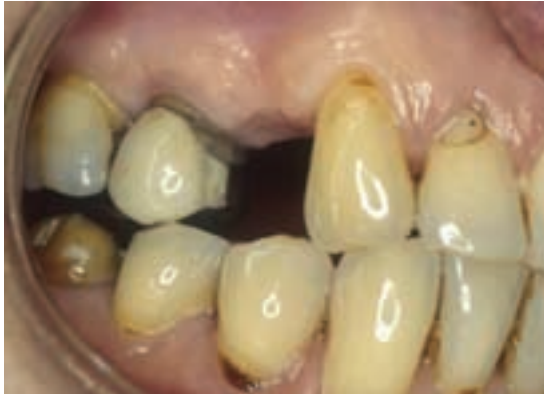*b* Following trauma this young patient has lost upper right canine to left lateral incisor teeth. If a fixed restoration is to be provided, implants will be necessary as there are insufficient suitable abutment teeth to retain a bridge.



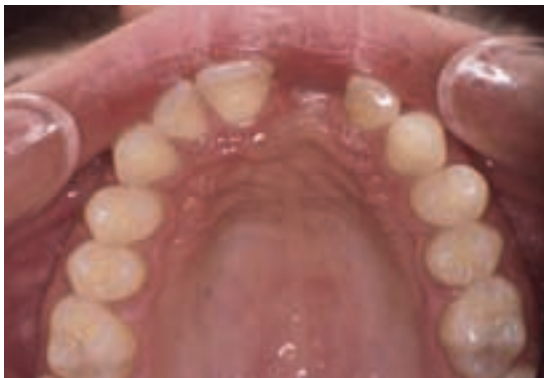*c* A panoramic radiograph of a patient with hereditary 'short root syndrome'. The upper left central incisor tooth has to be lost due to failed endodontic treatment and as the adjacent teeth are inadequate to support a bridge an implant is indicated.



*d* The patient has lost the upper right central incisor tooth but the remaining crowns and bridges are satisfactory. Replacing the missing tooth with a new bridge would involve removal and replacement of so many restorations that it is financially better to place an implant and leave the existing restorations untouched.



e A bridge would seem to be the obvious choice to replace this missing upper right first premolar tooth; however, the tooth behind is a stable post crown and the canine tooth in front is unrestored. The patient should be given a clear choice with advantages and disadvantages explained to allow them to decide between a conventional bridge, minimum-preparation bridge or a single tooth implant.



f A completely healthy unrestored dentition with a traumatically lost central incisor tooth. A conventional bridge would be considered too destructive. A minimum-preparation bridge could be highly successful. Many patients would wish for a single tooth implant despite the extra treatment and cost as the end result will be long-lasting and independent of the other teeth.

### General contraindications to implants

As for any dental treatment patients can be unsuitable for treatment for medical, physical or mental reasons. Specific concerns for implant treatment as opposed to other dental treatments include:

- Uncontrolled diabetic patients are more prone to surgical complications and carry a higher risk of long-term loss of implants.
- Following radiotherapy, patients may have less vascular bone if the area was subject to radiation.
- Patients with uncontrolled periodontal disease carry a higher risk of complications with implants.
- Heavy smoking. Over 20 cigarettes a day is considered high risk and the more years the patient has smoked compounds the problem. Cessation of smoking for a short period (a few weeks) prior to and after the surgical placement of the implant may help but a long-term heavy smoker who has stopped smoking for several years still carries a higher risk of failure than a non-smoker.
- Young patients should only be considered when they have stopped growing. This is normally by the age of 18 for women and up to 21 for men. There is no upper age limit for implant use.
- Patients with a strong bruxing habit may have more complications with dental implants but also with other forms of tooth replacement.

Many patients have unrealistic expectations for the outcome of their treatment and this can be heightened by the complexity and expense of implant treatment. It is essential that a very thorough planning process is undertaken and patients' expectations are understood so that mistakes are avoided. A removable denture may well restore a patient's appearance better than a complex fixed implant-supported restoration

## Choosing between implants and bridges

There are situations where the choice of restoration is clear-cut as the alternative options are not possible, for example if a central incisor tooth is lost in a patient with a spaced anterior dentition (Figure 12.2a). However, in most situations there are choices to be made and it is essential that the patient is fully advised about these options so that they can make an informed choice and give informed consent. This will include likely lifespans of the restoration, the implications for failure, the length of time the treatment will take and its cost. It should never be assumed that a patient cannot afford an implant and if the dentist does not provide implant treatment it should still be offered to the patient and an appropriate referral made.

## Designs of dental implants

Many different manufacturers produce implants and claim advantages for certain design features. Care should be taken to use an implant system that is well researched with published studies and has a good infrastructure of training and support. Many patients have implants placed that have become difficult to maintain over the years as implant manufacturers withdraw products or change designs.

Implants are produced in a variety of diameters ranging from 3 mm to 6 mm with the average size being 3.75–4 mm in diameter. The narrow diameter implants are used for smaller spaces but are mechanically weaker so cannot be used in high stress areas. Wider implants have greater mechanical strength and a larger surface area for

osseo-integration so are indicated for high stress areas where adequate bone volumes allow.

Implants can also vary in length from 6 mm to 20 mm, the most commonly used sizes being in the 9–13 mm length. The longest implants are not necessarily the best as they may be harder to place and cooling the burs during preparation is difficult. Implants less than 10 mm in length need to be splinted to other implants to survive.

Variations in the external surface have already been covered and the difference between systems may well be over-emphasized by manufacturers.

The fixation of the abutment to the implant also varies between manufacturers. Some have a flat top with an anti-rotation projection that the abutment fits over (see Figure 7.4a). An abutment screw then clamps the two parts together. Alternatively, the implant can have a recess (normally a cone shape) into which the abutment seats (Figures 12.1a and 12.3). Once again an abutment screw holds the two parts together although the mechanical interlock of the abutment to the implant places less reliance on the screw.

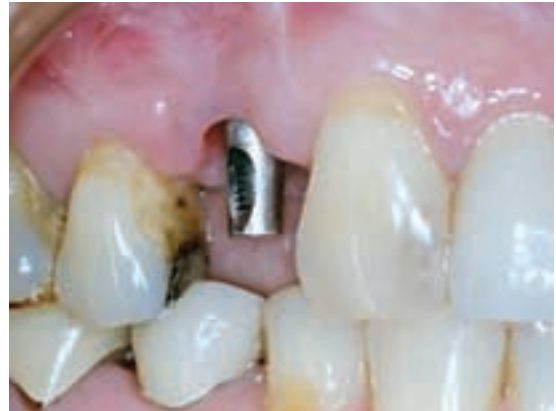Most implants are designed to be entirely embedded into bone and the part that extends through the mucosa is the detachable abutment, known as the transmucosal abutment (TMA). These implants are either left buried under the mucosa and later accessed with the TMA attached at a second stage of surgery or they are placed with the TMA already attached, i.e. a one-stage surgical approach (see later). An alternative implant design is for the transmucosal portion to be part of the implant, so this is already present when the implant is placed and these implants are therefore always used as a one-stage surgical approach (Figure 12.3).

## Abutments

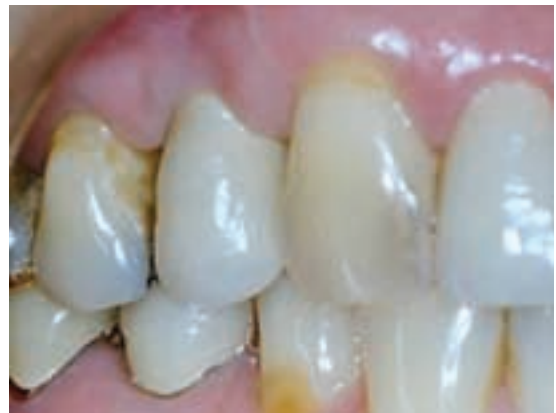The restoration is attached to the implant by the abutment and these can be designed so the restoration is screw- or cement-retained and this will have a direct effect on the ease with which the restoration can be retrieved, as screw restorations are completely predictable, whereas cemented restorations may be difficult to remove from the mouth if the cement has not failed. The abutment can either be prefabricated by the manufacturer (Figure 12.4) or an abutment can be



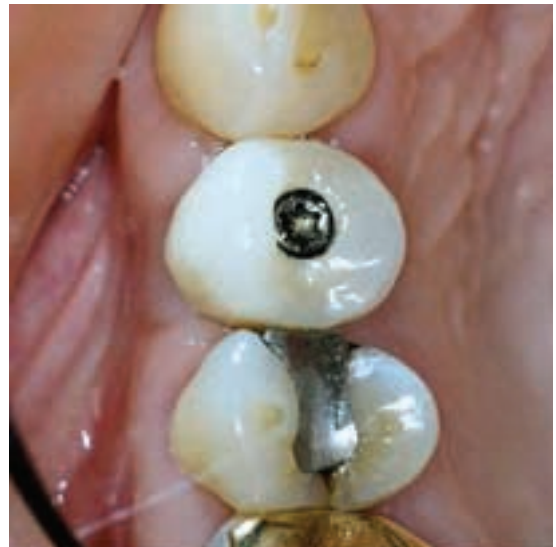a



b



c



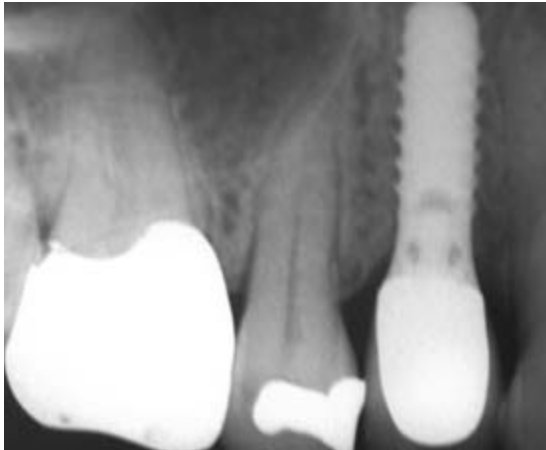d

**Figure 12.3**

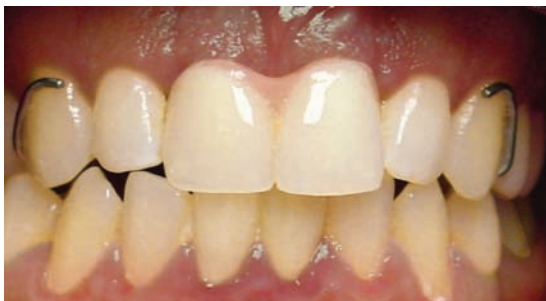a A Straumann implant which is a one-piece threaded implant with polished transmucosal portion. Made of titanium, the roughened part is placed in the bone and the polished part will extend through the gingiva. An abutment will internally attach to the implant to retain the restoration in a similar way to the previous designs of implant.

b A Straumann implant used to replace an upper first premolar tooth. A titanium abutment has been attached.

c and d The completed crown is screw-retained for ease of removal if required in the future. The screw hole visible on the occlusal surface will be restored with composite filling material.

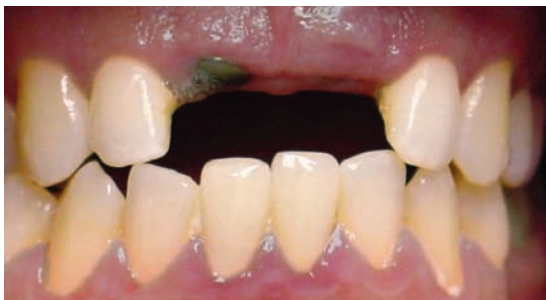

e A periapical radiograph showing the completed restoration.

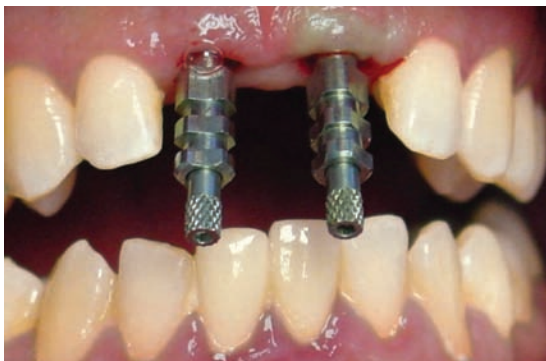

**Figure 12.4**

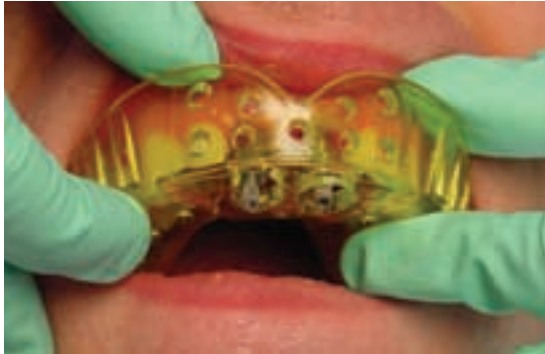a Missing central incisor teeth replaced temporarily with an acrylic partial denture whilst implants are integrating.



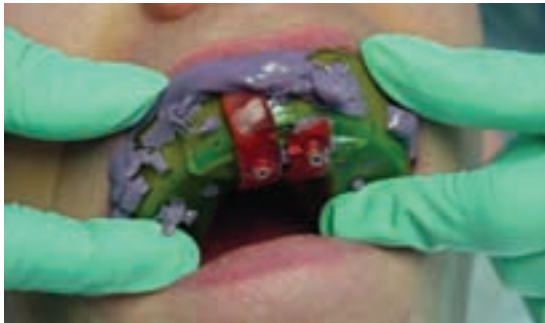b The healing abutments are just visible.



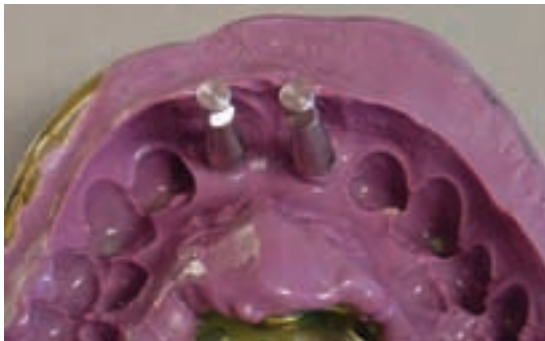c Screw-retained impression copings are attached to the implants.



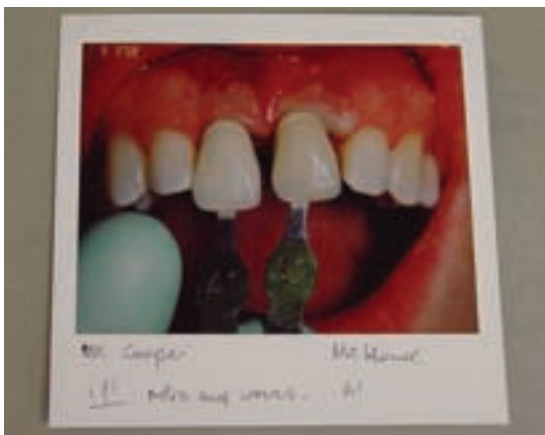d A stock impression tray is modified so that the pins holding copings project through the tray.



e An elastomeric impression material is syringed around the coping (in this case Impregum) and the tray is filled and seated into place so that the impression pins are visible.



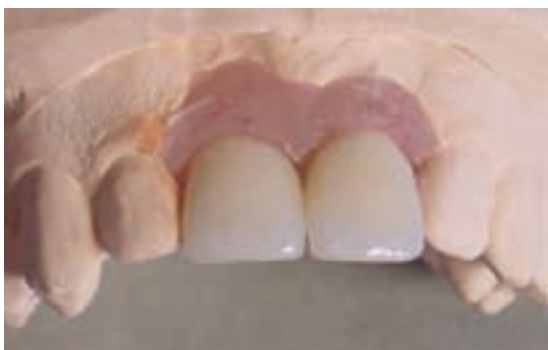f Following set of the material the pins are unscrewed and the copings will come out in the impression on withdrawal from the mouth. Replicas of the implants are attached to the copings ready for making the master cast.



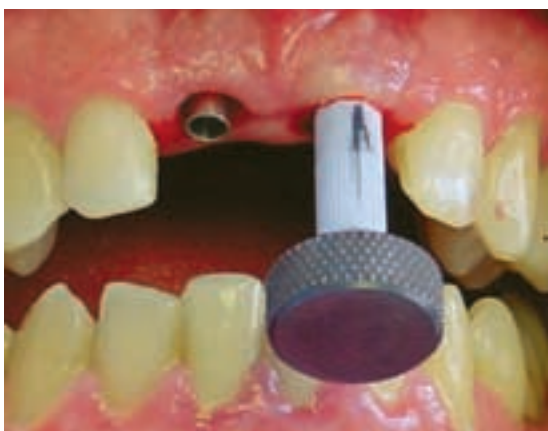g Records of the shade are taken; in this case a Polaroid photograph was taken with shade tabs in position.



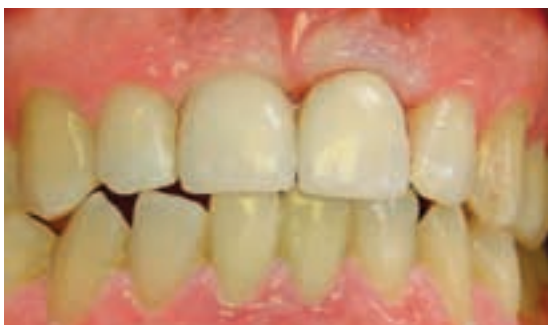*h* On the master model the gingival portion is formed in a removable silicone material to allow access to subgingival areas and make it possible for the restorations to emerge through the gingiva in a natural way.



*i* Completed metal–ceramic crowns.

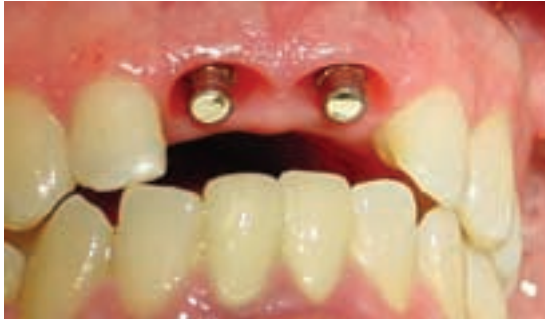

*j* The abutments are placed in a holder and seated into the implants. The abutment screws are tightened.

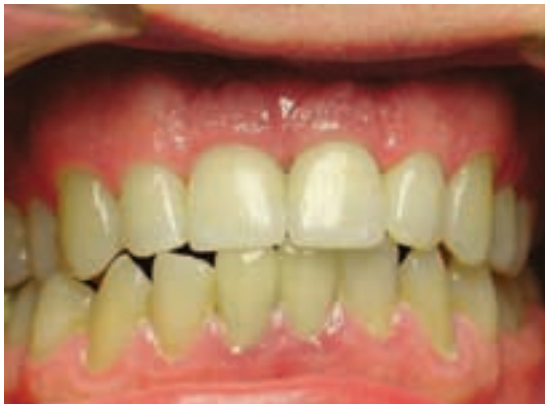

*k* On initial seating the gingiva are put under pressure as demonstrated by blanching. The occlusion is checked and the crowns are temporarily cemented.

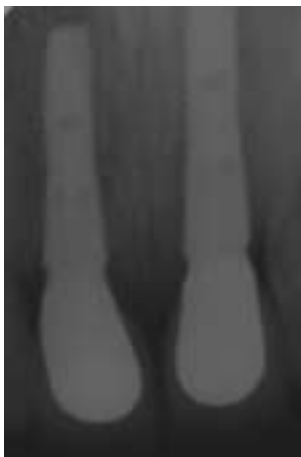



*l* Two weeks later the crowns are removed and a healthy gingival contour is evident. The abutment screws are re-tightened.



*m* and *n* The completed crowns following final cementation with periapical radiograph to verify fit and the position of the bone in relation to the implant for future monitoring.



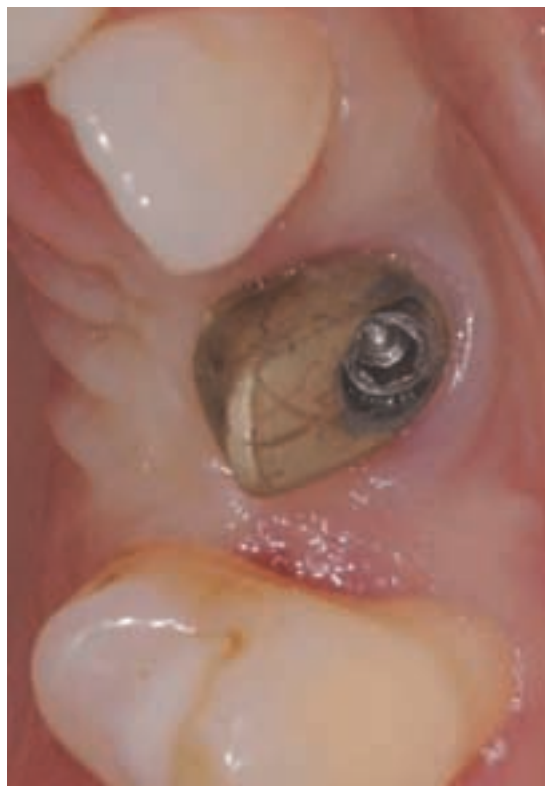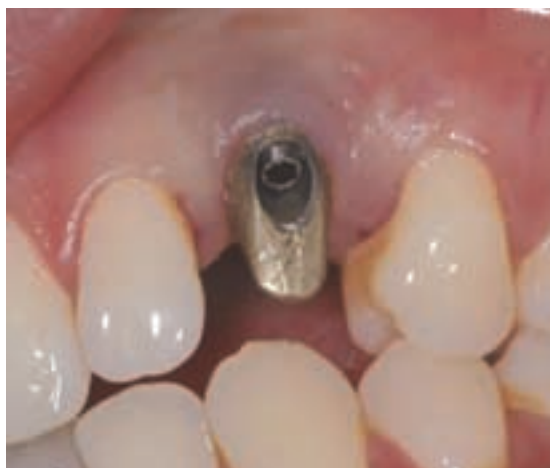made in the laboratory or prepared in the mouth, depending on the clinical situation. These abutments are commonly known as customized (Figure 12.5). Ideally, with an implant in the correct position it is easier to use a prefabricated

abutment where the exact fit of the restoration can be ensured rather than laboratory-made abutments which require more complex technical work and are more akin to conventional crown and bridge procedures.

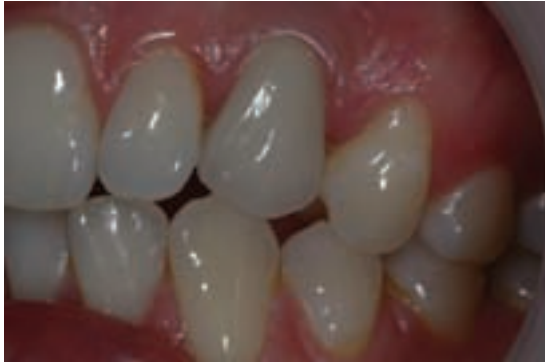

**Figure 12.5**

*a* A customized abutment made from a wax-up and gold casting technique allows a change in angulation for the restoration compared with the implant. The abutment screw projecting at the base will screw into the implant so shows the implant's orientation. The crown will have a path of insertion of about  $30^\circ$  compared to this.



*b* and *c* The abutment is screwed into place and the change in orientation between implant and crown is clearly seen, bringing the crown back into alignment with the adjacent teeth. A crown placed in the orientation of the implant would have resulted in a severe buccal position.



*d* The completed crown has a good contour, position and appearance.

### Screw- versus cement-retained

Screw-retained restorations are highly complex when used for conventional crowns and bridges and so are rarely seen. As there is significantly more space with implants in which to accommodate the metal framework needed to accommodate the screw, and the implants are in a static position, the use of screw retention has become common for implant restorations. The advantages of screw retention are the ease of removal and the stability of the restoration while in use. Screw retention demands a very accurate fit for the restoration onto the abutment so that the screws are not placed under tension during tightening and this places significant demands on the skill of the dental technician (Figure 12.6).

Prefabricated components are used with a gold cylinder incorporated into the restoration forming all of the connection onto the abutment so that a precise fit is achieved (Figure 12.6e). Sometimes the hole on the occlusal surface may compromise the appearance or is important in occlusal contact. Abutments with pre-determined alterations in angulation (angled abutments) can be used to overcome this (Figure 12.6g).

Laboratory-made abutments are normally constructed by the dental technician in much the same way as a conventional post and core is made. The abutment is made as though a crown preparation had been performed onto a metal core with margins and near parallel sides (Figure 12.5a). A 'conventional' crown or bridge is then constructed which is cemented onto the

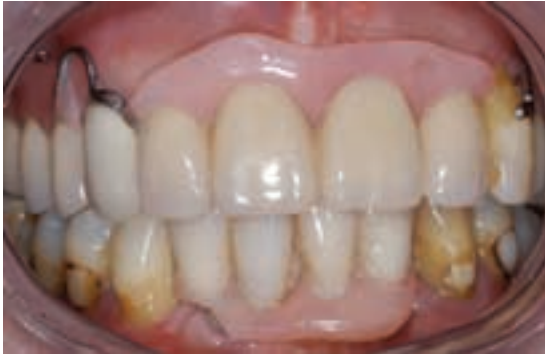abutment. If the restorations may need to be retrieved at some time in the future soft or provisional cement can be used. This technique does not require quite such an exact fit for the restoration and small amounts of misfit can be accommodated by the cement layer. It also does not have screw holes showing and so appearance is not compromised (Figure 12.5d).

The soft tissues lying over the implant may be of different thicknesses around and between mouths. Abutments are therefore made with differing heights so the margin for the restoration can be placed subgingivally to enhance the appearance. Screw-retained restorations are routinely placed 2–3 mm subgingivally as there are no concerns about marginal gaps or excess cement. Cemented restorations are normally placed 1 mm subgingivally where appearance is paramount but this should not be confused with margin placement for crowns on teeth, where taking impressions to obtain an accurate fit is a concern, together with the risk of leakage and caries if the subgingival margin is not so accessible for cleaning.

Abutments can be made from titanium, cast gold or high strength ceramics such as alumina oxide or zirconia.

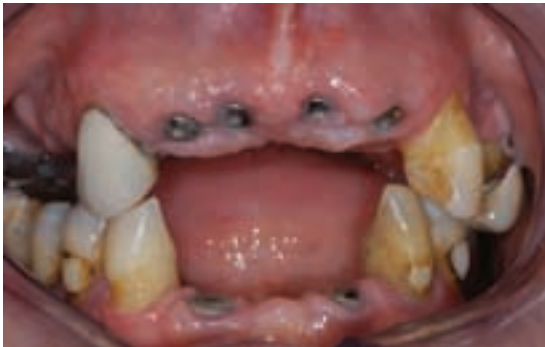### Restorations

Single tooth restorations are normally cemented metal–ceramic or all-ceramic crowns. Where

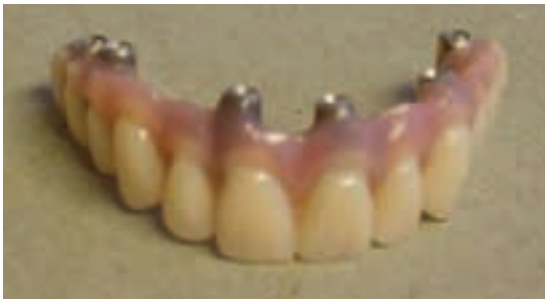

**Figure 12.6**

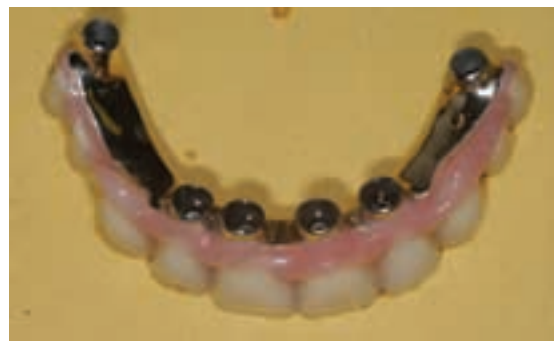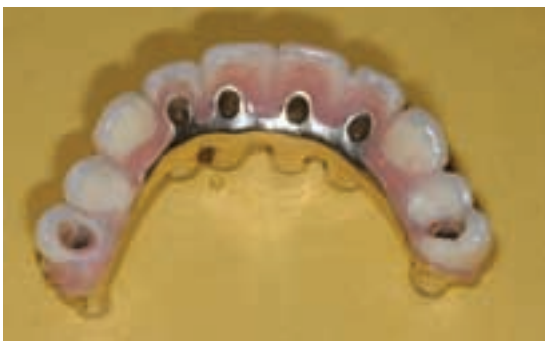*a* A patient being provided with a full arch upper implant-supported bridge and lower anterior bridge. During treatment the canine teeth have been retained to stabilize the partial denture.

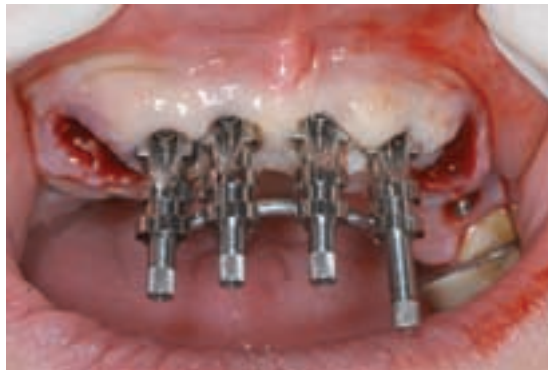

*b* Six implants have been placed in the upper jaw in the position of the incisor teeth and the second premolars. The healing abutments are visible.

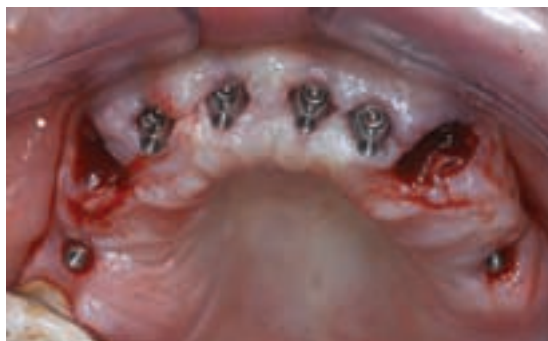

*c, d and e* The completed bridge made with a cast gold subframe and pink heat-cured acrylic and acrylic denture teeth. This could have been made from titanium and have a porcelain or composite tooth portion. The bridge is screw-retained and access holes for the bridge screws are visible on the palatal and occlusal surfaces. The fit surface incorporates ready-made gold copings which will fit exactly onto the abutments.

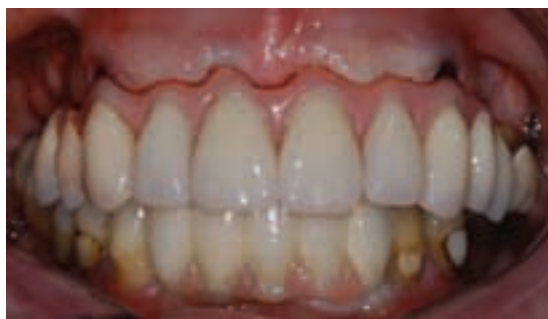



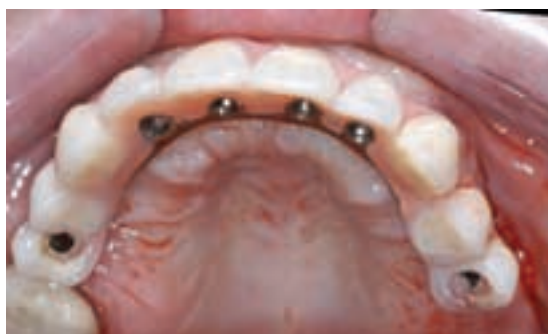*f* A jig is used to transfer the abutments to the mouth in the same position as they were on the model so the bridge will be an exact fit. The canine teeth have been extracted.



*g* The abutments in position.



*h* Completed bridge immediately on insertion. The pink acrylic maintains the appearance of normal gingiva without excessively long teeth but still allows access for cleaning.



*i* The bridge retaining screws allow easy removal of the bridge for maintenance in the future.

appearance is not paramount, for example a molar tooth, screw retention is more acceptable.

Multiple implants can be linked either with bridges or, if there are no pontics, splinted crowns. Longer implants can help to support shorter ones or allow for cantilever pontics. Conventional style metal-ceramic restorations are normally provided but with extensive bridges where this may be complex to produce and maintain, a gold or titanium frame can be made with the tooth portion made from ready-made acrylic (denture) teeth or laboratory composite (Figure 12.6c). Such restorations will be easier to maintain if wear or fractures occur in the future compared with porcelain restorations.

Implants can also be used to support complete or even partial dentures. This may be a cost-effective treatment as fewer implants are required or for those who need the lip support of a removable denture. The implants can be linked with a gold bar and the denture has clips on the fit surface which engage the bar to provide retention. Alternatively, individual ball abutments can be placed onto the implants and the denture retained with internal ring clips. Lower overdentures tend to have fewer complications than upper dentures and require fewer implants.

## Implant survival

Implants have been extensively investigated since their initial development and many long-term studies extending 10 years and more have been published. Most studies concentrate on implant survival as well as restoration survival, the latter having a higher survival rate where extensive bridges are supported by multiple implants, as loss of an implant may not result in loss of the restoration. Implant loss can occur either at the time of or soon after placement, normally due to surgical complications. They may also fail at the time of loading due to lack of osseointegration which failed to develop during the healing, perhaps due to movement of the implant during healing or failure of the bone to grow.

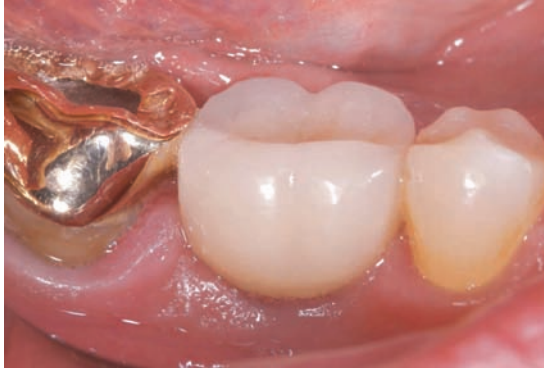Finally implants can fail years later following apparently successful osseointegration. This may be due to mechanical overloading of the implant (which may show as fracture of the implant) or progressive bone loss around an implant termed 'peri-implantitis', a process not dissimilar to

periodontitis. This may result from overload, poor oral hygiene around the implant, the presence of other periodontal lesions on adjacent natural teeth or a combination of all these factors. Heavy smoking may contribute to bone loss around an implant. A rate of bone loss of 0.2 mm per year has been postulated as acceptable from long-term studies when averaging out loss from many implants. This disguises the fact that most implants achieve a stable state where no bone loss can be demonstrated over many years. Any degree of loss is therefore unusual and should be investigated, monitored and treated, as it is not desirable.

Failures of the restoration above normal wear and tear are mechanical in nature such as screw fracture, screw loosening, or de-cementation or fracture of the superstructure, particularly porcelain fracture. This particular form of failure can commonly be seen with implant-supported restorations, as they can be subject to excessive loads as patients have no normal proprioception from implants and there is no protective effect from a periodontal ligament. Retrievability of the restoration so that it can be repaired is therefore essential.

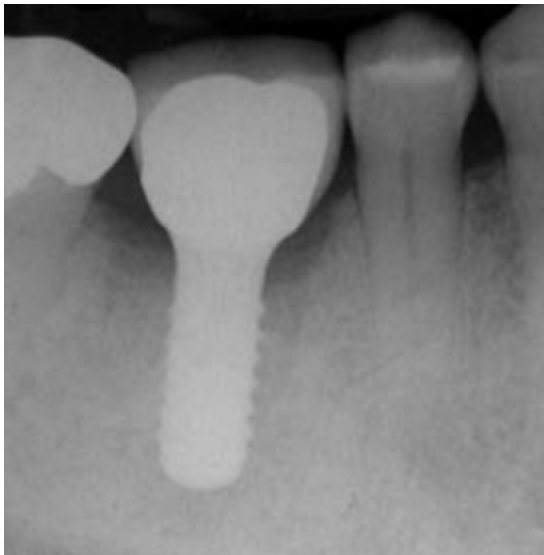
Single tooth implants have reported success rates varying from 100% survival at 5 years to failure of up to 15% within 2 years; for example with single missing lower molar teeth. All of this will depend upon the site and size of the missing tooth, the size and length of the implant that can be placed into the site and the occlusal load. Ideally the implant should be as long as possible and at least 10 mm in length. Increasing the diameter of the implant does not necessarily improve success rates, as there has to be sufficient thickness of the bone to support it. Lower molars are at greater risk as the implants may well have to be short to avoid the inferior dental canal. The length of the span may well be large compared to the width of the implant and the greater loads compared with anterior teeth. Where possible two implants linked together are a better solution for a missing molar tooth (Figure 12.7).

Bridges supported by implants can range from full arch bridges supported by three to eight implants to shorter spans with perhaps only two implants. Linking multiple implants allows for use of shorter implants splinted together and if more than two implants are used and one fails it may be possible for the bridge to survive, perhaps in a shorter form using the remaining implants. If



**Figure 12.7**

*a* and *b* A single lower molar tooth replaced on a wide diameter single implant. The potential for overloading the implant is evident when comparing the size of the tooth to the implant.

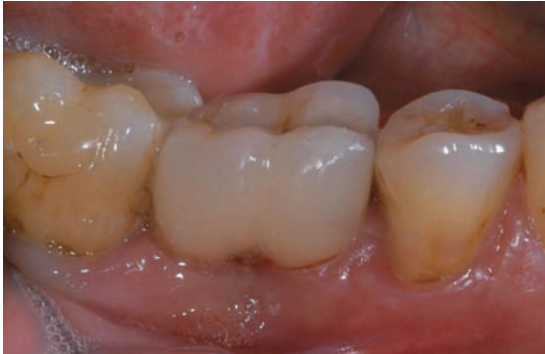

only two implants are used at the start, the loss of one implant invariably results in loss of the whole restoration.

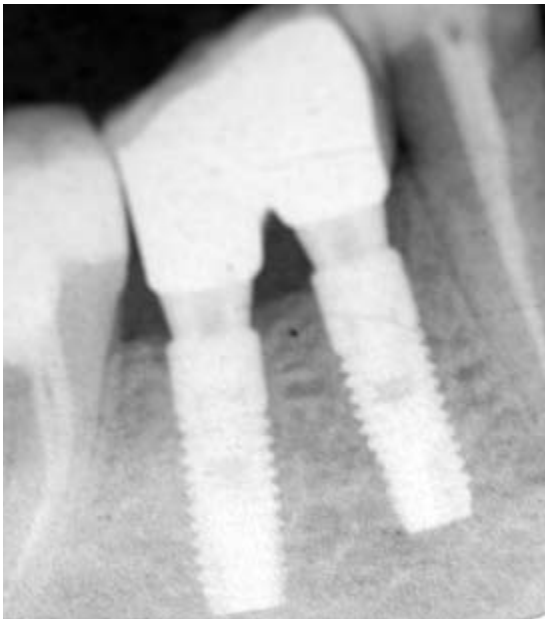Several long-term studies have monitored full arch fixed bridges for periods up to and beyond 15 years and show a success rate in the region of 85% for restoration survival.

Implant-supported overdentures have shown a generally higher rate of implant complications than implants used for fixed bridges and the overdentures will require ongoing maintenance of the retentive elements which is more than a fixed restoration.

Patients commonly ask how long an implant will last and great care must be taken to avoid the impression that implants will last forever – there is no evidence to support this claim. It is acceptable to inform patients that failure rates for properly planned and placed implants are low, comparable to or better than conventional bridges and that if failure does occur this should not compromise their remaining teeth (which is an advantage over conventional bridges). Patients in high risk groups or with inadequate bone volumes should be encouraged to try conventional treatment first. Patients should be warned



c and d A similar situation where two narrower implants have been used to support a lower molar tooth. This is more like a natural situation but may be difficult to clean and more expensive. At least 12 mm of space is required to place two implants.



that the restorations will wear out and require maintenance and replacement with time, but hopefully the implants themselves can be reused for a new restoration.

## Planning

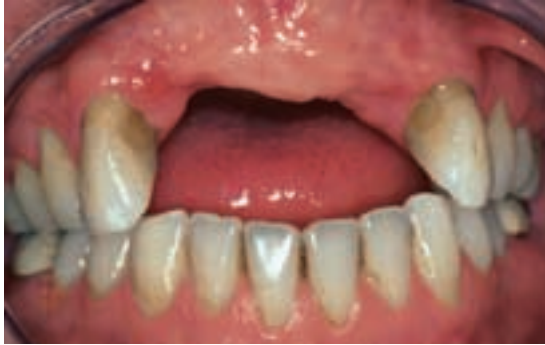It is often said that implant treatment is not in itself complex but the stage at which things can go wrong is in the planning and the decision to proceed with treatment. It is therefore essential

that thorough planning is carried out before an implant is placed. The restoration should be planned from the final result backwards so that the implant is placed to allow the final result to be achieved exactly as envisaged. All too often the implant is placed first and only then is consideration given as to how to restore it (Figure 12.8).

## ***Implant numbers and position***

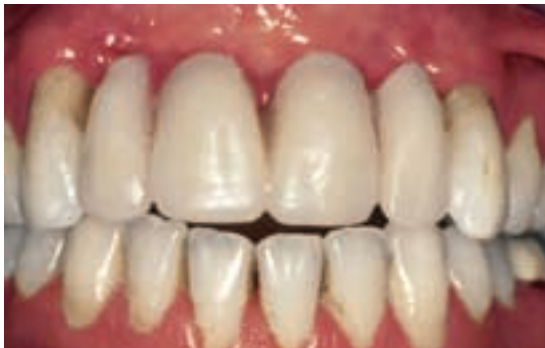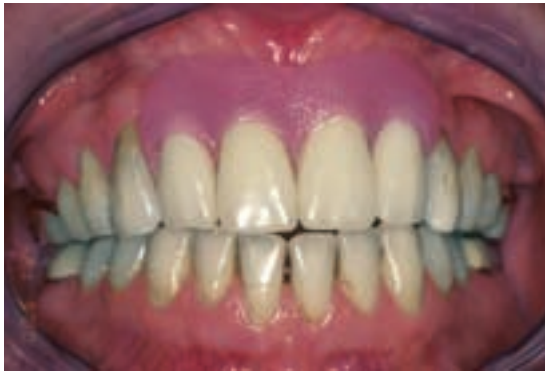As a general rule the following can be applied:





**Figure 12.8**

*a and b* Following loss of the upper anterior teeth this patient wears a partial denture with an extensive labial flange to replace the missing hard and soft tissues. This provides her with lip support and cannot be replicated in a fixed bridge as it would not be cleansable.

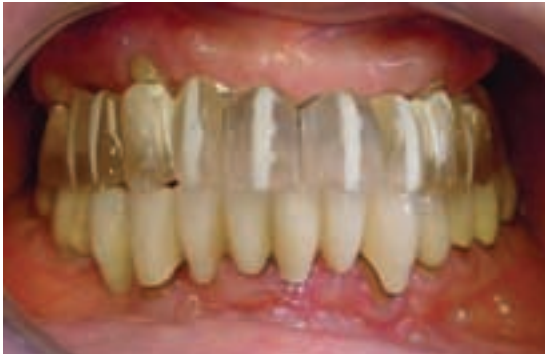

*c* A new partial denture is made without a labial flange and the pontics placed on the crest of the ridge to replicate the likely result expected from an implant-supported bridge. The patient can then assess the appearance and lip support provided before having implants placed.

- 1 implant can support 1 tooth
- 2 implants can support 2–4 teeth
- 3 implants can support 3–5 teeth.
- Full arch upper jaws require 6–8 implants
- Full arch lower jaws require 4–6 implants.


The diameter and length of the implant is clearly important and short implants below 9 mm should

only be used with care and protected by splinting to other implants. A space of 6–7 mm is required between adjacent teeth, measured at the minimum convergence along the entire length of the teeth including the roots. This gives only a 1 mm space between the implant and the adjacent tooth when a standard 4 mm implant is used and therefore there is no margin for error in placing

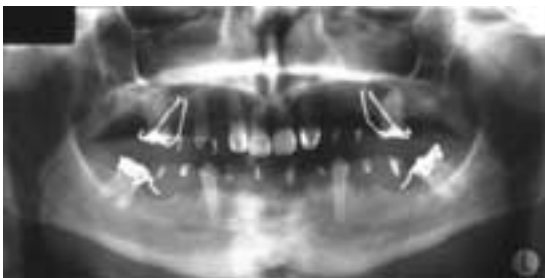

**Figure 12.9**

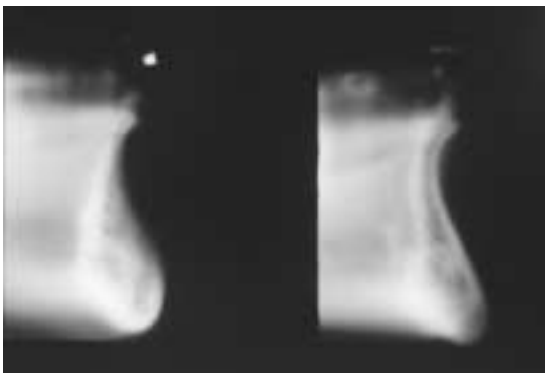
*a* A radiographic stent has been made by copying the existing bridge in clear acrylic and radio-opaque markers placed on the labial surface of those teeth where it is hoped to place implants.



*b* An image from a CT scan in the same patient. The marker from the stent can be seen in the lower left side and the section through the alveolar ridge allows measurement of height and thickness. This is a one-to-one image and the markers are 1 mm.



*c* A Scanora panoramic radiograph for a hypodontic patient with multiple missing permanent teeth. The radiographic markers are in the sites chosen to place implants. There appears to be adequate bone height in these sites.



*d* Sections through the mandible from the Scanora in *c*. These are magnified by the ratio 1:1.7. There is insufficient bone thickness to place implants and either alternative sites must be found or the patient will need bone grafting.

the implant. When implants are placed adjacent to each other the implant centres should be 7 mm apart to allow for bone and soft tissue to form between the implants. Careful measurement of the gap is therefore required.

The bone contour in the site where the implant needs to be placed is assessed visually and by palpation to check for bony undercuts and the thickness of the ridge. As at least 1 mm of bone is required all round the implant the ridge will need to be 6 mm thick. Special sectional radiographs are often required (Figure 12.9) to determine the thickness of the ridge. The height of the ridge is also assessed, particularly in relation to the adjacent teeth and gingival margins.

### **Lack of bone and grafting**

If inadequate bone or soft tissue is present at the site where an implant is to be placed this can be augmented by a graft. This increases the risk of complications and adds to the surgery required and may lead to alternative restorations being chosen rather than proceeding with implants. Bone can be harvested from other intra-oral sites such as the retromolar region, other edentulous sites or the mandible below the roots of the incisor teeth. In extreme cases the hip or cranium are used. The patient's natural bone works better than artificial materials.

### **Appearance**

However well an implant works, if it is in the wrong place resulting in a poor appearance the patient will not be happy with the result. The implant cannot be moved once it has integrated. It is essential that the patient is given a realistic understanding of the result that can be achieved, particularly if a degree of compromise from the ideal is going to be inevitable. The patient's provisional restoration can be used. If this is a removable denture it will need to be produced without a labial flange as this will not form part of the final implant restoration (Figure 12.8c). The tooth must be centred over the alveolar ridge where the implant is going to emerge. Often a denture will look better than a fixed implant restoration

as the denture is able to replace the missing soft tissue. If the diagnostic set-up is processed in acrylic this will allow the patient to assess the appearance and also the lip support provided without a flange before treatment is started.

A diagnostic wax-up of the desired result may be adequate for simple cases but these are difficult for patients to interpret and can make results look better than can actually be achieved.

### **Radiographs**

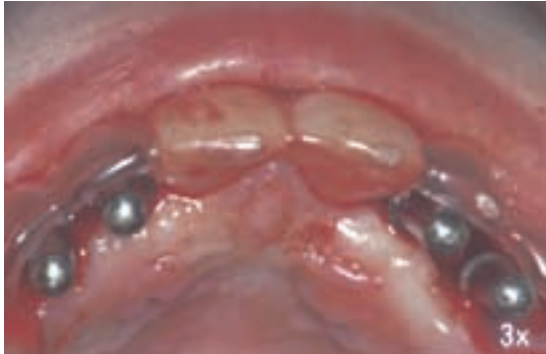For simple cases long cone radiographs may be adequate. These will not show the thickness of the bone or its contour. Where anatomic structures such as the inferior dental canal or the maxillary sinus need to be accurately imaged, detailed radiographs such as sectional tomography (e.g. Scan-ora) or computer aided tomograms (CT scans) will be necessary (Figure 12.9). A radiographic marker can be incorporated into the image using the diagnostic set-up and an acrylic stent and this allows the exact relationship of the bone to the desired restoration to be evaluated for accurate implant placement.

### **Surgical stent**

From the diagnostic set-up an acrylic surgical stent is made to accurately show the ideal position of the new tooth and allows the implant to be positioned so that this can be achieved. The stent fits onto adjacent teeth so it can be used during surgery with soft tissue flaps raised (Figure 12.10). Full arch or overdenture stents can be made by copying the complete denture in clear acrylic and cutting out the area where access is required for surgery.

### **Provisional restorations**

As the implant cannot normally be placed and restored immediately, most patients require temporary restorations while the treatment is being undertaken. Simple acrylic dentures are the easiest as these are easy to modify to fit over the



**Figure 12.10**

A surgical stent is used to guide the implant placement. Guide posts have been placed in the initial holes cut for the implants to verify their orientation. As the holes are not full size at this stage it is possible to change their angulation.

implanted area following surgery and the restorative phases. Alternatively minimum-preparation bridges can be provided, ideally of a perforated Rochette design so they can be removed easily. The pontic should be made from acrylic or composite so that it can be modified to accommodate the healing abutment when placed.

## Surgical procedures

Implants are normally placed using conventional local anaesthesia following exact planning. Patients should be advised that they may experience some swelling or bruising postoperatively and may have some difficulty wearing their temporary denture initially. If teeth are to be extracted this is normally carried out 6–12 weeks before the implant placement. With a small extraction socket or one where there is plenty of bone beyond the socket into which the implant will be placed, a short healing time following extraction will be acceptable to allow for soft tissue healing. More extensive sockets will require longer for bone healing to take place before the implant can be safely placed and be stable. Ideally the minimum time should be left so that the patient is with the temporary restoration for the least time possible and there is less chance for excessive shrinkage of the site to occur.

Implant placement is performed under strict aseptic techniques. Flaps are raised to identify the ridge, adjacent teeth and important anatomic structures (Figure 12.11). Using a series of drills with increasing diameter a hole is prepared to the

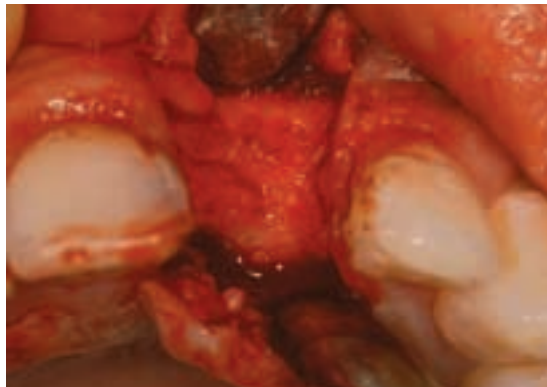
ideal depth and diameter under copious irrigation. The position, angulation and depth of the hole are continuously checked with relation to the surgical guide so that changes can be made before the final drill. The implant is then slowly screwed into the bone utilizing the self-cutting threads until it is in the correct position and stable in the bone.

## One stage

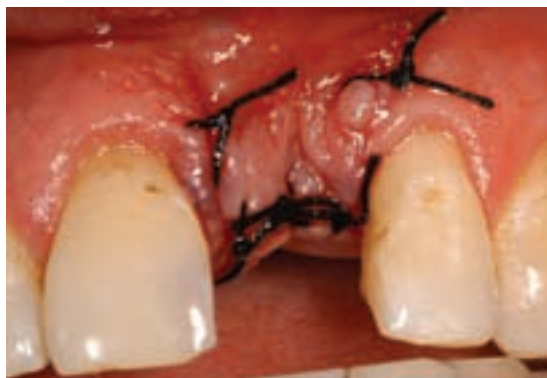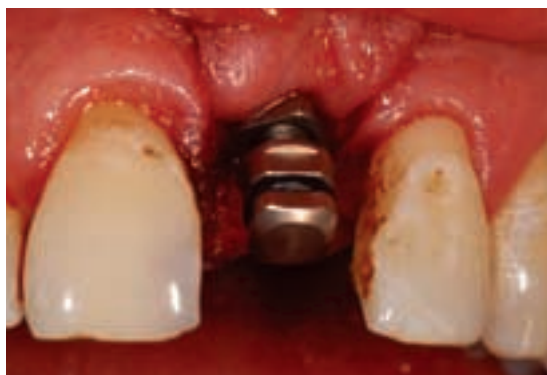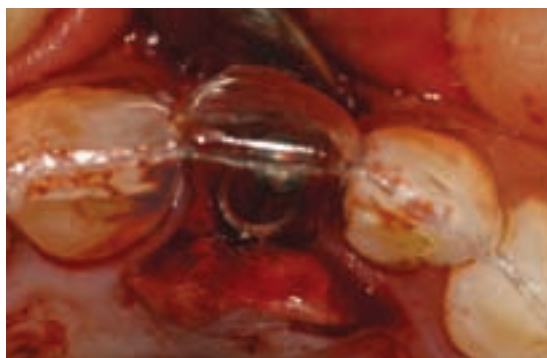
At implant placement a healing abutment is placed and the flaps are sutured so that the healing abutment is just projecting through the soft tissue. A healing abutment is a plain titanium cylindrical abutment which screws into the implant and holds back the soft tissue to create a soft tissue tunnel from the mouth to the implant head. Any temporary restoration should be adjusted so that the implant is not loaded. Once the soft tissues and bone have healed the implant is ready to be restored without the need for further surgery. This approach has become the most common as it reduces the surgical stages, and as long as the implant is protected from loading the success rates are comparable to the traditional two-stage approach.

## Two stage

After insertion of the implant, the hole for the abutment screw is sealed with a cover screw and the flaps are sutured over the area. Following a

**Figure 12.11**

*a-d* Some stages in the surgical placement of a single implant for a left central incisor tooth. A flap exposes the ridge and a surgical guide verifies the implant position. The implant mount seen in *c* allows the implant to be screwed into position with a high degree of torque and is then removed. A two-stage technique is employed and the implant has been buried to be exposed 3 months later.



healing period of 6–12 weeks a second stage of surgery is performed to locate the top of the implant, remove the cover screw and place a healing abutment. This technique requires extra surgery but encourages an uneventful healing with no loading to the implants during healing. It is recommended where bone grafts have been used or where protection of the implant from loading cannot be guaranteed.

### **Immediate placement/restoration**

It is occasionally possible to extract a root and immediately place an implant into the site. This can only be considered if dealing with an uninfected tooth and if the residual socket is smaller than the implant being placed, so the implant will be stabilized in sound bone, not sitting in the socket. Immediate placement carries an increased risk of failure and should only be considered where maintenance of the gingival contour is essential to preserve appearance. There may still be some gingival recession following immediate placement.

Where complete stability of a newly placed implant can be guaranteed, it may be possible to place a provisional restoration at the same time as the implant is placed. Again, this carries an increased risk of complication and care must be taken to ensure that the restoration is completely out of occlusal contact in all positions of the mandible. After the normal 3 month healing period the provisional restoration can be changed for the permanent restoration. In situations where providing a temporary restoration may be difficult or unacceptable to the patient this immediate approach may be considered but the increased risk must be fully explained to the patient and recorded in the notes.

### **Restorative procedures**

As discussed in the planning section, it is essential that the restoration has already been planned before the implant is placed to ensure its correct position. Even with such planning, variations in the implant position following surgery can be expected, as at the time of surgery the final

position of the implant is dictated by the shape of the residual bony ridge and the operator's ability to place the implant exactly as required.

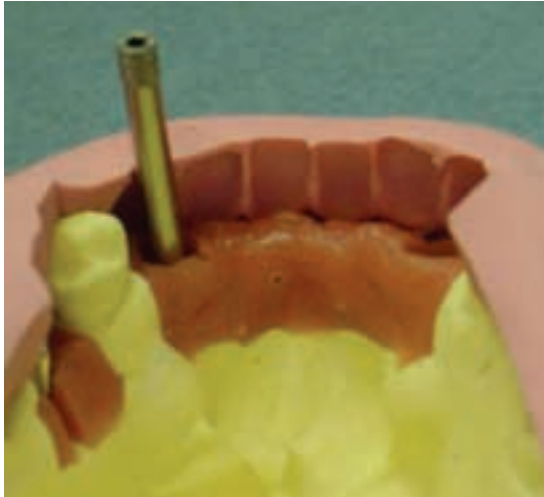
The restorative phase consists of choosing the abutment, taking accurate impressions, fitting the abutment and restoration and finally monitoring the result. The patient will present with a healing abutment attached to the implant which can be removed and the position of the implant, its angulation and depth in the soft tissues can be assessed. It is normally possible for the abutment to be unscrewed without requiring a local anaesthetic.

### **Abutment choice**

If the implant position is satisfactory and a clear choice of manufactured abutment has been made then the abutment can be ordered and attached to the implant. Manufacturers will have a protocol for securing the abutment and tightening the abutment screw which must be followed. This may include taking a radiograph to confirm full seating of the abutment before tightening the screw.

Making the wrong choice of abutment is a costly mistake and if a clear decision cannot be made in the mouth it is better to take an impression of the implant itself and make the choice out of the mouth following a diagnostic set-up (Figure 12.12). A ready-made impression coping is attached to the implant and a master model produced using a replica of the implant. As the implant will be significantly subgingival, the use of a solid plaster model will not allow access to the deep margins. A removable silicone replica of the gingiva is therefore incorporated into the model to allow access to the top of the implant and also to allow the restoration to be made with an emergence that can shape the soft tissue for a more natural appearance.

To ensure that the correct abutment is chosen to make the desired restoration a putty labial mask taken from the ideal diagnostic wax-up can be placed on the master model. If a laboratory-made abutment is to be used this needs to be designed to leave adequate space for the restoration with optimal retention and margins placed 1 mm subgingivally on the labial aspect so that no metal shows.



**Figure 12.12**

*a* A silicone putty matrix has been made from a diagnostic wax-up and is placed onto the master model of the implant positions. With a guide pin screwed into one of the implant replicas the correct abutment can be chosen.



*b* An abutment selection kit with replicas of the various abutment sizes and angulations.

## Impressions

Implant impressions are more straightforward than for conventional crowns and bridges but the same principles are followed. A special tray is often required but a stock tray will be adequate, if it is a good fit for simple cases. Impression copings are attached to the implant or abutment and are normally held in place with an extended pin. The tray is modified to allow the pin to extend through an opening. A conventional impression material (normally a polyether or silicone) is syringed around the coping and the tray is filled and seated so that the pin is visible through the tray (Figure 12.4e). Once set the pin

can be unscrewed and the impression removed along with the coping. The pin is used to secure the replica to the coping before the model is cast (Figure 12.4f).

Alternative techniques are available, particularly where access may be difficult to use a screwdriver to undo the pin with an impression in the patient's mouth. Impression copings can be attached to the implant or abutment and these are designed to remain in the mouth following removal of the impression. The coping can then be removed and re-seated into the impression.

The healing abutment is replaced on the implant while the restoration is made and the patient can wear their temporary restoration.

## Placing the restoration

If the abutment was left in the mouth, the temporary cover is removed and the restoration is tried in. Alternatively, a laboratory-made abutment is attached to the implant in exactly the same position as it was on the model. This may require a location jig to verify its position (Figure 12.6f). It is normal for the soft tissues to be placed under slight pressure as the restoration emerges through the gingival margin. The restoration is assessed for appearance, contour, contact points and occlusion as for any conventional restoration. The fit of the restoration should be ensured if ready-made components have been used.

Screw-retained restorations can be tightened and temporary covers placed over the screws to allow patients to live with the restoration before it is completed. Cemented restorations can be temporarily cemented to also allow for retrieval and alteration before being definitively cemented. It is frequently important to allow for this trial period while the patient adjusts to the new restoration and the soft tissue adapts to the new contour (Figure 12.4l). This trial period allows the restoration to be altered before finally screwing or cementing into place.

Implant restorations, other than full arch reconstructions, have the occlusal contacts adjusted so that on light contact the implant restoration is only just in contact and is not able to hold occlusal contact foils such as shim stock. On applying pressure the implant restoration will come into full contact and hold shim stock and this allows the implant to be protected from overloading, as it is not in a periodontal ligament and cannot protect itself from occlusal overload as teeth can. Extensive restorations cannot be protected from occlusal contacts and care is taken to ensure that the occlusal loads are in the long axis and centred over the implants where possible.

Following approval by the patient and verification by the dentist that the restoration is satisfactory it can be completed. Cemented restorations can be placed using conventional crown and bridge cements, although often temporary cements are adequate due to the tightness of fit of components. Care must be taken to ensure removal of all excess cement. Screwed restoration must have the screws re-tightened

and the access holes restored with composite. The patient should be given specific oral hygiene instruction.

Long cone radiographs should be taken of the completed implant restoration and monitored for the first few years with annual radiographs to check the maintenance of the bone support for the implant. The patient's oral hygiene also needs to be maintained.

## Maintenance

The continued success of an implant should be monitored by clinical and radiographic examination every year for at least 2–3 years and thereafter at longer time periods. Periodontal probing of the soft tissues is not very useful other than demonstrating poor plaque removal if the gingiva are bleeding on probing. Metal scalers should not be used around implants as they may damage comparatively 'soft' titanium surfaces. Plastic scalers are available.

## Complications

The signs of implant failure are:

- Implant mobility
- Pain or discomfort
- Bone loss more than 1 mm in the first year or more than 0.2 mm per year thereafter.

If bone loss around the top of the implant is observed, this may not in itself lead to complete failure of the implant but may indicate occlusal overloading of the implant or poor oral hygiene, both of which should be addressed.

Complications can commonly arise with implant restorations and there is evidence that this may be more common than with tooth-supported restorations. Fractures of porcelain or acrylic portions of a restoration can be repaired, particularly if screw-retained restorations have been provided. Abutment and bridge screws can sometimes fracture but fracture of the implants is rare.



[WWW.HIGHDENT.IR](http://WWW.HIGHDENT.IR)

همیار دندانسازان و دندانپزشکان

## 13

## Fixed splints

Many of the techniques used in constructing fixed splints are similar to those used to make crowns and bridges. Large splints often contain one or more pontics, and are therefore combination bridge/splints. There is no attempt here to describe removable splints in detail, since the techniques for constructing them are more akin to partial denture construction. There is, however, a section of this chapter comparing fixed and removable splints.

Different types of splint are used depending on the length of time for which they will be needed. Short-term splints are made as an emergency measure, intermediate splints are made to last for a few months, usually while other forms of treatment are being carried out, and permanent splints are intended to last for the lifetime of the dentition or the patient.

### Indications for fixed splints

#### *Trauma*

A blow may result in an incisor tooth being partially or completely subluxated. If the tooth is repositioned correctly in its socket very shortly after the accident, particularly with young patients, it has a good chance of surviving for a useful period, provided that it is kept clean and other conditions are favourable. It will normally need to be stabilized by being attached to adjacent teeth while the periodontal ligament heals and the alveolar bone remodels. It is not usually necessary to provide intermediate or permanent splinting for traumatized teeth.

#### *Periodontal disease*

At one time splints were prescribed as a way of treating periodontal disease and preventing the loss of teeth through progressive loosening. This is no longer accepted as a reasonable form of

treatment; and the proper treatment of periodontal disease itself is beyond the scope of this book. However, once the disease has been successfully treated, there may be two conditions when a fixed splint is indicated:

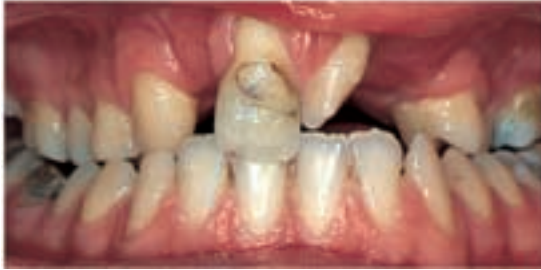- When the residual mobility of the teeth is such that the patient finds them uncomfortable and normal masticatory function is impractical.
- When teeth are missing and must be replaced for one of the reasons listed in Chapter 7. In many cases the remaining teeth are not satisfactory as denture abutments in view of their mobility or because it is considered that a partial denture will make oral hygiene procedures more difficult and will be likely to shorten the life expectancy of the remaining teeth. Individual teeth may also be unsuitable as bridge abutments, but a number of teeth splinted together may form a satisfactory abutment for a bridge or perhaps a precision-attachment retained partial denture.

#### *Orthodontic retention*

In the great majority of courses of orthodontic treatment the teeth are moved into new positions where, following a period of settling in, they are stable. There is sometimes a persistent tendency to relapse, and for fuller explanations for this the reader is referred to textbooks of orthodontics. Orthodontic relapse is more likely, and may indeed be anticipated, if the tooth movement is to realign teeth that have drifted following periodontal disease. Figure 4.5c and d illustrates a case where, if orthodontic treatment is to be provided, fixed splint retention is very likely to be necessary.

#### *Cleft palate*

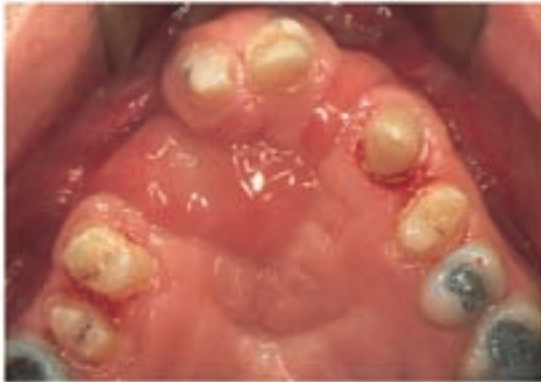One method of treating cleft palate cases is to expand the palate rapidly by orthodontic means



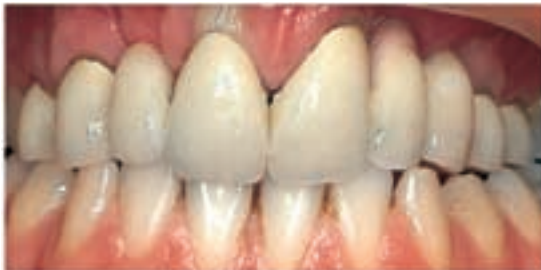**Figure 13.1**

A bridge to stabilize a mobile premaxilla resulting from a bilateral cleft palate.

*a* The preoperative condition following surgical treatment.



*b* The prepared teeth. Two abutments in each buccal segment are used together with the two teeth in the premaxilla.



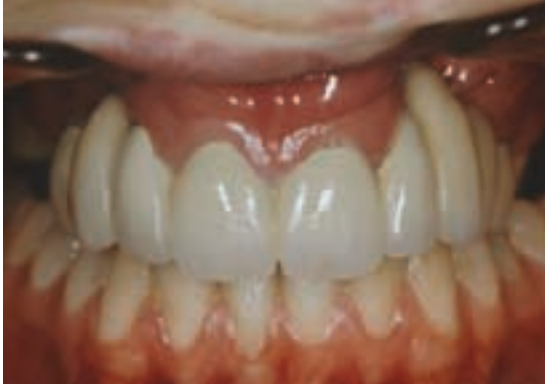*c* The completed bridge stabilizing the premaxilla.

and to insert a bone graft. In some cases the result is not completely stable, and if there are missing anterior teeth (which is common), a bridge replacement may be made and a number of teeth on each side of the cleft splinted to form the abutments. These splinted abutments will also stabilize the two halves of the upper arch.

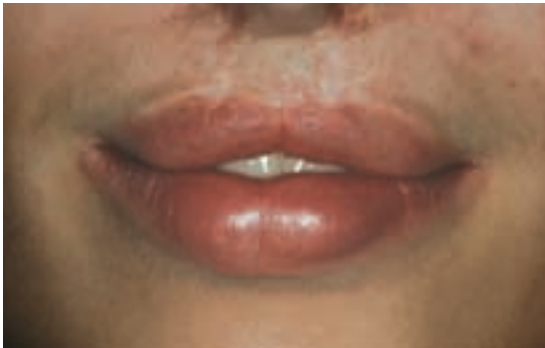Occasionally the premaxilla is separated from the remainder of the upper arch and, together with any teeth carried in it, it will be mobile. This

can be splinted by means of a fixed splint/bridge (Figure 13.1).

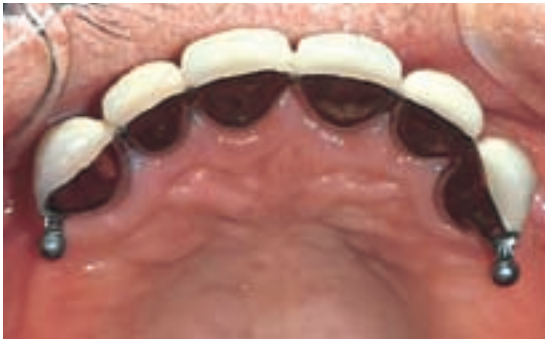The surgical and orthodontic management of cleft lip and palate has improved in recent years and the need for stabilization by means of bridges has reduced. However, the surgical and orthodontic treatment is not always successful and so the need for a restorative option still remains. Also a large number of cleft lip and palate patients were treated in the past by fixed



d Another similar case with considerable bone loss and insufficient blood supply for further bone grafts or implants. Hence the very long pontics.



e However, the tight lip hides the pontics.



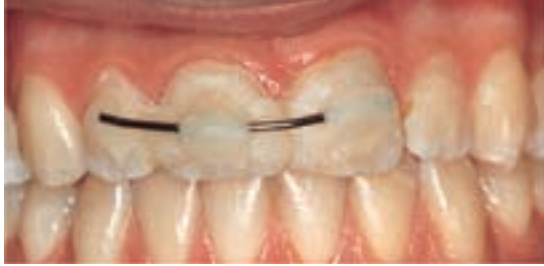**Figure 13.2**

Splinted abutment teeth for a precision-attachment retained free end saddle denture. The six anterior teeth have reduced alveolar support and have been successfully treated periodontally. They were also heavily restored. Splinted crowns provide support for extracoronal precision attachments that retain and stabilize a denture and avoid visible clasps.

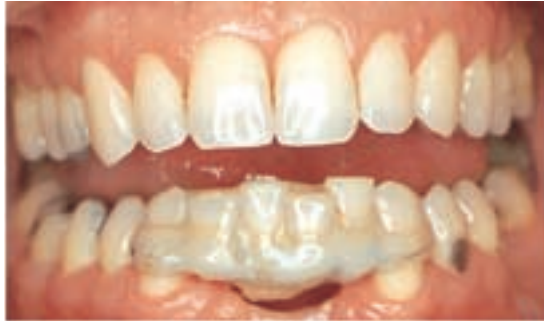splint/bridges and these need to be maintained. There have been unfortunate incidents when enthusiastic dentists faced with a failing bridge of this type think it would be better to make individual crowns and place implants to replace the missing teeth. In some of these cases the arch has collapsed without the stabilization of the bridge, causing great difficulty.

### **Additional retention**

With precision-attachment retained partial dentures, the abutment teeth carrying the attachment may need to be splinted together. This provides extra retention to resist the additional force during removal of the appliance (Figures 7.3a and 13.2).

**Figure 13.3**

The right central incisor was partly displaced by a blow. It was mobile and uncomfortable. This wire-and-composite splint is rigid, allows the tooth to be positioned correctly in the occlusion while the splint is being attached, allows the tooth to be tested for vitality, does not interfere with the occlusion, and is accessible for cleaning. It was removed after 3 weeks, by which time the injured tooth was firm.

**Figure 13.4**

A wire-and-acrylic splint. This splint served a useful purpose during initial periodontal therapy, after which the roots of the four incisors were resected. The splint has remained effective until complete alveolar healing has occurred, and now the patient is ready to have a bridge – a temporary partial denture having been avoided.

## Short-term, intermediate and permanent splints

### Short-term splints

When a tooth is loosened by a blow or is completely lost and replanted, an immediate temporary splint is necessary. The usual method of splinting is to attach the tooth involved to adjacent teeth with wire attached with composite (Figures 13.3, 13.4 and 8.9). Various other techniques were previously used for temporary splints, such as wiring the teeth together or cementing a cap splint made of acrylic, some other vacuum-formed material or cast metal. However, if sufficient enamel is present for acid etching, these other techniques are less satisfactory than wire/composite splints because they are less hygienic and interfere with the occlusion.

### Intermediate-term splints

These are used when teeth need to be immobilized for periods of between a few weeks and a few

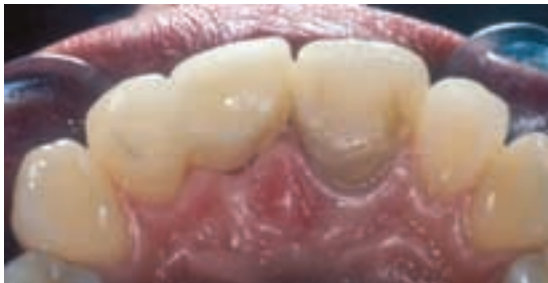months, for example while periodontal treatment is carried out, before permanent restorations are made. They are usually one of the less permanent minimum-preparation types, such as a Rochette splint (Figure 13.5c), but may be intracoronal.

### Permanent splints

Conventional permanent splints for restored teeth are usually complete crowns connected (Figure 13.2). With unrestored teeth a minimum-preparation splint is the treatment of choice (Figure 13.5d).

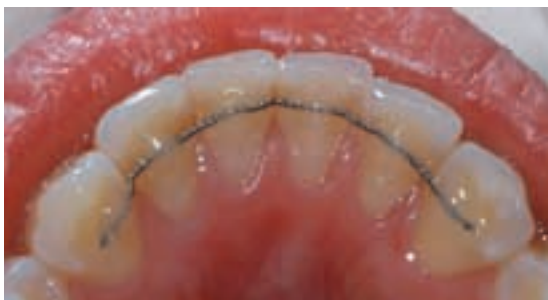## Fixed splints compared with removable splints

A variety of removable splints were used in the past but only two are still common: long-term orthodontic retainers and short-term vacuum-formed soft splints for traumatized teeth. Apart

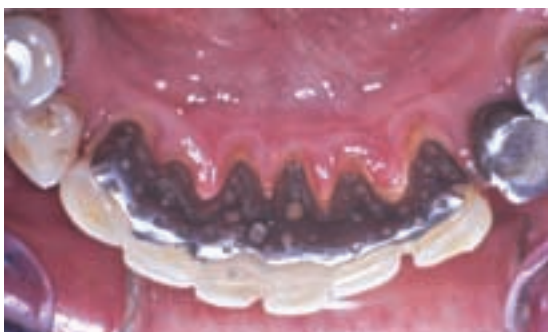

**Figure 13.5**

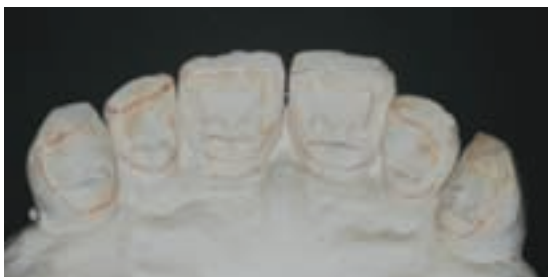*a* Quartz-fibre-reinforced composite splint.



*b* A flexi-wire orthodontic retainer retained by composite.



*c* A Rochette minimum-preparation splint made for a patient who found the mobility of their teeth to be uncomfortable following successful periodontal stabilization.



*d* Preparations for a six-unit minimum-preparation splint. The notches are a little deeper than usual because of the difficulty of seating a multi-unit splint on mobile teeth.

from these fixed splints should be used rather than removable. The advantages of fixed splints are:

- They are the most reliable splints for mobile teeth or those with a tendency to drift
- Can be kept entirely clear of the gingival tissues
- Occupy minimum or no additional space
- Cannot be left out by the patient.

### Types of short-term, intermediate and permanent fixed splint

Although short-term splints are different from the others, there is less distinction between intermediate- and long-term splints.

#### Examples of short-term splints

##### Acid-etch retained composite splints (Figure 13.3)

A simple short-term splinting technique is to acid-etch the approximal surfaces of adjacent teeth and connect them with composite. The technique is not sufficiently rigid to function as a permanent splint. To strengthen the splint, it is usually necessary to add stainless-steel wire or ribbon fibres.

##### Wire and composite splint (Figure 13.4)

A satisfactory form of intermediate splint, particularly for mobile lower incisors, is the wire-and-acrylic splint. The technique can be used when some of the teeth are crowned and so cannot be etched for the retention of composite.

#### Examples of intermediate- and long-term splints

##### Fibre-reinforced splint (Figure 13.5a)

These have only been available for a fairly short time and so it is sensibly cautious to regard them as intermediate for the time being.

##### Flexi-wire splints (Figure 13.5b)

These are commonly used by orthodontists following a course of orthodontic treatment producing an unstable result. Orthodontists can predict that medium- or long-term splinting will be necessary before the orthodontic treatment starts. The patient and parents can therefore give informed consent.

The 'flexi-wire' is attached to the lingual or palatal surfaces of teeth with composite. The flexibility of the wire allows some movement of the teeth to which it is attached but the wire is relatively weak and breakages are common.

##### Cast metal intermediate and permanent minimum-preparation splints

These are the most common types of intermediate and permanent splints. They have the advantage that they do not require much or any preparation of the tooth and yet are thin and unobtrusive and do not significantly affect the patient's appearance. However, because they are applied to the surface of the teeth, they inevitably add to their bulk and make oral hygiene more difficult. There is also the problem of them interfering with the occlusion; and in some cases the ideal design for retention and splinting cannot be used because of the occlusion.

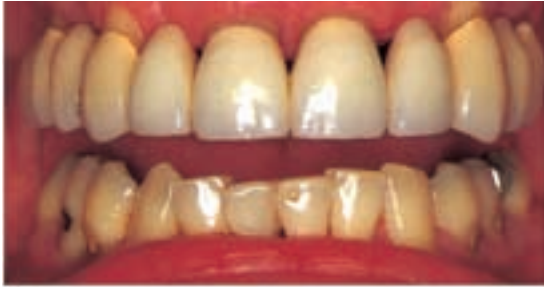Figure 13.5c shows a Rochette splint. These splints have the advantage that it is possible to remove them fairly atraumatically by cutting the composite out of the retentive holes.

Figure 13.5d shows the preparations for a six-unit minimum-preparation splint. The only preparation has been the palatal notches to locate the splint firmly to the teeth, without slipping, while the cement sets.

For permanent retention of orthodontically treated teeth with sound periodontal health, a minimum-preparation splint is preferred since it is more retentive and smoother lingually. These splints are made and cemented in the same way as the minimum-preparation bridges described in Chapter 11.

##### Complete-crown splints

Despite the advantage of minimum-preparation splints, complete-crown splints are still common.

**Figure 13.6**

A 12-unit fixed splint/bridge. There are six abutment teeth and six pontics. Note the supragingival margins which have helped to maintain a good level of gingival health. Note also the opaque appearance of the retainer margins. This is because in order to make the six preparations parallel to each other it was not possible to prepare sufficiently wide shoulders without over-preparing the whole tooth and risking exposure. This was anticipated from the trial preparations and the patient was fully informed about this before the preparations were undertaken so that her consent to the procedure included understanding that the appearance would be compromised in this way.

This is because the natural crowns of the teeth being splinted often already have large restorations or crowns, and some teeth may have been extracted, so that the appliance becomes a splint/bridge. Figure 13.6 shows a typical 12-unit splint/bridge where six teeth are missing and where the remaining teeth were uncomfortably mobile. A partial denture to replace the missing teeth would probably have increased the mobility of the remaining teeth; and the patient was most unhappy about wearing a removable appliance. The radiographs of this patient are shown in Figure 7.5.

The disadvantages of this technique are that it is very time-consuming, both at the chair side and in the laboratory, and therefore very expensive. If failure occurs, it may be necessary to remove the entire splint and maybe extract several other teeth. This type of appliance should therefore only be provided for very highly motivated patients with extremely good oral hygiene.

### Intracoronal splints

A variety of techniques have been suggested for splinting adjacent teeth with intracoronal restorations using either amalgam or composite, with the teeth linked by wire or a proprietary device.

The major problems with this type of splint are first that forces applied to the unprotected part of the tooth surface tend to break down the seal

between the restoration and tooth, with marginal leakage occurring followed by secondary caries. Second, mechanical failure at the connectors is fairly common. Third, because they are difficult to finish and polish, it is often harder to clean around this type of splint than around partial or complete crown splints with polished connectors.

For these reasons and because there are now better alternatives intracoronal splints are no longer used, although some lucky patients who have avoided these problems still have them.

### The appearance of anterior splints

A patient who has had extensive periodontal disease and treatment (particularly surgical treatment) often has upper anterior teeth that appear very long. When the lipline is high this is an aesthetic problem (Figure 7.8a). If the incisor teeth are extracted and a partial denture is made, artificial teeth, fitted to the ridge, will also appear to be too long; otherwise a flange may be used, and the edges will have an extremely artificial appearance. In any case, if the patient has been cooperative during periodontal treatment and this has been successful, he or she will obviously not want the teeth extracted.

If a complete-crown splint is made, it will be necessary to prepare crown margins at the



cement–enamel junction (CEJ) and try to disguise the crown margin as the CEJ, or at the gingival margin, producing very long thin preparations that endanger the pulp. The first alternative is often unsatisfactory, since the opacity of the metal–ceramic retainer is greater than that of the root surface. Neither makes any improvement in the appearance of the length of the teeth (Figure 13.6).

With all these aesthetic problems, some patients and dentists would elect to extract the upper incisor teeth, re-contour the ridge by bone augmentation and replace the teeth with implants. However, this would be even more expensive than the splint/bridge and so many patients have to accept the cheaper option of dentures.

### Selecting an anterior splint

It is important to make sure that the patient understands how the splint will look, and what compromises are necessary. In a typical case the patient has:

- Mobile, uncomfortable upper anterior teeth that have been successfully treated periodontally or have been retracted orthodontically
- A high lipline with unattractive appearance of the upper incisor teeth
- An extreme reluctance to wear a removable appliance.

There is no ideal solution to these problems; the options are as follows, in increasing order of cost:

- Offer no treatment; the result will be a patient who continues to complain about mobility, the lack of comfort, the appearance and possible further drifting of the upper incisors.
- Provide a minimum-preparation splint with or without a removable gingival prosthesis; the compromise here is the 'metal shine-through', but on the plus side are the conservative nature of the preparations and the relatively low cost compared with the alternatives. Sometimes this option is not possible because some of the teeth are heavily restored or crowned or the occlusion is unfavourable.
- Extract the upper incisor teeth and provide a partial denture; some patients will refuse, and

in any case it will provide only limited improvement in appearance.

- Extract the upper incisors and provide a bridge. There is still the problem of the length of the pontics, but this may be the preferred treatment in some cases – there is little point in keeping teeth with a very poor prognosis if the same number of additional abutment teeth would be necessary to support them as would be prepared for a bridge; a removable gingival prosthesis may also be provided.
- Provide a complete-crown splint with or without a removable gingival prosthesis; this has the disadvantages of time, cost and appearance described above, but may still be the preferred treatment in some cases.
- Extract the teeth and provide ridge augmentation and implants.

### Clinical techniques for permanent splints

The reader is referred to the literature on the treatment of traumatized teeth and the periodontal literature for fuller descriptions of temporary and intermediate splinting techniques. The clinical techniques for minimum-preparation splints are the same as for bridges (see Chapter 11), therefore clinical techniques will be described only for complete-crown splints.

### Tooth preparation for complete-crown splints

One of the techniques described in Chapter 11 should be used to ensure that the preparations are parallel. In the case of multiple-unit complete-crown splints, it may be necessary to take several intermediate impressions to check the parallelism of the preparations with a surveyor before the final impression is taken. Figure 13.6 shows a 12-unit splint/bridge with six abutment teeth. Six intermediate impressions were taken. This sounds very time-consuming, but with fast-setting plaster and a surveyor at the chair side, only two appointments were needed.

It is highly advisable to carry out trial preparations on a study cast to ensure that the ideal path

of insertion is selected. This may not be in the long axis of all the teeth.

### **Temporary splints**

With complete-crown splints it is possible to make a temporary splint at the chair side or in the laboratory using one of the techniques described in Chapter 11.

### **Impressions**

When teeth are mobile, they should be splinted so as to be in an unstrained position within their remaining periodontal support, and preserving optimum occlusal relationships. There is a danger of them being moved away from this position by the force of the impression being inserted, so that the finished splint, although it may fit, will distort the alignment of the teeth. This risk is greater if a viscous material is used, particularly in a close-fitting special tray. This means that the putty-wash technique is not ideal for these impressions.

There are two ways around this problem. One is to use an impression technique in which the teeth can 'float' into their natural positions before the material sets, the ideal material being reversible hydrocolloid. The second way is to take an impression in any material and have

separate transfer copings made for each tooth. These are located in the mouth using a gentle technique that does not disturb the alignment of the teeth, for example painting on a self-curing acrylic material (see Chapter 11).

### **Cementation**

Some teeth being splinted are likely to be more mobile than others, and this produces a cementation problem. Although the splint may fit well at the margins when it is tried in, if some teeth can be moved apically in their sockets and others cannot, when the splint is being cemented the mobile teeth may be depressed by the hydrostatic pressure in the unset cement. The marginal fit of the retainers of these teeth will therefore be unsatisfactory. Precautions should be taken to avoid this happening. The splint should be pressed firmly home onto the stable abutments and then an instrument such as a Mitchell's trimmer hooked onto the mobile abutment teeth, preferably at the cement–enamel junction, and the teeth drawn down into its retainer. Because this takes time, zinc phosphate cement, mixed to produce an extended working time, is preferred.

Alternatively, floss is tied round each of the mobile teeth between the preparation margin and the gingival margins. After fully seating on the stable abutments, the mobile teeth can be pulled down into their retainers with the floss.

**WWW.HIGHDENT.IR**

همیار دندانسازان و دندانپزشکان

## 14

# Crown and bridge failures and repairs

## General considerations of success and failure and the value of survey data

### *How long will it last?*

This is a question which many patients ask when a crown, bridge or implant is being discussed and a decision is being made between them or leaving the tooth without a crown or the space unrestored.

The honest answer is 'I do not know' but that is not going to satisfy the patient.

There have been many surveys of crown, bridge and implant success and failure; however, there are a number of major problems with these surveys.

Prospective surveys, following up restorations from when they are placed, are usually of selected and therefore biased samples – restorations made in dental schools, or specific practices. Also, if it is known that the treatment is part of a survey, extra care may be taken in the treatment, thus producing further bias.

Retrospective surveys, looking at a cross-section of restorations placed in different locations – general or specialist practice or dental hospitals – by a variety of dentists and by a variety of techniques involve so many variables that it is difficult to analyse the results realistically.

Retrospective surveys of failures are helpful when they look at the causes of failure and the time from the restoration being placed to its failure.

A reasonable way to record failures is as a percentage per year. For example, large surveys of bridges made in practice and elsewhere in different countries show that about 90% of bridges last at least 10 years.

## *There are difficulties in defining failure*

Looking at any crown, bridge or implant, it is always possible to find some minor fault with the fit or the appearance of some other aspect. In many cases it is a matter of degree. There is nothing seriously wrong with the restoration, only that one dentist, looking at another's work, would have applied his or her skills in different ways – would have introduced a little more incisal translucence or placed the margin a little more subgingivally or supragingivally, or finished it better. These variations in judgement are to be expected and need to be encouraged. If every crown or bridge were standardized, there would be no room for development and improvement.

At the other extreme there are undisputed failures, for example, the fractured ceramic crown or the loose bridge where extensive caries has developed. Between these extremes lies a large grey area of partial failures and partial successes. With these it is better to consider levels of acceptability to patient and dentist (which may be different) and to consider what needs to be done to improve matters.

Because the prognosis for a crown, bridge or implant cannot be guaranteed, potential failure should be regarded as a disadvantage and balanced against the advantages. It is not realistic to ignore the possibility of failure, and its financial implications for patient and dentist must be recognised.

For restorations which have only been available for a short time or where significant changes in design, materials or techniques have been made it is not possible to give a reliable prognosis, only a best guess.

Many patients die with their restorations intact and so these restorations, however long they have been in place, have served their purpose and are successful.

Later in this chapter the causes of failure and some solutions are described, together with some techniques for adjustment or repair.

### ***How long do crowns and conventional bridges last?***

Most crowns and bridges do not wear out, neither do the supporting teeth. Failure is the result of an isolated incident, a progressive disease process, or bad planning or execution in the first place. Isolated incidents such as a blow cannot be predicted and may occur on the day the restoration is fitted, in 40 years time or never.

The prevention of caries and periodontal disease is largely under the control of the patient, assisted and monitored by the dentist and hygienist. Some changes affecting caries and periodontal disease cannot be predicted. These include dietary changes, drugs producing a dry mouth, the onset of a general disease such as diabetes and geriatric changes that may make cleaning difficult.

A number of long-term surveys of success and failure have produced results varying from very low to high rates of failure. It is possible to calculate from the published figures an average life expectancy of a bridge but this is the wrong statistic to use, and it should not be quoted to patients. Some restorations are failures from the day they are inserted, for example because they do not fit properly, and some last for over 40 years with a range between. To quote an 'average' of 20 years is meaningless.

In the more recent surveys more sophisticated statistical methods have been used to describe survival rates of restorations. In addition, a number of factors affecting the survival rate have also been analysed, for example for bridges, the design, the number of teeth being replaced, the periodontal support for the abutment teeth and their vitality and factors to do with the patient such as age and gender. Some of the surveys show a survival rate that remains high for the first 10 years or so with more than 90% of the bridges still in place at that time. After this, the survival

rate declines, with 60–70% of bridges still in place at 15 years. There are not sufficient studies to establish the number of years at which the survival rate is 50%, in other words when there is an even chance that the bridge will still be in place. However, looking at the published survival curves and extrapolating them, the figure is likely to be between 30 and 40 years survival for small, well-made conventional bridges.

One of the difficulties in interpreting these surveys is the fact that many of the bridges were made a long time ago using techniques, materials and concepts that are now regarded as out of date.

There is therefore no reliable, consistent figure which can be given to a patient when they ask: 'How many years will the bridge last?'. It is often necessary to give the patient a fairly detailed explanation of why such a figure cannot be given or to say something more vague such as (depending on the patient's age, condition of the abutment teeth, etc.): 'A bridge made for you may have to be replaced with another bridge or an alternative prosthesis once (or twice) during a normal lifetime, at times that cannot be predicted'.

### ***How long do minimum-preparation bridges last?***

These were introduced long after conventional bridges and so there has been less time for long-term surveys. However, when they began to become popular two factors influenced the reviews of these bridges. First there was scepticism among many dentists about the likelihood of their success and this was reinforced by many early failures while they were being developed. This view still prevails among some traditionalists but has almost disappeared with more modern dentists who have been trained and have developed for themselves policies of minimum intervention, maximum conservation and considerable confidence in a range of bonding techniques and materials for many applications in dentistry.

The second factor is that the time that minimum-preparation bridges started to become popular and more reliable coincided with a fast growing emphasis on clinical audit and review, and they were therefore prime candidates for well-designed prospective surveys of success and failure.

Many good but relatively short-term surveys and audits have been carried out and the results are very encouraging. It is now reasonable to say that a minimum-preparation bridge should be the default option, rather than a conventional bridge, when the circumstances are appropriate.

### **How long do porcelain veneers and inlays last?**

Porcelain veneers rarely fail by becoming de-cemented unless this occurs soon after placement, indicating poor technique. More commonly porcelain fractures occur with or without loss of part of the veneer. These are normally vertical or oblique fractures extending down from the incisal tip. Fractures without loss can be monitored as they may not progress and the cement lute under the veneer, if intact, will protect the tooth from decay. Eventually the crack will stain and the veneer will usually need to be replaced. Small fractures to veneers can be repaired with composite.

Removing failed veneers is difficult and is best done with a diamond bur, regularly stopping to ensure that the enamel is not damaged. It is not always possible to replace a failed veneer with another veneer if there is insufficient enamel remaining.

Porcelain or composite inlays and onlays can fail by fracture, commonly across the narrowest part of the occlusal lock, in which case repair is not possible. Fracture may cause loss of part of the cuspal coverage. Repair with composite may be possible.

The reason for failure of porcelain inlays or veneers should always be investigated to ensure that a design problem is not repeated.

### **How long do implants last?**

The early Swedish studies of highly controlled groups of patients and treatment protocols produced impressive results but are unlikely to be reproduced in the less controlled environment of 'high street' general practice or specialist practice elsewhere in the world. Dento-legal experience shows that many failures do not get into survey data, which are distorted towards suggesting a higher than realistic success rate.

Dealing with failures of implant fixtures and/or the prosthetic elements is a specialist subject beyond the scope of this book. If a dentist finds evidence of failure in an implant, the patient should be referred unless the dentist has had specialist training. Preferably the referral should be back to the dentist who placed the implant.

### **How long have modern restorations been available?**

The following approximate figures relate to the time when the various restorations first made a major impact on dentistry in the UK. They have all been developed since then, producing continual improvement to a greater or lesser extent.

For example, conventional crowns and bridges have been made for over 100 years but have improved significantly with new techniques and materials in the last 30–40 years. However some, made with older materials and techniques, have lasted for more than 50 years.

These figures relate to the publication date of the fourth edition of this book: 2007.

- Metal–ceramic restorations      about 40 years
- Modern ceramic crowns      about 30 years
- Ceramic veneers      about 20 years
- Minimum-preparation bridges:
  - Fixed–fixed and cantilever (Rochette 1975)      about 25 years
  - Fixed–movable and hybrid      about 15 years
- Multiple implant retained restorations.
  - The Brannemark system was imported into the UK and USA in 1982 and it took about 5 years before a significant number of dentists were properly trained in its use. Therefore the substantial experience is      about 20 years
- Single tooth implants      about 15 years

### **A rough guide for advice to patients, to be modified by knowledge of the patient's specific circumstances**

This guide is based on survey data where this is reasonably robust, anecdotal evidence from

colleagues and the author's personal experience. It is therefore not scientific and should not be quoted in, for example, legal reports. Nevertheless, we feel it right to make an attempt, however flawed, to help dentists to answer the question 'How long will it last?'

Provided that the patient fully understands the likely effects of their own circumstances and that the following figures are very approximate with a wide range, it may be reasonable to give patients these figures. However, it is often better to estimate how many replacements will be necessary in the patient's anticipated lifespan if everything else remains stable. In other words add lots of caveats and estimate low rather than high. A patient whose restoration lasts a few years longer than you thought it would will be content but if it fails a few months beforehand they will be disgruntled.

	Years
• Ceramic veneers	8–10
• Individual anterior crowns	15–40
• Individual posterior crowns	20–50
• Small anterior conventional bridges	20–40
• Small posterior conventional bridges	20–50
• Large conventional bridges	10–30
• Minimum-preparation bridges	
– Cantilever	15–30
– Fixed–fixed	10–15
– Fixed–movable	10–20
– Hybrid	10–20
• Multiple implants	
– Connected to each other	25+
– Connected to natural teeth	20+
• Single tooth implants	20+

## Causes of failure and some solutions

### Loss of retention

With the exception of post crowns, where failure is usually due to inadequate post design or construction (Figure 14.1), loss of retention is not a common cause of failure of individual crowns. However, because of the leverage forces on fixed–fixed bridges, one of the more common ways in which they fail is by one of the retainers becoming loose but the other remaining attached to the abutment tooth.

### Conventional fixed–fixed bridges and splinted retainers

When only one retainer of a conventional bridge becomes loose, this can be disastrous. Without a cement seal, plaque forms in the space between the retainer and the abutment tooth and caries develops rapidly across the whole of the dentine surface of the preparation (Figure 14.2).

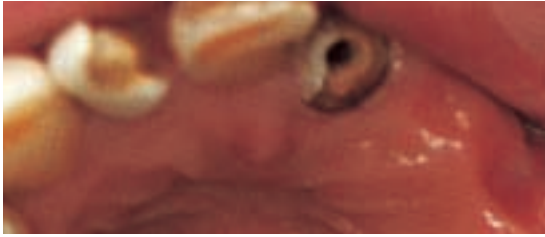Sometimes the patient is aware of movement developing in the bridge or experiences a bad taste from debris being pumped in and out of the space with intermittent pressure on the bridge. A good diagnostic test for a loose retainer is to examine the bridge carefully without drying the teeth, pressing the bridge up and down and looking for small bubbles in the saliva at the margins of the retainers.

### Minimum-preparation bridges

Loss of retention of one part of a fixed–fixed minimum-preparation bridge also occurs but, although caries does sometimes develop rapidly, because the surface of the tooth is enamel rather than dentine, the development of caries is usually slower than with a conventional bridge. If one retainer does become loose, it is a matter of urgency to remove at least that retainer, and usually the whole bridge. If a fixed–fixed minimum-preparation bridge becomes loose at one end but seems firmly attached at the other, one option is to cut off the loose retainer, leaving the bridge as a cantilever.

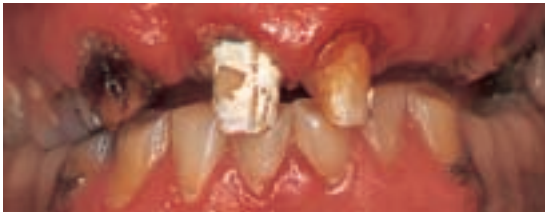Partial or complete loss of retention is the commonest cause of failure of these bridges. It is argued by some that if the bridge can be removed without distorting it, cleaned, re-grit-blasted and re-cemented without further treatment, it is not a true failure but only a partial failure. This is a reasonable point of view, and when minimum-preparation bridges are made, the patient should be warned that re-cementation may be necessary as part of normal maintenance and should not always be regarded as a disaster.

There is some evidence that minimum-preparation bridges are retained for longer periods when they have been re-cemented. It is difficult to imagine why this should be, other than perhaps the operator taking greater care the second time around. If a minimum-preparation bridge debonds soon after placement, this is often due to poor



**Figure 14.1**

The upper central incisor had a post-retained crown but no diaphragm covering the root face. The tooth has split longitudinally and the crown has fallen off. It must now be extracted.



**Figure 14.2**

Carious abutment teeth (the upper right canine and upper left first premolar) revealed by removing a bridge that was still firmly attached to the sound central incisors.

cementation technique and if re-cementation is done with more care, the bridge is likely to last for longer. Bridges that survive for many years and then debond may well not last for as long a second time.

There is now good evidence that fixed–fixed minimum-preparation bridges fail through loss of retention more readily than cantilever (with one abutment tooth) and fixed–movable designs. This is why these designs have been advocated earlier in this book. It is very unusual for a minor retainer for a fixed–movable minimum-preparation bridge to lose its retention because there are no significant forces to dislodge it.

### Other bridges

In the case of simple cantilever bridges with one abutment tooth, or the major retainer of a three-unit fixed–movable bridge, the loss of retention will result in the bridge falling out. The same is true if both ends of a fixed–fixed bridge become loose. There is usually less permanent damage in these cases, since plaque is not retained against

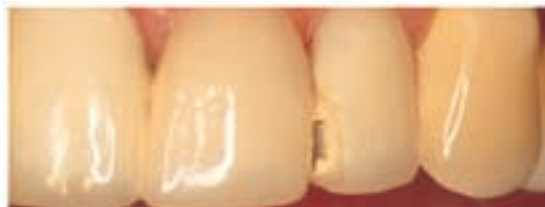the surface of the preparation, and the patient is obviously aware of the problem and seeks treatment quickly.

### Solutions for loss of retention

If there is no extensive damage to the preparation, it may be possible to re-cement the crown or bridge, provided that the cause can be identified and eliminated. It may be that a bridge was dislodged by a blow or that some problem during cementation was the cause. However, if the underlying reason is that the preparations are not adequately retentive, they can sometimes be made more retentive and the crown or bridge (or at least the unsatisfactory retainer) remade. A more adhesive cement could be tried such as a chemically active cement as used for minimum-preparation bridges. It is always wise to re-check the occlusion in case this contributed to the failure.

Alternatively it may be necessary to include additional abutment teeth in a bridge to increase the overall retention or to change the design in some other way.

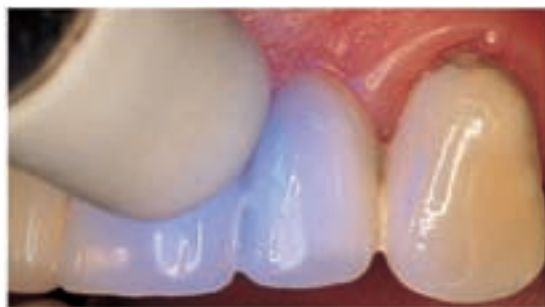



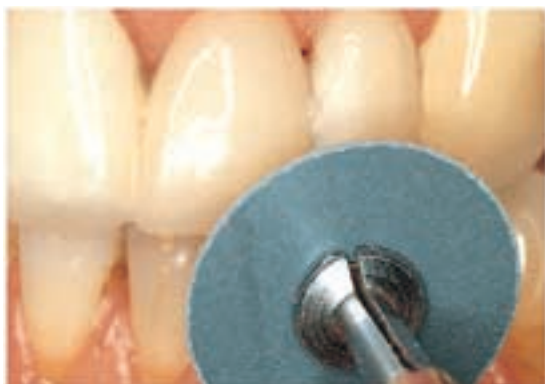**Figure 14.3**

Repairing porcelain facings.

*a* The porcelain of the lateral incisor facing has chipped. The bridge is more than 10 years old.



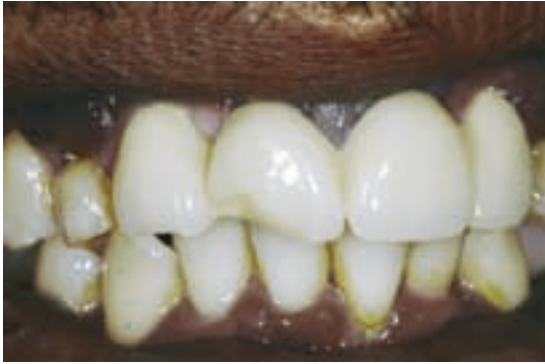*b* After polishing with pumice and water, a silane coupling agent is painted over the surface, followed by a resin bonding agent and light-cured composite.



*c* Polishing the composite.



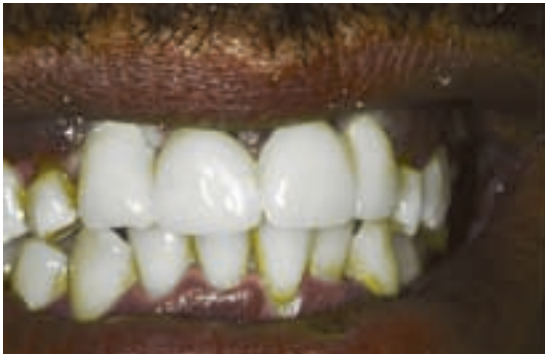*d* The finished result. This would have been better if an opaquer had been used over the metal to stop the 'shine through'.



e Fractured porcelain at the tip of a bridge retainer that was 5 years old and otherwise satisfactory.



f An intra-oral grit-blasting machine.



g The fracture repaired with composite following grit-blasting with alumina oxide particles and silane priming.

### **Mechanical failure of crowns or bridge components**

Typical mechanical failures are:

- Porcelain fracture
- Failure of connectors: solder and laser welded joints
- Distortion
- Occlusal wear and perforation
- Lost acrylic facings.

### **Porcelain fracture**

At one time pieces of porcelain fracturing off metal–ceramic restorations, or the loss of the entire facing due to failure of the metal–ceramic bond, were relatively common. With modern materials and techniques this is much less common; but when it does occur it is particularly frustrating since, even though the damage may be slight, and can often be repaired with composite, the repair is less satisfactory than the original porcelain (Figure 14.3). Even if the repair only



**Figure 14.4**

A laser welding machine.

lasts a few years before discolouring or wearing, it is a cost-effective way to extend the life of a restoration.

To prevent this type of damage to metal–ceramic bridges, the framework must be properly designed with an adequate thickness of metal to avoid distortion, particularly with long-span bridges. If there is any risk of the pontic area flexing, the porcelain should be carried on to the lingual side of pontics to stiffen them further.

A ceramic crown or bridge that is fractured must be replaced. Sometimes the cause is a blow, and then the choice of material can be regarded as fortunate: had a metal–ceramic material been used it is more likely that the root of the tooth would have fractured. If the fracture is due to trauma, and particularly if the crown or bridge had served successfully for some time, it should be replaced by means of another all-ceramic restoration. However, if the failure occurs during normal function, shortly after the crown or bridge is fitted, the implication is that the conditions are not suitable for a ceramic restoration, and the replacement should be metal–ceramic.

#### **Failure of connectors: soldered and laser welded**

**Solder joints.** Occasionally a solder joint that appears to be sound fails under occlusal loading. This may be due to:

- A flaw or inclusion in the solder itself
- Failure to bond to the surface of the metal
- The solder joint not being sufficiently large for the conditions in which it is placed.

A problem, particularly with metal–ceramic bridges, is that soldered connectors should be restricted from encroaching on the buccal side too much to avoid metal showing, restricted gingivally to provide access for cleaning, and restricted incisally to create the impression of separate teeth. Too much restriction can lead to an inadequate area of solder and to failure.

It is better whenever possible to join multiple-unit bridges by solder joints in the middle of pontics before the porcelain is added. This gives a much larger surface area for the solder joint, and it is also strengthened by the porcelain covering. Ideally one-piece castings are preferred and these are now more successful with modern investment materials and casting techniques.

A failed solder joint is a disaster in a large metal–ceramic bridge, and often means that the whole bridge has to be removed and remade. Figure 9.4e shows a failed solder joint which was too small. There are no satisfactory intra-oral repair methods, and it is not usually possible to remove the bridge to re-solder the joint without doing further damage.

**Laser welded joints** have been available for less time than soldered joints, but it is likely that they will be stronger. Figure 14.4 shows a laser welding machine.

#### **Avoiding soldered or welded joints in the first place**

The current, ideal laboratory technique is to produce both a working model with removable, trimmed dies to wax-up the separate components and a solid model to ensure that the components



**Figure 14.5**

*a* Sectioned and *b* unsectioned models of the same preparation need to be used to verify the contact points and confirm the fit of a crown.

are located together in an accurate relationship with good contact points (Figure 14.5).

### Distortion

Distortion of all-metal bridges may occur, for example, when wash-through pontics are made too thin or if a bridge is removed using too much force. When this happens the bridge has to be remade.

In metal–ceramic bridges distortion of the framework can occur during function or as a result of trauma. This is likely if the framework is too small in cross-section for the length of span and the material used. Distortion of a metal–ceramic framework invariably results in the loss of porcelain.

### Occlusal wear and perforation

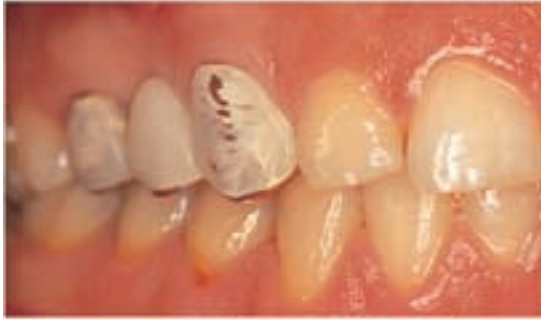Even with normal attrition, the occlusal surfaces of posterior teeth wear down substantially over a

lifetime. Gold crowns made with 0.5 mm or so of gold occlusally may wear through over a period of two or three decades. If perforation has been the result of normal wear and it is spotted before caries has developed, it may be repaired with an appropriate restoration. Occasionally, particularly if the perforation is over an amalgam core, it is satisfactory simply to leave the perforation untreated and check it periodically (see Figures 8.1b and 14.12d).

Occlusal perforations may also be made deliberately for endodontic treatment or vitality testing (see Figure 10.2c).

### Lost acrylic facings

Old laboratory-made or acrylic facings may be entirely lost, and wear and discoloration are also common (Figure 14.6). If the metal part of the restoration is satisfactory then removing all or part of the facing, grit-blasting the metal and repairing with composite is worth trying.



**Figure 14.6**

Badly worn acrylic facings.

The bridge has been present for many years and fits well. It is worth replacing all or part of the canine facing with composite.

## Changes in the abutment tooth

### Periodontal disease

Periodontal disease may be generalized, or in a poorly designed, made or maintained restoration its progress may be accelerated locally. If the loss of periodontal attachment is diagnosed early enough and the cause removed, no further treatment is usually necessary. However, if the disease has progressed to the point where the prognosis of the tooth is significantly reduced then the crown or bridge, or the tooth itself, may have to be removed.

With a bridge the original indication will still be present, and so something will have to be done to replace the missing teeth. It may be possible to make a larger bridge, or the abutment teeth may be reduced and used as abutments for an over-denture. Teeth that have lost so much support that they are not suitable as bridge abutments are also not suitable either as abutments for conventional partial dentures.

Figure 14.7 shows how successful periodontal treatment and adjustment of bridge margins can be achieved.

### Problems with the pulp

Unfortunately, despite taking the usual precautions during tooth preparation, abutment teeth may become non-vital after a crown or bridge has been cemented. It is usually reasonable to attempt endodontic treatment by making an

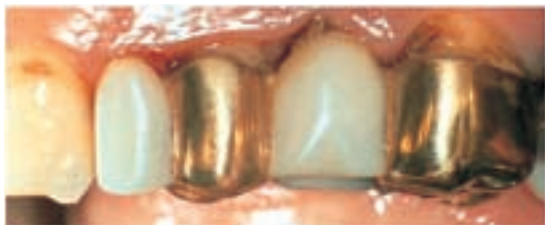access cavity through the crown. There are of course problems in the application of a rubber dam with bridges, although these can usually be overcome by punching a large hole and applying the rubber dam only to one tooth, stretching the rubber over the connectors.

It is difficult to gain access to the pulp chamber and remove the coronal pulp completely without enlarging the access cavity to a point where the remaining tooth preparation becomes too thin and weak to support the crown satisfactorily, or where the (pin) retention of a core is damaged. The crown may have been made with rather different anatomy from the natural crown of the tooth for aesthetic or occlusal reasons, so that the angulation of the root is not immediately apparent. Provided that these problems can be overcome and a satisfactory root filling placed, the prognosis of the crown or bridge is only marginally reduced.

Teeth that were already satisfactorily root-filled when the crown or bridge was made may later give trouble. It may be possible to re-root-fill the tooth through the crown, but apicectomy is an alternative solution. Care must be taken not to shorten the root of an abutment tooth more than is absolutely necessary so that the maximum support for the bridge can be maintained.

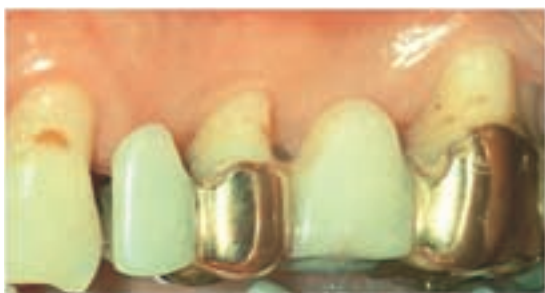### Caries

Secondary caries occurring at the margins of crowns or bridge retainers usually means that the patient has changed his or her diet, the standard



**Figure 14.7**

*a* An old bridge with defective margins and extensive gingival inflammation.



*b* The same bridge after a periodontal flap has been raised, the retainer margins adjusted by grinding and polishing, and the flap then apically repositioned. The gingival condition is now healthy.

of oral hygiene has lapsed or there is some inadequacy in the restoration that is encouraging the formation of plaque. The cause of the problem should be identified and dealt with before repair or replacement is started.

#### **Fracture of the prepared natural crown or root**

Fractures of the tooth occasionally occur as a result of trauma, and sometimes even during normal function, although the crown or bridge has been present for some time. With a bridge abutment it is usually necessary to remove the bridge, but occasionally the abutment tooth can be dispensed with and the root removed surgically, the tissue surface of the retainer being repaired and converted into a pontic.

#### **Movement of the tooth**

Occlusal trauma, periodontal disease or relapsing orthodontic treatment may result in the crowned tooth or bridge abutment becoming loose, drifting, or both. When the cause is periodontal

disease or relapsing orthodontic treatment, this must be remedied before the crown or bridge is remade.

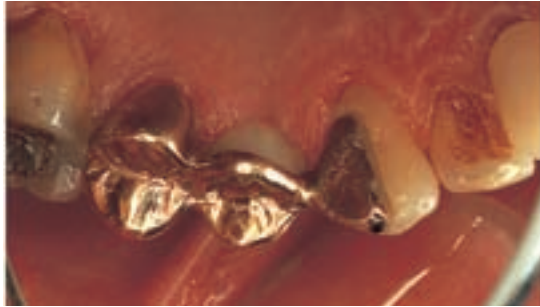
### **Design failures**

#### ***Abutment preparation design***

The pitfalls of inadequate crown preparation design were described in Chapter 3, and are the underlying cause of many of the problems listed so far in this chapter.

#### ***Inadequate bridge design***

Designing bridges is difficult. It is neither a precise science nor a creative art. It needs knowledge, experience and judgement, which take years to accumulate. So it is not surprising that some designs of bridge, even though well intentioned and conscientiously executed, fail. A simple classification of these failures is as 'under-prescribed' and 'over-prescribed' bridges.



**Figure 14.8**

A bad design.

The bridge is fixed–fixed and is firmly held by the premolar retainer. The inlay in the canine is, however, loose and caries has developed beneath it. Either the design should have been fixed–movable with a mesial movable connector or, if fixed–fixed, the retainer on the canine should have covered all occluding surfaces of the tooth and have been more retentive.

### Under-prescribed bridges

These include designs that are unstable or have too few abutment teeth – for example a cantilever bridge carrying pontics that cover too long a span or a fixed–movable bridge where again the span is too long, or where abutment teeth with too little support have been selected.

Another ‘under-design’ fault is to be too conservative in selecting retainers, for example intracoronal inlays for fixed–fixed bridges. With these design faults little can be done other than to remove the bridge and replace it with another design (Figure 14.8).

### Over-prescribed bridges

Cautious dentists will sometimes include more abutment teeth than are necessary, and fate usually dictates that it is the unnecessary retainer that fails. The first lower premolar might be included as well as the second premolar and second molar in a bridge to replace the lower first molar, no doubt so that there will be equal numbers of roots each end of the bridge so as to comply with the redundant ‘Ante’s Law’. This is not necessary.

Another example would be to use the upper canines and both first premolars on each side in replacing the four incisor teeth. As well as being destructive, this gives rise to unnecessary practical difficulties in making the bridge and cleaning it. This, in turn, reduces the chances of the bridge being successful.

When an unnecessarily large number of abutment teeth have been included in a bridge

and one of the retainers fails, it is sometimes possible to section the bridge in the mouth and remove the failed unit, leaving the remainder of the bridge to continue in function. The failed unit is remade as an individual restoration (Figure 14.9).

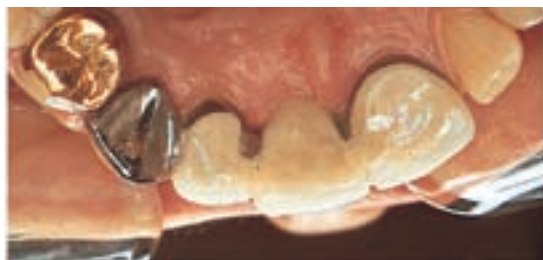The retainers themselves may be over-prescribed, with complete crowns being used where partial crowns or intracoronal retainers would have been quite adequate; or metal–ceramic crowns might be used where all-metal crowns would have been sufficient. When the pulp dies in such a case, it is interesting to speculate whether this might not have occurred with a less drastic reduction of the crown of the natural tooth.

### Inadequate clinical or laboratory technique

It is helpful to allocate problems in the construction of crowns and bridges to one of three groups:

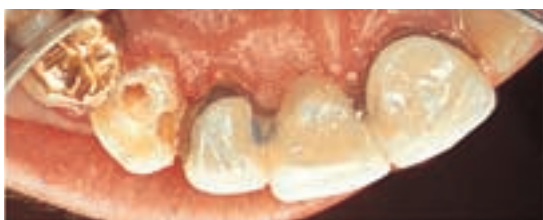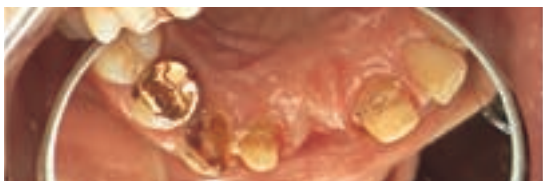- Minor problems to be noted and monitored but where no other action is needed
- The type of inadequacies that can be corrected *in situ*, and
- Those that cannot.

This is often a matter of degree, and many of the following faults can fall into any of these groups.

**Figure 14.9**

Overprescribed design.

*a* This four-unit bridge replaces only one central incisor. The partial-crown retainer on the canine has become loose. When the bridge was removed, the central and lateral incisors were found to be sound and adequate abutments, without the inclusion of the canine. Caries has spread across the canine, and the pulp has died.



*b* and *c* Fortunately it was possible to remove the bridge intact, and, after removing the canine retainer, the remaining three units could be re-cemented. A separate post crown was made for the canine tooth following endodontic treatment.

## Marginal deficiencies

### Positive ledge (overhang)

A positive ledge is an excess of crown material protruding beyond the margin of the preparation. Considering that this is a fairly easy fault to recognise and correct before the crown or bridge is fitted, it is surprising how frequently overhangs are encountered (see Figure 6.26a). However, it is often possible to correct them without otherwise disturbing the restoration.

### Negative ledge

This is a deficiency of crown material that leaves the margin of the preparation exposed but with no major gaps between the crown and the tooth. Again it is a fairly common fault, particularly with metal margins, but one that is difficult or impos-

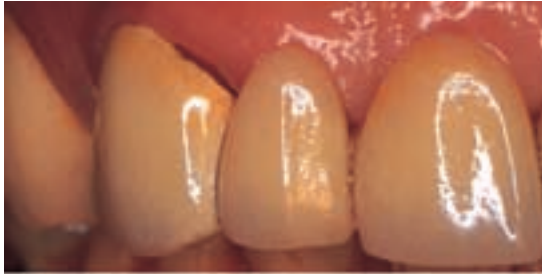ible to correct at the try-in stage (Figure 6.26b). It often arises because the impression did not give a clear enough indication of the margin of the preparation and the die was over-trimmed, resulting in under-extension of the retainer (Figure 6.27).

Provided that the crown margin is supragingival or just at the gingival margin, it is sometimes possible to adjust and polish the tooth surface. When the ledge is subgingival, and particularly when there is localized gingival inflammation associated with it, it may still be possible to adjust the ledge with a pointed stone or bur, although this will cause gingival damage. However, it is usually necessary to remove the crown or bridge.

### Defect

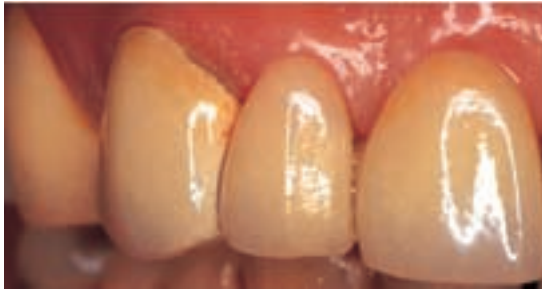A defect is a gap between the crown and preparation margins. There are four possible causes:



**Figure 14.10**

Repair for a retainer margin.

*a* A small gap at the mesial margin of the upper canine retainer on an otherwise very satisfactory bridge that has been in place for several years. The gap was not noticed at previous recall appointments, and although it may now have become apparent through gingival recession, it is more likely that the gap has been enlarged by over-vigorous use of dental floss. The patient demonstrated a faulty and damaging sawing action, with floss running into the gap.



*b* The defect repaired with glass ionomer cement. The patient has been shown gentler oral hygiene techniques.

- The crown or retainer did not fit and the gap was present at try-in
- The crown or retainer fitted at try-in, but at the time of cementation the hydrostatic pressure of the cement (particularly if the cement was beginning to set) produced incomplete seating
- With a mobile bridge or splint abutment, the cement depressed the mobile tooth in its socket more than the other abutment teeth, thus leaving the gap
- No gap was present at the time of cementation, but one developed following the loss of cement at the margin, and a crevice has been created by a combination of erosion/abrasion and possibly caries.

In any of these cases, the choice is to remove the bridge, restore the gap with a suitable restoration, or leave it alone and observe it periodically.

Purists may say that all defective retainers should be removed and replaced. But this is not always in the patient's best interest, and the skilful application of marginal repairs may extend the life of the restoration for many years (Figure 14.10).

### **Poor shape or colour**

More can be done to adjust the shape of a crown or bridge *in situ* than to modify its colour, although occasionally surface stain on porcelain can be removed and the porcelain polished. The shape of metal–ceramic crowns or bridges can be adjusted if they are too bulky (and this is usually the problem), provided that it is done slowly. At the first sign of the opaque layer of porcelain, the adjustment is stopped.

Successful modifications can often be made to open cramped embrasure spaces, reduce excessive cervical bulbosity, shorten retainers and pontics, and of course adjust the occluding surface. In all cases the adjusted surface, whether it is metal or porcelain, should be polished.

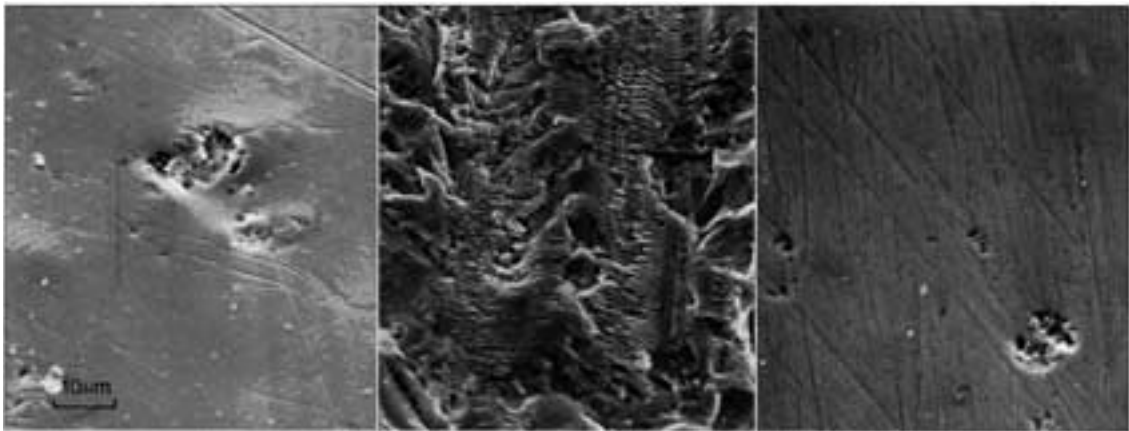
### **Occlusal problems**

As well as producing abutment tooth mobility, faults in the occlusion involve damage to the retainers and pontics by wear and fracture.

**Figure 14.11**

*a* A set of instruments for polishing porcelain. These are also available with contra-angle shanks for intra-oral use.

*b* Scanning electron micrographs, at the same magnification, of three areas of the same porcelain surface. *Left*: the glazed surface showing some undulation and occasional defects. *Centre*: the surface ground with a fine porcelain grindstone. *Right*: the same surface re-polished, after grinding, with the instruments shown in *a*. The surface is smooth, without undulations, but with some fine scratch marks and occasional residual defects.



The occlusion can change as a result of the extraction of other teeth, or their restoration, or through wear on the occlusal surface.

## Techniques for adjustments, adaptations and repairs to crowns and bridges

### Assessing the seriousness of the problem

In existing restorations there is not infrequently one or other of the faults listed above. A decision has to be made between:

- Leaving it alone, if it is not causing any serious harm

- Adjusting or repairing the fault
- Replacing the crown or bridge.

When action is necessary, it is clearly better to extend the life of an otherwise successful crown or bridge with the second option than replace restorations too frequently. If there is any doubt, or when adjustment or repair must be carried out, the restoration must be kept under frequent and careful review.

### Adjustments by grinding and polishing in situ

In some situations the margins of crowns with positive ledges can be satisfactorily adjusted. If the margin is porcelain, specially designed porcelain

finishing instruments should be used. Alternatively, a heatless stone or diamond point can be used, followed by polishing with successive grades of composite finishing burs and discs. These are capable of giving a very good finish to non-porous porcelain, which the patient can keep as clean as glazed porcelain (Figure 14.11). The contour of porcelain restorations can be modified *in situ* using the same instruments.

In the case of metal margins, a diamond stone followed by green stones, tungsten carbide stones or metal and linen strips may be used. Interdentally, a triangular-shaped diamond and an abrasive rubber instrument in a special reciprocating handpiece designed specifically for removing overhangs may be used. The margin should be polished with prophylactic paste and a brush or rubber cup, and interdentally with finishing strips.

## Repairs in situ

### Occlusal repairs

Occlusal defects in metal retainers can be repaired with amalgam, which usually gives quite a satisfactory result. In ceramic or metal–ceramic restorations composite can be used, but the repair may need to be redone periodically.

### Repairs at the margins

Although repairs are justified to extend the life of an established crown or bridge, they should never be used to adapt the margins of a poorly fitting bridge on insertion. Secondary caries that is identified at an early stage or early abrasion/erosion lesions at crown margins can be repaired using composite or glass ionomer cement. The cause should be investigated and preventive measures applied.

The cavity preparation at the margin must not be so deep that it endangers the strength of the preparation, although of course all caries must be removed. If there is poor access it may be better to remove part of the crown margin rather than an excessive amount of tooth tissue.

In some cases raising a full gingival flap may be justified. Retainer margins can be adjusted and restored under conditions of optimum access and

visibility, and any necessary periodontal work or endodontic surgery carried out at the same time (Figure 14.7).

### Repairs to porcelain

Materials are available to repair or modify the shape of ceramic restorations in the mouth. These are basically composites with a separate silane coupling agent to improve bonding. It is not an acid-etch bond like the bond to enamel and is not strong, so the use of the material is limited to sites not exposed to large occlusal forces (Figure 14.3).

An alternative and better solution is to use an intra-oral grit-blasting device if one is available. This will produce a retentive surface on porcelain to which bonding resin and composite can be applied. In many cases the repair is strong enough to be used on chipped or fractured incisal edges where there is sufficient porcelain to bond to (Figure 14.3e, f and g).

## Repairs by removing or replacing parts of a bridge

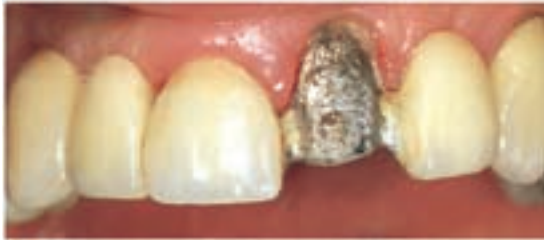### Replacing lost facings

It is sometimes possible to replace a failed facing on a bridge, usefully extending its life. But this is not worth attempting on individual crowns – it is better to replace the whole crown.

When the porcelain is lost from a metal–ceramic unit and a composite repair is not possible, there is often little choice but to remove the whole crown or bridge.

However, it is sometimes possible with retainers or pontics to remove all the porcelain and reprepare the metal part, producing enough clearance without damaging the strength of the metal. A new complete crown covering the skeleton of the old retainer or pontic can then be accommodated. These are sometimes made in heat-cured acrylic, laboratory light-cured composite or metal–ceramic material. They are known as ‘sleeve crowns’. A metal–ceramic sleeve crown is shown in Figure 14.12a, b and c.

Before the routine use of metal–ceramic materials, bridges were sometimes made with a

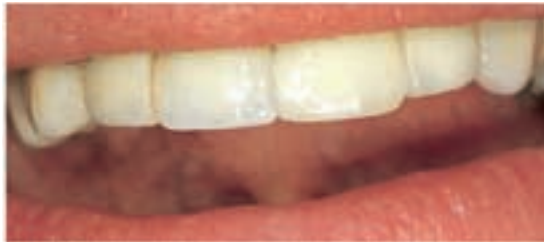**Figure 14.12**

Techniques for repairing bridges.

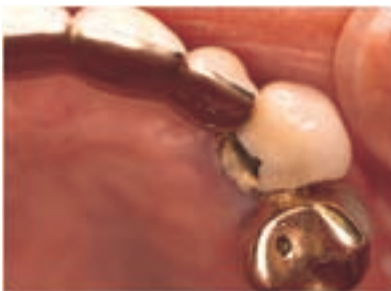*a* The porcelain on this bridge retainer has fractured. It has all been removed and the tooth prepared for a 'sleeve-crown'.



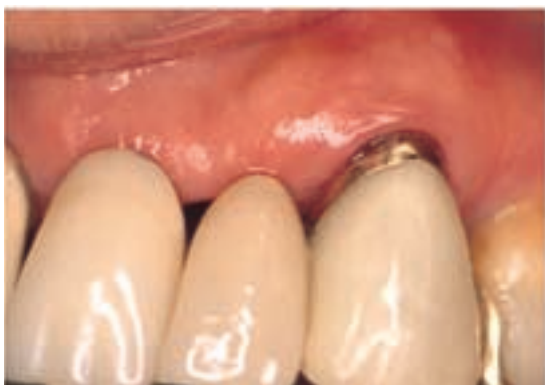*b* The sleeve-crown with a metal lingual surface replacing the original lingual porcelain. This could be bonded with the resin bonding material used with minimum-preparation bridges. The metal of the sleeve-crown should be grit-blasted in the laboratory immediately before bonding and the metal of the bridge could be blasted with an intra-oral grit-blaster if one is available. This would give a very retentive result.



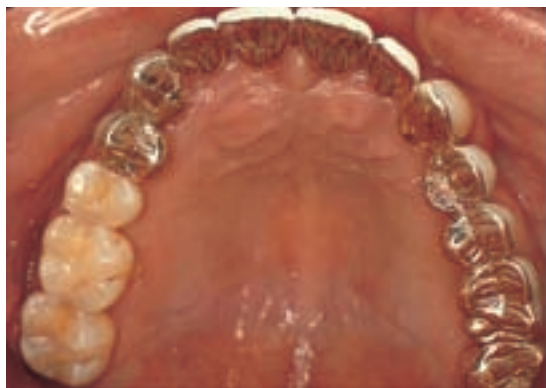*c* The sleeve-crown in place.



*d* A fractured traditional porcelain jacket crown, which has been made over a gold coping as the canine retainer for a bridge. Apart from this, and the hole worn in the occlusal surface of the premolar partial crown retainer, the bridge is still serving satisfactorily after more than 20 years.



*e* The replacement ceramic crown cemented. Pictures of the bridge illustrated in *d* and *e* were published in the first edition of this book in 1986. By the 3rd edition in 1996 the bridge with its replacement ceramic crown was still in place. The bridge eventually had to be removed for other reasons in 2002. It had been in place for 37 years – showing that repairs of this sort are well worthwhile.



**Figure 14.13**

Provision for the extension of a bridge (see text for details).

metal framework and separate ceramic crowns cemented to it. This design was known as 'unit-construction'. The individual ceramic crowns often broke, since they were considerably reduced approximately to accommodate the connector. However, a new ceramic or preferably a metal–ceramic crown can easily be made (Figure 14.12d and e).

### **Removing and/or replacing entire sections of a bridge**

Bridges are sometimes so designed that if a doubtful abutment tooth becomes unsavable, it can be removed with its associated section of the bridge, leaving the remainder undisturbed. This is one of the purposes of removable, telescopic crown-retained bridges and of dividing multiple-unit bridges into smaller sections. When part of a bridge is removed, the remainder can sometimes be modified, perhaps by cutting a slot for a movable joint and then replacing the lost section.

### **Removing abutment teeth**

Sometimes with large bridges, particularly those made as bridge/splints for patients with advanced bone loss and following periodontal treatment,

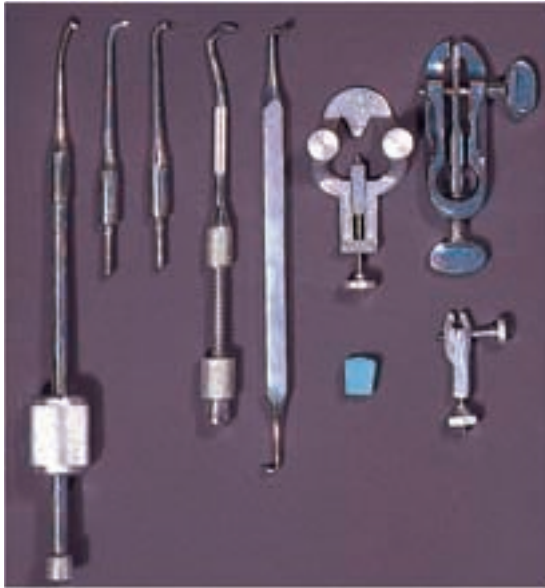such as that shown in Figure 13.6, it is possible to remove a failing abutment and fill the retainer with composite. The bridge shown in Figure 13.6 was made with six abutment teeth but over the years two abutment teeth developed untreatable periodontal disease and were extracted. Despite this the bridge survived for more than 20 years until the other abutment teeth deteriorated. The patient had learnt and practised meticulous oral hygiene methods.

### **Extending bridges**

Provision is sometimes made to extend a bridge if further teeth are lost. Figure 14.13 shows a large bridge with a slot in the distal surface of the premolar retainer on the left of the picture so that a further fixed–movable section can be added if the second premolar (which has a questionable periodontal prognosis) is lost. The slot is filled in the meantime by a small gold inlay.

### **Removing crowns and bridges**

In removing any crown or bridge, and in particular posts and cores, it is often helpful to break up the cement by vibrating the restoration with an ultrasonic scaler. This works best with zinc phosphate cement.

**Figure 14.14**

A selection of instruments for removing crowns, bridges and posts.

From the left:

- a slide hammer remover with two alternative screw-in tips: the tip is hooked into a crown margin or under a bridge connector, and the weight slid down the handle and tapped against the stop at the end;
- a spring-loaded slide hammer, also with replaceable tips;
- a special heavy-duty instrument that is hooked under crown margins and twisted to remove them;
- *below*: a turquoise-coloured adhesive polymer that is softened in hot water and bitten upon by the patient. The material is cooled with water and the patient is asked to jerk the jaw open;
- *above*: this instrument is clamped beneath the crown and the two screws (the heads visible here) are screwed down on to the occlusal surfaces of adjacent teeth, lifting the crown;
- two clamps that fit on to posts and cores, with a screw that presses on to the shoulder of a post-crown preparation and draws the post and core out of the tooth.

## Crowns

### Removing metal crowns

Complete and partial metal crowns can sometimes be removed intact by levering at the margins with a heavy-duty scaler such as a Mitchell's trimmer. Alternatively, a slide hammer type of crown- or bridge-remover may be used, or one of the other devices specially designed to remove crowns; Figure 14.14 shows a selection. If these techniques do not work, the crown will have to be cut off (see under 'Removing metal-ceramic crowns').

### Removing posts and cores

Unretentive posts can sometimes be removed by gripping the core in extraction forceps and giving it a series of sharp twists to fracture the brittle

cement, rather than tear the periodontal membrane and extract the tooth. This should not be attempted by the inexperienced!

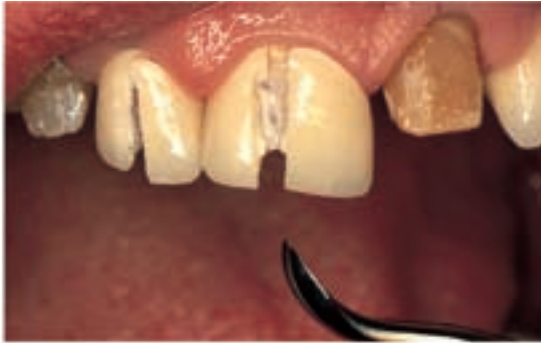There are several devices designed to remove posts and cores intact and to remove broken posts (Figure 14.14).

### Removing ceramic crowns

These cannot usually be removed intact, and should be cut off. A vertical groove is made with a diamond bur in the labial or buccal surface, just through to the cement, and then the crown is split with a suitable heavy-duty instrument (Figure 14.15).

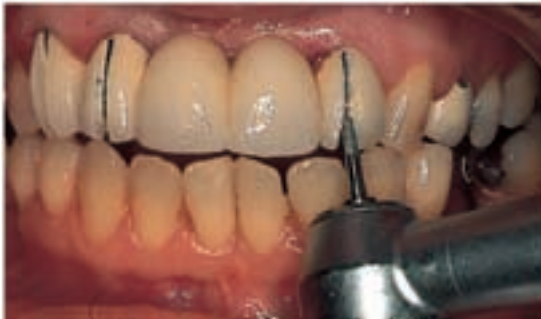### Removing metal-ceramic crowns

It is sometimes possible to remove metal-ceramic crowns intact by using one of the devices shown

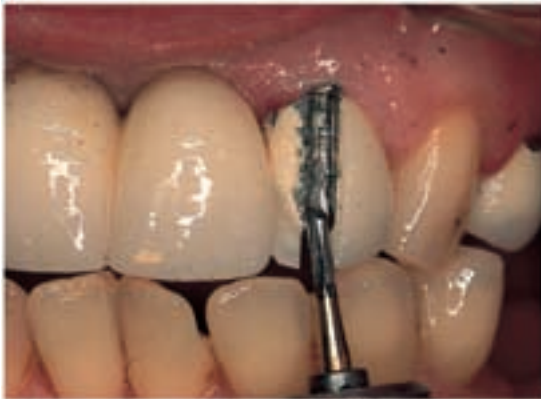**Figure 14.15**

Removing crowns and bridges.

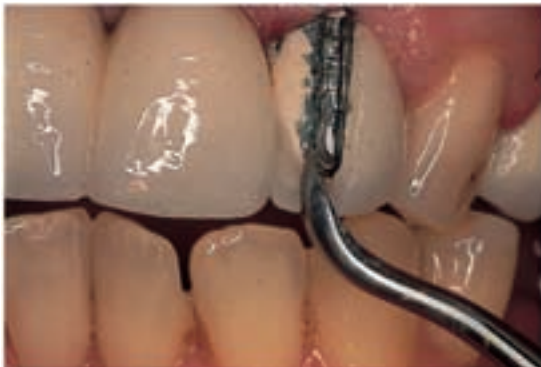*a* Removing a ceramic crown. A cut is made with a diamond bur down the labial surface and across the incisal edge. The crown can then be split with a suitable heavy-duty instrument.



*b* Removing a metal–ceramic bridge by cutting through the labial porcelain with a diamond bur.



*c* Then changing to a special metal-cutting (beaver) bur to cut through the metal until the cement just shows.

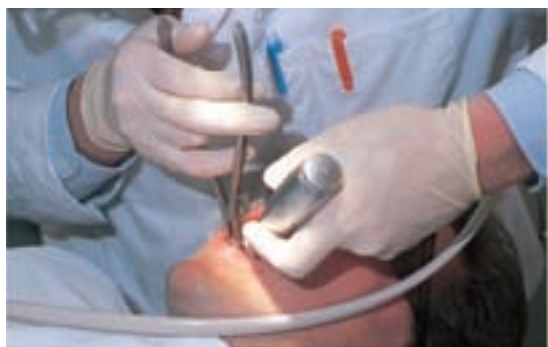

*d* Springing open the retainer with a heavy-duty instrument. It is sometimes necessary to continue the cut round to the occlusal or lingual surface.



**Figure 14.16**

a Specialized equipment for removing crowns. The pistol-shaped instrument is driven by compressed air and vibrates one or other of the attachments against the crown or bridge. The equipment is expensive and is usually only available in specialist centres.



b The equipment being used clinically.

in Figure 14.14, but they are more rigid than gold crowns and the porcelain is liable to break, so they usually have to be cut off.

A groove is cut vertically from the gingival margin to the occlusal surface, preferably on the buccal side just through to the cement, and then the crown is sprung open with a heavy instrument such as a Mitchell's trimmer or a heavy chisel, breaking the cement lute. Sometimes the cut will need to extend across the incisal or occlusal surface (Figure 14.15b, c and d).

Cast metal is best cut with a special solid tungsten carbide bur with very fine cross-cuts (beaver bur). This is capable of cutting metal without juddering or jamming, and there is less risk of the bur itself breaking than with a conventional tungsten carbide bur. Eye protection should always be worn by the patient, the dental nurse and dentist, particularly when cutting metal.

Diamond burs cut cast metal slowly, but are ideal for rapidly cutting porcelain, and so metal-ceramic units are best sectioned using different burs for the two materials. Since it is

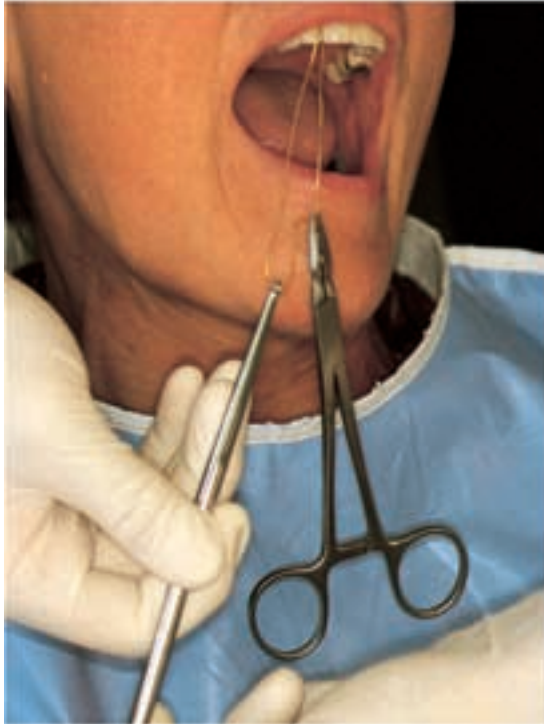
possible to cut porcelain much more quickly than metal, the metal on the buccal surface is usually thinner than that on the palatal or lingual surface, and visibility and access are far better buccally, the groove is easier to make on the buccal side.

### Removing bridges

There are three sets of circumstances:

- When the abutment teeth are to be extracted and so it does not matter if the preparations are damaged, the bridge will be removed in the most convenient way, often with a crown- and bridge-remover. In some cases it may not be necessary to remove the bridge at all, for example with simple cantilever bridges with one abutment tooth. In others it is quicker to divide the bridge through a pontic or connector and extract the abutment teeth individually with their retainers in place.





**Figure 14.17**

Removing a bridge with a soft brass wire loop.

The locking forceps are clipping the twisted ends of the wire together to prevent the sharp ends damaging the chin. The slide hammer (see Figure 14.14) is being used in the wire loop rather than under the bridge pontic. This is more controllable and effective and less dangerous.

- When it is the intention to retain the abutment teeth – either to make a new bridge or to use them to support a partial denture or an overdenture – it does not matter whether the bridge is damaged during its removal, but the preparations should be protected. The retainers should be cut and the bridge carefully removed with the bridge-remover.
- There are occasions when it would be helpful to remove the bridge intact, modify or repair it and then replace it, if only as a temporary measure. In this case neither the bridge nor the preparations should be damaged.

### Removing bridges intact

The slightly more flexible structure of all-metal bridges and of minimum-preparation bridges allows them to be removed intact rather more readily than metal–ceramic conventional bridges. However, all types can sometimes be removed by sharp tapping, which fractures the cement lute without too much risk to the periodontal

membrane of the abutment teeth. The nature of the force is quite different to the slow tearing applied in extracting teeth.

Slide hammers are specially designed for the purpose with replaceable tips to fit under retainer margins, under pontics or into embrasure spaces (Figure 14.14). Sometimes it is necessary to drill a hole in the palatal surface of the retainer or pontic and fit an attachment from the slide hammer into it.

Various other techniques can be used. Figure 14.16 shows a specialist air-driven appliance. Ultrasonic vibration with a scaler can loosen crowns and bridges.

A good technique is to make a loop of soft wire beneath the connector of the bridge and use a slide hammer in the wire loop (Figure 14.17). Alternatively, if a slide hammer is not available, a heavy metal object is passed through the loops well outside the mouth, and sharp blows applied to it with a mallet or other heavy instrument. This is a rather dramatic approach, and the patient needs to have a phlegmatic personality and to be properly informed of what is proposed beforehand.

# Index

- abrasion 5
- abutment teeth 246–8
- assessment for bridges 229–31
- caries, secondary 306–7
- definition of 197
- directions of forces 231
- fixed–fixed bridges 199
- fracture of natural tissue 307
- minimum-preparation bridges 199, 242, 244
- occlusal loading 226, 228, 231
- adaptation to extra load 226–7
- paralleling
- by extra-oral survey 247–8
- by eye 244, 246–7
- paralleling devices 248
- periodontal disease 306
- preparation design failures 307
- prognosis 189
- pulp problems 306
- radiographs 184
- and retainer choice 212, 213
- selection 235
- support
- in bridge design 225–8
- and length of span 227
- abutments, implant 180, 271
- choice of 283
- custom-made 271
- definition 261
- design 265, 270, 272
- healing 267
- screw- vs cement-retained 272, 273–4
- seating 269, 270
- see also transmucosal abutments (TMAs)
- acid-etch retained composite splints 292
- acid etching 17
- acrylic
- biteplane 89, 90
- bridges
- provisional 216, 250
- temporary 248
- on cast metal crowns 39, 107
- changing occlusal vertical dimension 116, 117
- crowns, provisional 87
- lost/worn facings 305
- partial dentures 267, 280–1
- polyacrylic veneers 15
- special trays 127–30
- temporary bridges 241, 242
- for temporary crowns 154, 155
- wire/acrylic splint 290
- adhesive bridges 209, 210
- adhesive cements 61, 171–2
- adrenaline-impregnated cord 164, 166
- age of patient
- crown planning 106, 107
- fixed vs removable prostheses 187, 188
- bridge indicated 192
- and implant restorations 264
- alginate impressions 101, 123
- for temporary bridges 247, 249
- alloys, dental 37, 45
- aluminium crown forms 154–5
- alveolar bone loss 189, 192
- implant restorations 262, 280
- amalgam cores 47, 51
- pin-retained 46, 47–8, 131
- post-retained 70, 131
- amalgam restorations 21
- bonded 20, 21–2, 27
- dislike of, by patients 22
- failing 49
- pin-retained 20, 21–2, 27
- amelogenesis imperfecta 4, 31
- anterior crowns
- alternatives to 13–18, 21
- complete 29–39
- preparations 137–40
- finishing 138, 140
- incisal/proximal reduction 137, 138, 139
- labial reduction 139
- palatal reduction 138, 140
- indications 11, 13
- life-expectancy 300
- pin-retained 66
- post-retained
- preparations 140–5
- anti-rotation notch 145
- finishing 145
- post hole preparation 140–2, 145
- post hole shaping 145, 146–7
- post insertion/cementation 142–4
- shoulder/margin preparation 140
- preparations 71–2
- inadequate 72
- vital teeth 73, 75
- for root-filled teeth 39–40
- anterior splints
- appearance 293–4
- selecting 294
- Ante's law 225, 227, 308
- appearance
- bridges 228–9
- and crown design 55–6
- and crown planning 109, 110, 112–16, 124–6
- fixed vs removable prostheses 187, 188–9, 190, 191
- bridge indicated 192
- and gender 106
- and implant restorations 280
- importance 9
- indicating crowns 7, 8, 9
- pontics 214
- porcelain jacket crowns (PJs) 37
- and retainer choice 212, 213
- splints, fixed 293–4
- veneers 13, 14–16
- appointments 118–19
- arcon articulators 94, 99
- articulating paper/foil 90–1, 154
- articulating wax 91
- articulators 94–6
- arcon 99
- fully-adjustable 100
- hand-held 98
- inadequate 99
- non-arcon 99–100
- semi-adjustable 94–6, 98
- simple hinge 98, 99
- Astra implant 261
- attrition 5
- autogenous bone grafting 189, 279
- automix guns 153, 159, 161, 166
- axial contours/surfaces of crowns
- checking/adjusting 170
- reduction 135, 137
- banding 10, 11
- beaver burs 316, 317
- Bennett angle 80
- Bennett movement 80
- beveling functional cusp 54
- biteplanes
- acrylic 89, 90
- fixed anterior (Dahl appliances) 132–3
- bleaching 12
- as alternative to crowns 13
- crown shade matching 117
- external 9, 12, 13
- internal 8, 9, 12, 13
- shade planning 125
- in tetracycline staining 11
- vital 10, 13
- bonded amalgam 20, 21–2, 27
- bone grafting 189, 279
- bone loss 189, 192, 279, 280
- implant restorations 262, 280, 289
- Brannemark system 299
- bridge abutment preparation 70
- bridge-retaining crown preparations 72
- bridges
- cleaning aids 256, 257
- clinical/laboratory techniques, inadequate 308
- components 211–24
- see also specific components
- construction 241–57
- conventional 177, 178, 197
- anterior, life-expectancy of 300
- cementation 255
- large, life-expectancy of 300
- life-expectancy 298
- loss of retention 300
- paralleling 244, 246–8
- posterior, life-expectancy of 300
- design
- abutment teeth selection 235
- anterior missing teeth 236
- alternative designs 239
- multiple 237–8

- bridges (*cont.*)
- basic 197–203
    - advantages/disadvantages 204
  - combinations 203–4
  - comparison 206–7
  - connector selection 238
  - examples of process 239
  - failures 307–11
  - hybrid 203, 204
  - inadequate 307–8
  - overprescribed 308, 309
  - pontic selection 238
  - posterior missing teeth 236
  - retainer choice 235, 238
  - selection
    - criteria 225–9
    - practical steps 234–9
    - support rule 225–8
    - underprescribed 308
    - variations 204
  - distortion 305
  - failure 185, 217
  - fixed vs removable prostheses 186–95
  - implant-supported 273
  - indications 192–3
    - compared with partial dentures/implants 177–95
  - intra-oral trials 233–4
  - life-expectancy 186
  - localization 251, 252
  - loss of retention 301
  - maintenance 256
  - materials 204–5, 208
  - oral hygiene instructions 255–6
  - patient confidence 188
  - planning 232
    - abutment teeth assessment 229–31
    - length of span 227, 231
    - occlusion 225–9, 238–9
    - predicting final result 232–3
    - ridge shape 232
    - study casts 233
    - whole patient considerations 229
  - removal 317–18
    - intact 318
    - reasons 317–18
  - repairing fractured porcelain 303–4
  - repairs 313
    - abutment teeth, removing 314
    - extending bridge 314
    - facings, replacing lost 312, 314
    - screw-retained 181
  - terminology 177–82
  - try-in stage 250
    - finished bridges 253
  - types 177–9, 197–210
  - use in UK 177
  - for young patients 107
  - see also specific types of bridge*
- brittleness
- porcelain 53
  - porcelain jacket crowns (PJs) 37
- broken-down teeth
- indicating crowns 5, 21
  - preparation 20
  - indicating veneers 14
  - restoration 21
- bruxism
- contraindicating implants 264
  - and crown choice 47
  - and crown design 55
- buccal flanges
- on dentures 188
    - partial 188, 233, 234
    - removable 189, 204
- burs 133, 134
- for anterior crowns
    - complete 137, 138, 139, 140
    - post-retained 141, 145
  - for axial reduction 135, 137
  - for occlusal reduction 135
  - for restoration removal 316, 317
  - see also drills*
- CAD/CAM *see* computer-aided design/manufacture (CAD/CAM)
- canine guidance 78, 83
- and crown planning 111
- canines, pointed 112
- cantilever bridges 71, 178, 181, 198, 201, 219
- all-ceramic 201
  - approximal surfaces 221
  - in combination designs 203
  - conventional, advantages/disadvantages of 206
  - indications 193
  - large splint bridge 202
  - life-expectancy 300
  - minimum-preparation 201, 213
    - designs comparison 207
  - occlusal assessment 232
  - occlusal forces 230
  - temporary 241
  - see also* spring cantilever bridges
- carbon-fibre posts 41
- caries
- and bridges 185
  - and crown design 59
  - development 3
  - indicating crowns 3, 11
  - secondary 185, 199, 293
  - abutment teeth 306–7
  - repair 312
- casts
- articulating 94, 102
  - occlusal surface shaping 102
  - opposing 123
  - study 71
    - bridges 232, 233
    - as contract 116
    - diagnostic wax-ups on 114, 115
    - for occlusion 93
    - pre-preparation 123
    - trial preparations on 112, 117, 118, 119, 124
    - trimming 101, 102
    - working
      - articulation 94–6
      - articulators 98–100
    - see also* wax-ups
- cast ceramic crowns 32, 33
- cast connectors 222–3
- cast (laboratory-made) posts 42, 43, 44
- cast metal abutments 271
- cast metal bridges 204
- cast metal cores 51
- construction stages 120, 121
  - preparations 147
- cast metal crowns 69
- with acrylic/composite 39, 107
  - construction stages 120, 121
  - design 53–75
- fit surfaces 67
- fracture and retention 67
  - groove-retained 47
  - posterior 45, 46
  - preparation 69
  - removal 315, 317
  - retention problems 67–8
- cast metal posts 51
- construction stages 120, 121
  - design 74
  - preparations 146, 147
- cavosurface angle 53, 54, 57
- cementation splints, fixed 295
- cements/cementation 59–61
- adhesive 61, 171–2
  - cement removal 314
  - choice of cements 171–2
  - non-adhesive 59
  - penetration into dentine 17, 61
  - technique 172
  - temporary/provisional 157
- 'centric occlusion' 79
- 'centric relation' 79
- ceramic inlays/onlays 26, 27
- computer-aided design/manufacture 26, 27
  - life-expectancy 299
- ceramic (porcelain) bridges 205
- cantilever bridges 201
  - failures 304
- ceramic (porcelain) crowns 32, 33
- advantages/disadvantages 37
  - anterior crowns
    - complete 29–37
    - prepared teeth 40
  - choosing 36
  - construction stages 120, 121
  - date of development 299
  - design 53
  - failures 304
  - implant-supported 272
  - occlusal shaping 102
  - posterior 47
  - preparations 71, 72
    - inadequate 72
    - occlusal reduction required 135
    - vital teeth 75
  - reinforced 33
  - removal 315, 316
  - resin-bonded 19, 21
  - retention problems 66–7
  - see also* porcelain jacket crowns (PJs)
- ceramic veneers *see* porcelain veneers
- Cerec CAD/CAM machine 26
- chair-side bleaching 13
- chair-side milled restorations 33
- chair-side temporary bridges 241, 248–9
- chair-side temporary crowns 130
- injection technique 150–2, 155
  - with laboratory-produced mould 153
- moulding technique 154, 155
- children
- bridges for 106, 107
  - crowns for 106, 107
  - oral hygiene 108
- cleansability
- bridges 228
  - intracoronal splints 293
  - pontics 214, 218, 219
- cleft palates
- bridges supporting 184, 185
  - indications for fixed splints 287–9

- collapsed bite 86
- complete-crown splints 292  
preparation 294–5  
preparations 293
- composite cores 41, 51, 72, 130  
pin-retained 20, 48, 49, 136
- composite crowns 41
- composite inlays/onlays 22, 24, 27
- composite luting cement 61
- composite materials 9  
bridge facings 204
- composite restorations  
as alternative to crowns 13, 23  
appearance 8  
cores 20  
Dahl effect 87, 89, 133  
failing 8  
posterior teeth 22, 23  
veneers 13–14, 18, 21
- composite splints 292
- compressed air for gingival retraction 162, 163, 166
- computer-aided design/manufacture (CAD/CAM)  
ceramic inlays/onlays 26, 27  
cores 33  
crowns 33
- connectors (joints)  
cantilever bridges 203  
combination bridges 205  
definition of 197  
failures 304  
fixed 222–3  
fixed–fixed bridges 197  
fixed–movable bridges 199, 200, 203  
hybrid bridges 204  
precision-attachment 224  
selection 238
- connectors, movable 224
- construction  
bridges 241–57  
abutment teeth preparation  
conventional bridges 244–8  
minimum-preparation bridges 242–4  
cementation  
conventional bridges 255  
minimum-preparation bridges 252–3  
permanent 252  
temporary/provisional bridges 250  
trial 252  
occlusal records 251  
preoperative procedures 241–2  
provisional 249–50  
temporary 248–9, 250  
try-in stage 253  
finished bridges 252  
metal framework 251  
separate units 252  
working impressions 250
- crowns  
clinical stages 120–1  
laboratory stages 120–1  
impression trays 127–30  
porcelain veneers 29
- contacts see occlusal contacts
- contraindications  
of any prostheses 195  
implant restorations 264–5
- copper bands 48, 51
- cord for gingival retraction 164–5, 166
- cores 27–8  
assessing need for 117  
bonded 20  
building up 130  
and crown planning 110  
pin-retained 20, 45, 46, 47–8, 49, 131  
in children 107  
pin placement 130  
in vital tooth 51  
post-retained 49, 70, 131  
design 74  
for posterior crowns 47–51  
with posts 41, 43  
removal/removal instruments 315  
in root-filled teeth 21, 41, 51  
see also *specific types*; *specific types of core*
- cost  
bridges 186  
ceramic crowns 37  
crowns 107–8  
implants 186  
metal–ceramic crowns 37, 39  
partial dentures 186  
retainers 214
- crossarch splinting 183, 228, 238
- crossbite, posterior 83
- crown lengthening 57–8, 63, 124  
minimum-preparation bridges 244  
for retention 118  
for worn teeth 133
- crowns  
alternatives to 13–18, 21  
anterior see anterior crowns  
assessment on recall 173  
beveling functional cusp 54  
complete, as retainers 211  
repairing fractured porcelain 312  
designing preparations 53–75  
specific crowns 73–5  
dislodgement 60  
directions 63–4  
failures, mechanical 302–5  
vs fillings 3, 111  
fitting  
checking/adjusting stage  
contact points/axial contours 170  
die overtrimming 169, 170  
fit 168–9, 170  
occlusion 170–1  
retention 169–70  
try-in stage 167–8  
indications 3–13  
anterior 11, 13  
appearance 8, 9  
badly broken-down teeth 5  
caries 3, 11  
combined 7–8  
function 7, 9  
hypoplastic conditions 5, 7, 11  
mechanical problems 9, 11  
multiple crowns 8  
support of other restorations 7, 13  
tooth characteristics 7  
tooth wear 5–6, 11  
trauma 4, 5, 8, 11  
life-expectancy 298  
maintenance by patient 172–3  
making, clinical/laboratory stages of 120–1  
partial 20, 27  
path of insertion 56, 62, 73  
difficult 134
- planning 105–18  
clinical/laboratory stages 118–21  
core, need for 117  
detailed planning 111–17  
individual tooth considerations 110–11, 117  
material, choice of 117  
type, choice of 117  
whole mouth considerations 108–10  
whole patient considerations 105–8
- posterior see posterior crowns
- preparation of teeth 20, 63  
design 53–75  
on extracted teeth 59, 60  
finishing 134  
instrument choice 134  
parallel opposing walls 65  
planning 111, 123–4  
stages 134–5  
taper/length and retention 63, 64, 65, 69
- removal 315–16, 317  
instruments 315, 317, 318
- repair 173
- retention 61–7, 72  
against displacing forces 62–6  
vertical loss 62–3  
failure, other causes of 66–7, 72  
retentive features 63
- section at dentine/cement interface 62, 63
- shade planning 116–17, 124–6  
selection technique 124–6
- spacing 56–7
- support from other teeth 109–10  
types 29–51  
see also *specific types*
- cusps, functional, in crown design 54
- Dahl appliances 87, 88–9, 103, 248  
for axial tooth movement 214  
for worn teeth 132–3
- Dahl effect 230, 232  
with composite 87, 89
- Denar articulator 94
- dentine destruction in caries 3
- dentinogenesis imperfecta 5, 106, 107
- dentures  
implant-supported 275  
occlusal design 78–9  
premature contact 84  
see also partial dentures
- design  
bridges  
anterior missing teeth 236  
alternative designs 239  
multiple 237–8  
basic 197–203, 204  
combinations 203–4  
comparison 206–7  
connector selection 238  
examples of process 239  
hybrid 203, 204  
pontic selection 238  
posterior missing teeth 236  
retainer choice 235, 238  
selection  
criteria 225–9  
practical steps 234–9  
support rule 225–8  
variations 204

- design (*cont.*)  
 crown application to tooth 117  
 crown preparations 53–75  
 adjacent teeth, related to 56–7  
 appearance-related 55–6  
 function-related 54–5  
 material-related 53  
 periodontal tissue-related 57–9  
 pulp-related 59  
 specific crowns 73–5  
 failures 307–11  
 implant restorations 265–75  
 minimum-preparation designs comparison 207  
 see also planning
- diastemma 6, 7, 112  
 and bridge planning 234  
 and implants 195, 198  
 and spring cantilever bridges 198
- Dicor crowns 32, 33
- direct bridges 208
- dome-shaped pontics 215, 216, 219  
 buccal surface 222  
 cleansability 256
- drills 142, 148  
 see also burs
- eating disorders and tooth erosion 132  
 eating with missing teeth 182, 183
- elastomeric impression materials 157, 160, 252, 268  
 relining 161
- elderly patients 106, 188
- electrosurgery for gingival haemorrhage 166  
 embrasure spaces, open 220, 221
- Empress crowns 31
- enamel hypoplasia 5  
 and crown design 57
- erosion 5, 38  
 incisal 132  
 palatal 88, 112, 132  
 reflux 89, 116  
 management 132  
 temporary crowns for 151  
 see also broken-down teeth; tooth/teeth, wear
- facebow record 94
- failures  
 amalgam restorations 49  
 bridges 185, 217  
 causes/solutions 300–11  
 ceramic bridges 304  
 ceramic crowns 304  
 composite restorations 8  
 connectors (joints) 304–5  
 crown retention 66–7, 72  
 defining, difficulties with 297–8  
 fillings 9  
 implant restorations 275, 285  
 recording 297  
 retrospective surveys 297  
 soldered connectors 304–5  
 veneers 15, 18  
 see also design, failures
- fibre-reinforced composite crowns 36, 39
- fibre-reinforced splint 292
- fillings  
 vs crowns 3, 111  
 failing 9
- fixed-fixed bridges 197–8, 199  
 abutment teeth 199
- approximal surfaces 221  
 in combination designs 203  
 conventional 206  
 failures 301  
 hybrid designs 204  
 life-expectancy 300  
 loss of retention 300–11  
 minimum-preparation designs comparison 207  
 non-parallel abutments 223  
 paralleling 244, 246–8  
 temporary 241  
 unsatisfactory design 199
- fixed-movable bridges 198, 199–200, 202, 213  
 in combination designs 203  
 conventional 206  
 hybrid designs 204  
 life-expectancy 300  
 minimum-preparation 200, 202  
 designs comparison 207  
 temporary 241  
 trial preparations for 119
- fixed partial dentures see bridges
- fixed splints see splints, fixed
- fixed vs removable prostheses 78–9, 186–95  
 dental issues 189, 191  
 patient issues  
 age/sex/occupation 188, 192  
 appearance 187, 188–9, 190, 191, 192  
 attitude 186–8  
 health/confidence 188
- fixtures see under implant restorations
- flexi-wire splints 289, 292
- full arch mirrors 246
- fully-adjustable articulators 100
- function, indicating crowns 7, 9
- functional cusps 135
- 'fuse-box' principle 205
- gender  
 and crowns 106  
 fixed vs removable prostheses 188
- gingival blanching 269
- gingival hyperplasia 57
- gingival margins  
 in crown planning 113  
 minimum-preparation bridges 242  
 oral hygiene 255  
 retraction 162–6  
 compressed air 162, 163, 166  
 cord/impregnated cord 164–5, 166  
 electrosurgery 166  
 kaolin pastes 163–4, 166
- gingival prostheses 189
- gingival tissue  
 and bridges 186  
 and crowns 58
- glass ionomer core 40, 41  
 glass ionomer crown 41  
 glass ionomer luting cements 61, 172
- gold  
 abutments 271, 272  
 casts 69  
 copings 273, 313  
 crowns 46, 67, 69  
 checking/adjusting 168  
 metal-ceramic 37  
 preparation for 135  
 as retainers 200  
 wear 305
- diaphragm for retention 111  
 framework 273, 275
- inlays/onlays  
 bridge repair 314  
 as retainers 200, 205, 213  
 post crowns 41, 45  
 restorations 21
- gold inlays/onlays  
 inlays/onlays  
 in metal-ceramic bridges 205  
 posterior teeth 20, 22–5, 27  
 preparation 25
- grooves  
 buccal depth indicator 139  
 reference 134, 138, 139  
 for retention 54, 63, 64, 65, 135  
 partial crowns 66, 75  
 posterior crowns 68, 73, 75
- group function  
 and crown planning 111  
 occlusion 78, 83, 111
- 'half' crowns 47  
 healing abutments 180
- Hi-Ceram crowns 29, 31
- home bleaching 13
- hot transfer-moulded ceramic crowns 33
- hybrid bridges 203, 204  
 life-expectancy 300
- hydrophilic impression materials 161
- hypodontia 7, 107, 194, 262
- hypoplastic conditions indicating crowns 5, 7, 11
- implant restorations 182, 261–85  
 abutment transfer jig 274  
 alveolar bone loss 262, 280  
 appearance 280  
 vs bridges 264, 265  
 bridges 275  
 caution with 280  
 completed 270, 272  
 radiograph of 267, 270
- components  
 abutments 271  
 angled 272  
 choice of 283  
 customized 270, 271  
 definition 261  
 design 265, 270, 272  
 healing 267  
 materials 272  
 screw- vs cement-retained 272, 273–4  
 seating 269, 270  
 selection kit 284  
 titanium 266
- implants 261, 266  
 definition 261  
 description 265, 278  
 numbers/positions 277, 278, 280  
 placement 281, 282  
 survival 275–7  
 restorations 272, 275  
 assessment 285  
 cemented 285  
 definition 261  
 placement 285  
 provisional 280–1  
 screw-retained 266
- contraindications 264–5

- cross-section 180
- date of development 299
- design 265–75
- failure 275, 285
- gingival blanching 269
- gingival portion 269
- impressions 284
  - copings 267, 283, 284
  - impression-taking 268
- indications 194–5, 262–4
- life-expectancy 299
- maintenance 285
- multiple, life-expectancy of 300
- multiple, linked 275
- osseointegration 261
- planning 265, 277–81
- principles 261–2
- procedures
  - restorative 283
  - surgical
    - immediate placement/restoration 283
    - one-stage implants 281
    - stents 279, 280, 281
    - two-stage implants 281–3
  - radiographs 267, 270, 280
  - shade planning 268
  - single tooth 180, 275, 276
    - life-expectancy of 300
- implant-retained prostheses 182
  - advantages 185
  - use in UK 177
- implant-supported bridge 181, 182
- impression materials 157, 158, 160–1
  - and gloves 162
- impression trays
  - choosing 126
  - making 127–30
- impressions 126, 157–62
  - of bridges 250
    - minimum-preparation 252
  - gingival retraction 162–6
  - implant copings 267, 283, 284
  - localizing 252
  - for splints 295
  - techniques 162
- In-Ceram crowns 29, 31, 33
- incisors
  - crowns for 4
    - lower incisor preparation 61
    - peg-shaped lateral incisors 4, 19
    - rotated laterals 118
  - length 116
  - reshaping, temporary 116, 117
  - veneers, preparation for 17
- inclination of tooth indicating crowns 7
- indications
  - bridges 192–3
    - compared with partial dentures/implants 177–95
  - crowns 3–13
    - anterior 11, 13
    - appearance 7, 9
    - broken-down teeth 5, 21
    - caries 3, 11
    - combined 7–8
    - function 7, 9
    - hypoplastic conditions 5, 7, 11
    - mechanical problems 9, 11
    - multiple crowns 8
    - posterior 21
  - root-filled teeth 21
    - support of other restorations 7, 13, 21
  - tooth characteristics 7
  - tooth wear 5–6, 11
    - trauma 4, 5, 8, 11
- implant restorations 194–5, 262–4
  - partial dentures 194
  - splints, fixed 287–90
    - cleft palate 287–9
    - periodontal disease 287
    - retention
      - additional 289
      - orthodontic 287
      - trauma 287
  - informed consent 105, 188
  - inhaled crowns 167–8
  - inlays
    - ceramic 26
    - composite 22, 24
    - gold
      - posterior teeth 20, 22–5, 27
      - preparation of 25
  - insertion/cementation of crown 172
  - insertion paths
    - bridges 223
    - crowns 62, 73, 223
    - difficult 134
  - intercuspal position (ICP) 79, 80
    - adjustments 103
    - contacts 82
    - dentures 84
    - occlusal adjustment in 102–3
    - recording 97, 166–7
  - intermediate splints 290, 292
  - interocclusal space, creating 85, 87
  - intraoral retainers 211, 230
  - intraoral splints 293
- joint, definition of 197
- kaolin pastes for gingival retraction 163–4, 166
- keratinization under pontics 218, 220
- laboratory-made (cast) posts 42, 43, 44
- laboratory-made provisional bridges 249–50
- laboratory-made provisional restorations 157
- laboratory-made temporary bridges 241, 242
- laboratory-milled cores/crowns 33, 35
- laboratory temporary crowns 130
- laser welded connectors 223
- lateral excursion 77, 78, 82, 83
  - difficulty with 84
- lateral guidance 80
- layered restorations 22
- life-expectancy 297
  - anterior crowns 300
  - bridges 186
    - conventional 298
      - anterior 300
      - large 300
      - posterior 300
    - minimum-preparation 298–9
  - cantilever bridges 300
  - crowns 298
    - fixed–fixed bridges 300
    - fixed–movable bridges 300
    - hybrid bridges 300
  - implant restorations 299
  - implants
    - multiple 300
    - single tooth 300
  - minimum-preparation bridges 300
  - porcelain inlays/onlays 299
  - porcelain veneers 18, 299, 300
  - posterior crowns 300
- light-cured acrylic special trays 127–9, 130
- light-curing box 129
- loss of retention
  - conventional bridges 300
  - fixed–fixed bridges 300–11
  - minimum-preparation bridges 300–11
  - solutions 300–11
- maintenance
  - of bridges 185
  - of crowns 172–3
- making restorations see construction
- malocclusions see occlusal problems
- mandible 83
  - dysfunction 87, 89–90, 93
  - movements 79–83
    - border 80
    - lateral 77, 78, 82, 83
    - protrusive 80
    - retrusive 80, 82
- manufacture see construction
- marginal deficiencies 309–10
  - repairs in situ 312
- margins of crown
  - assessment on recall 173
  - and crown design 55–6
  - marginal configurations 53, 54
  - marginal fit 37
    - subgingival vs supragingival 56, 57
- Maryland bridges 209, 210
- mechanical problems indicating crowns 9, 11
- mercury allergy/toxicity 22
- metal bridges see cast metal bridges
- metal–ceramic bridges 204, 251
  - with all-metal posterior retainers 208
  - combined with gold inlay 205
  - metal framework 250
  - processing temperatures 205
  - provisional 250
  - removal 316
- metal–ceramic crowns 32, 37–9
  - advantages/disadvantages 38–9, 45–6
  - construction stages 120, 121
  - design 53, 60, 73, 75
  - groove-retained 46
  - implant-supported 272
  - pin-retained 45, 46
    - and pin-retained cores 51
  - post-retained, one-piece 38, 45
  - posterior 45–6
  - preparation 38
  - preparations 70, 72, 136
    - anterior vs posterior 37–8
    - bridge-retaining crowns 72
    - occlusal reduction required 135
    - removal 315, 317
- metal–ceramic pontics 214, 215
- metal–ceramic restorations 299
- metal–composite bridges 250
  - provisional 250
  - temporary 249
- metal crowns see cast metal crowns
- metal posts 41
- Metalor Stylepress crowns 31
- metals, dental 37, 45

- Michigan splint 89  
microdontia 107  
  and crown design 59  
milled crowns 33, 35  
minimum-preparation bridges 177, 178,  
  192–3, 197, 229, 238  
  abutment teeth 199, 242, 244  
  advantages 185  
  advantages/disadvantages 210  
  appointments  
    first 253  
    second 254  
  on augmented ridge 191  
  cantilever 201, 213  
  cementation 252–3  
  contraindications 195  
  date of development 299  
  designs comparison 207  
  direct bridges 208  
  fixed-fixed 199  
  fixed-movable 199, 200, 202  
  laboratory stage 253  
  life-expectancy 298–9, 300  
  loss of retention 300–1  
  macro-mechanically retentive (Rochette)  
    bridges 210  
  occlusal assessment 232  
  overpreparation 242  
  preparations 242, 243  
  as provisional implant restorations 281  
  spring cantilever 197  
  success with 255  
  wax-up for 73  
  for young patients 188  
minimum-preparation retainers 197, 204,  
  211, 213  
  design 245  
  tooth tissue conservation 211, 212  
minimum-preparation splints 292  
missing teeth see replacement of missing  
  teeth  
Mitchell's trimmer 315, 317  
modified ridge-lap pontics 215, 219  
movement of teeth 307  
multiple crowns 8  
multiple implant retained restorations 299  
mylar matrix strips 93  
Nayyar cores 50, 51, 131  
nickel chromium 37, 209  
non-arcon articulators 99–100  
occlusal contacts 82  
  checking/adjusting crowns 170  
occlusal disharmony 84  
occlusal forces 200  
occlusal harmony 84  
occlusal interference 80, 83–4  
  detection 89–90  
  in intercuspal position 84  
  non-working-side 82  
  and overeruption 83  
  of restorations 103  
  and temporomandibular dysfunction 87  
  treatment 90  
occlusal loading of abutment teeth 226, 230  
occlusal marking materials 90–1, 102  
occlusal problems  
  indicating bridges 189, 191  
  in restorations 310–11  
occlusal records 82, 166  
  silicone 92–3, 166  
  trimming 166, 167  
  wax 166–7  
occlusal relationships, maintaining 97–8  
occlusal stability 85, 86  
  and missing teeth 183, 184  
  of restorations 103  
occlusal stops 85  
occlusal surface reduction 68  
occlusal vertical dimension (OVD) 85  
  bridges restoring 184  
  crown planning 116, 117  
  increased 86  
  loss with erosion 89  
  occlusal records 100  
  for worn teeth 133  
occlusal wear/perforation 305  
occlusion 7, 170–1  
  adjustments/alteration 7, 93, 97  
    bridges 252  
    in intercuspal position 102–3  
    restorations 103, 238  
    before cementing 102–3, 170–1  
    techniques 103  
  'balancing side' 83  
  bridges 231, 232, 238–9  
  canine-guided 78, 83, 111  
  clinical/laboratory management 97–8  
  crowns  
    checking/adjusting 102–3, 170–1  
    planning 110–11  
    preparation design 54–5  
    surface reduction 55  
  design 78–9  
  examination/analysis 90–7  
    clinical aids 90–3  
    clinical examination 90  
  fixed vs removable prostheses 78–9  
  functional approach 77–9  
  group function 78, 83  
  lateral excursion 77, 78, 82, 83  
  measurement 85  
  objectives in crown-/bridge-making 97  
  orthodontic approach 77–8  
  premature contact 84  
  recording 97, 98–100  
  and retainer choice 214  
  of tooth, indicating crowns 7  
  occupation and choice of restoration 107,  
    184–5, 188  
    bridge indicated 192  
oligodontia 107  
onlays  
  composite 22  
  gold 22–5, 27  
oral hygiene  
  bridges 189  
  instructions 256  
  crowns 108, 109, 119  
    design 56–7  
    instructions for 172–3  
    on recall 173  
orthodontic retention 183  
osseointegration 261  
overbite, complete 191  
overeruption  
  anticipated 86  
  bridge planning 235, 238  
  and occlusal interference 83, 238  
  and occlusion 97–8  
  and palatal erosion 88  
overtrimmed die 169, 170  
palatal reduction 38  
parallel-sided posts 49  
  smooth/serrated 42, 43, 44, 51  
  threaded 42, 44–5  
paralleling abutment teeth 244–8  
  by extra-oral survey 247–8  
  by eye 244, 246–7  
paralleling devices 248  
partial crowns 47, 49  
  fit surfaces 66  
  fracture and retention 67  
  posterior 75  
  as retainers 211  
  rigidity 66  
partial dentures 109, 179, 182  
  and bridge planning 233, 234  
  as first alternative 186–7  
  and implant restoration 267  
  indications 194  
  patient anxiety 188  
  for young patients 188  
patient  
  advice to 299  
  attitude  
    crowns 105  
    fixed vs removable prostheses 187  
    informed consent 105–6  
peg-shaped lateral incisors 4, 19, 58  
periodontal disease  
  abutment teeth 231, 306  
  indications for fixed splints 287  
periodontal splinting 183  
periodontal tissue  
  and bridges 186, 189, 235  
  and crowns 186  
  design 57–9  
  planning 109, 110  
permanent splints 290, 292  
petroleum jelly-zinc oxide cement 157, 252  
photographs  
  clinical, in planning 123  
  image manipulation 115–16  
pier, definition of 197  
pin-retained amalgam 20, 21–2, 27, 47–8  
pin-retained cores 20, 46, 47–8, 49, 130, 131  
pin-retained crowns 66  
planning  
  bridges 229–34  
    abutment teeth assessment 229–31  
    length of span 227, 231  
    occlusion 231, 238–9  
    ridge shape 232  
    whole patient considerations 229  
  crowns 105–18  
    appearance 124–6  
    clinical modifications 117  
    clinical stages 118–21  
    core, need for 117  
    detailed planning 111–17  
    individual tooth considerations 110–11,  
      117  
    laboratory stages 118–21  
    material, choice of 117  
    pre-preparation 123  
    preparation 123–4  
    type, choice of 117  
    wax-ups 112–13  
    whole mouth considerations 108–10  
    whole patient considerations 105–8  
  implant restorations 265, 277–81  
  see also design

- plastic strips 93  
polyacrylic veneers 15  
polycarbonate temporary crown preparations 145, 149  
polycarboxylate cements 157  
polyether impressions  
  material 158, 161  
  mixing machine 159–60, 161  
  technique 162  
polymerization contraction 22  
pontics 214–22  
  for cantilever bridge 181  
  definition of 197  
  design principles 214  
  effects on ridge 218, 220  
  inflammation around 218, 220  
  materials 222  
  strength of 214, 215  
  surfaces  
    approximal surfaces 221  
    buccal 221  
    lingual 222  
    occlusal surface 221  
    ridge surface 215–20  
    cleaning technique 255  
porcelain  
  advantages/disadvantages 37  
  chips/fractures, repairs to 302–4  
  polishing instruments 311  
  properties 53  
  repairs in situ 312  
  strength of 29  
  surface defects 311  
porcelain bridges *see* ceramic (porcelain) bridges  
porcelain connectors 223–4  
porcelain crowns *see* ceramic (porcelain) crowns  
porcelain facings, repairing 302  
porcelain inlays/onlays *see* ceramic inlays/onlays  
porcelain jacket crowns (PJs) 29–31  
  advantages/disadvantages 37  
  feldspathic 29  
  fractured, repair of 313  
  strength of 29, 33  
  strengthened 29, 31  
porcelain veneers 13, 14–17, 18  
  alternatives to 21  
  cements 172  
  date of development 299  
  life-expectancy 298–9, 300  
  manufacture 29  
posts/post systems  
  cast (laboratory-made) 41, 42, 43, 44  
  choosing 44–5  
  and cores 41, 49  
  and crown planning 110  
  for crown retention 35, 39, 41, 51  
  direct/indirect 41  
  impressions 158  
  materials 41  
  preformed 41, 42, 44, 49  
  removal/removal instruments 315  
  in root-filled teeth 51  
  shapes 41–4  
  temporary 156  
post hole cutters 148  
post-retained cores 49, 131  
post-retained crowns 41  
  as abutment teeth 231  
  design 75  
  metal–ceramic 38  
  one-piece 38, 45  
posterior crowns 20, 21  
  alternatives to 21–7  
  complete 45–7, 73  
  indications 21  
  life-expectancy 300  
  partial 47, 49, 75  
  preparations 68–9, 70, 135–7  
    axial reduction 137  
    finishing 137  
    margins 137  
    occlusal reduction 135  
posterior restorations  
  choosing 27–8  
  root-filled teeth 21  
  tooth-coloured 22  
  for weak cusps 22–3, 27  
precision-attachment connectors 224  
precision-attachment partial dentures 179, 182  
preformed posts/post systems 41, 42, 44, 49  
preformed temporary crowns 130  
pressed ceramic crowns 31, 34  
Procera 33  
  cores 35  
  crowns 35, 152  
prospective surveys 297  
prostheses contraindicated 195  
provisional bridges 107, 155–6, 234  
  fibre-reinforced 39  
  laboratory construction 249–50  
  long-term 156–7  
  metal–composite 250  
  *see also* temporary bridges  
provisional crowns 48, 87, 155–6  
  cementation 157  
  fibre-reinforced 39  
  long-term 156–7  
  vs temporary crowns 155–7  
  for worn teeth 133  
  *see also* temporary crowns  
provisional restorations 39, 97, 103  
  laboratory-made 157  
  *see also* temporary restorations  
pulp tissue  
  abutment teeth, problems in 306  
  bridges damaging 185  
  and crown design 59  
  and crown planning 110  
putty and wash impressions 162  
PVC slips 150, 155  
quartz-fibre posts 41, 43  
quartz-fibre-reinforced composite splint 289  
radiography  
  hypodontia 279  
  implant restorations 267, 270, 280, 285  
  on recall 173  
recall of patients 173  
reinforced porcelain crowns 33  
removable bridges 177, 179, 204  
removable prostheses *see* fixed vs removable prostheses  
repairs  
  crowns 173  
  porcelain chips/fractures 302–4  
replacement of missing teeth  
  advantages 183–5  
  decisions 182–3  
  disadvantages 185  
resin-based/resin-modified cements 61, 171–2, 254  
resin-bonded ceramic crowns 19, 21, 33, 36  
resin-retained bridges 210  
resorption and pontic modification 220  
restorations 182  
  dates of development 299  
  failing  
    adjustments in situ 311–12  
    assessing seriousness 311  
    repairs in situ 312  
  marginal deficiencies 309  
    defects 309–10  
    negative ledge 309  
    positive ledge (overhang) 309  
    repairs in situ 312  
  occlusal considerations 77  
  polishing/grinding 311–12  
  shape/colour problems 310  
retainers 211–14  
  choosing 212–14  
  definition of 197  
  major/minor 211  
  marginal deficiency repairs 309–10  
  materials 212  
  ‘metal shine-through’ 212, 213, 230  
retention  
  crowns 27, 59–67  
    ‘adhesive’ 59, 61  
    and casting difficulties 67–8  
    checking/adjusting 169–70  
    crown fracture/distortion 66–7  
    crown lengthening for 118  
    crowns 61–7, 72  
    displacing forces 60, 62–6  
    mechanical 59  
    retentive features 64  
    tooth tissue fracture/distortion 66  
    trial wax-ups 112  
    and fixed splints 289  
  orthodontic  
    indications for fixed splints 287  
    and missing teeth 184  
    and retainer choice 212, 214  
  retrospective surveys 297  
  retruded arc of closure/movement 79  
  retruded contact position (RCP) 79, 80  
  contacts 82  
  dentures 84  
  difficulty with 84  
  occlusal interference 83  
  recording 97, 166–7  
  reversible hydrocolloid impression materials 157, 158, 160, 161, 295  
  ridge augmentation 189, 190–1  
  ridge-lap pontics 215, 217, 219  
  ridge shape and bridges 232  
  ridge surface of pontic 215–18  
  Rochette bridge 208, 234, 281  
  Rochette splint 292  
  root-filled teeth 40  
    as abutment teeth 231  
    anterior crowns 39–40  
    composite restoration 40  
    and crown planning 110  
    and pin-retained cores 51  
    posts in 51  
    restoration 21  
  root length and crown planning 111



- saddle, definition of 197  
 saddle pontics 218  
 safety precautions at try-in stage 167–8  
 self-curing acrylic trays 127–8, 130  
 semi-adjustable articulators 94–6, 98  
 'seven-eighths' crowns 47  
 sex *see* gender  
 shade  
   checking/adjusting 170  
   planning 116–17, 124–6  
   implant restorations 268  
 shade guide 124–6  
 shade maps 126  
 shade-taking device 125  
 shape *see* under tooth/teeth  
 shimstock 91, 93, 103  
 'short root syndrome' 262  
 short-term splints 290, 292  
 shortened dental arch 182  
 silicone impressions  
   materials 158  
   occlusal record 92–3  
   techniques 162  
 silicone occlusal records 166  
 silicone putty matrix 139, 283, 284  
 silicone 'seating' cement 252  
 sleeve crowns 312, 313  
 slide hammers 315, 318  
 smoking 264  
 social development and dental appearance 11  
 social history and crowns 107  
 soldered connectors 223  
   failures 304  
 span, definition of 197  
 speech and missing teeth 183  
 splinting 183, 189  
   in combination with bridges 202, 204  
   crossarch 183, 228, 238  
   periodontal 183  
 splints, fixed 287–95  
   advantages 292  
   anterior  
     appearance 293–4  
     selecting 294  
   cementation 295  
   indications 287–90  
     cleft palate 287–9  
     periodontal disease 287  
   retention  
     additional 289  
     orthodontic 287  
     trauma 287  
   intermediate 290, 292  
   permanent 290, 292  
     clinical techniques 294–5  
     vs removable 290  
     short-term 290, 292  
     temporary 295  
 sport players, crowns for 106  
 spring cantilever bridges 197, 198, 203  
   minimum-preparation 197  
 staining of teeth 7  
   banding 10  
   and bleaching 11  
   correction 9  
   tetracycline 10, 11, 12  
   vital 12  
 stainless-steel temporary crowns 145, 154, 155  
 stents, surgical 279, 280, 281  
 Straumann implant 266  
 strengthened ceramic crowns 29, 31  
 superfloss 255, 256, 257  
 surgical ridge augmentation 189, 190–1  
 surveys  
   prospective 297  
   retrospective 297  
 swallowed crowns 168  
 Tanner appliance 89  
 tapered posts  
   smooth/serrated 43–4, 51  
   threaded 42, 44, 45  
 temporary bridges 234  
   chair-side construction 248–9  
   materials 248  
   *see also* provisional bridges  
 temporary crowns 155  
   cementation 157  
   planning 130  
   post-retained 155, 156  
   preformed 145, 154–5  
   vs provisional crowns/bridges 155–7  
   removing 167  
   *see also* provisional crowns  
 temporary posts 156  
 temporary restorations 97–8  
   *see also* provisional restorations  
 temporomandibular dysfunction (TMD) 87, 89–90  
 terminal hinge axis (THA) 79, 80  
 tetracycline staining 10, 11, 12  
 'three-quarter' crowns 47  
 tilted teeth  
   in crown design 54–5  
   crown preparation 71  
 titanium crowns 33  
 titanium implants 261  
 titanium posts 41  
 tooth-grinding *see* bruxism  
 tooth/teeth  
   inclination 7  
   occlusion *see* replacement of missing teeth  
   replacement *see* replacement of missing teeth  
   shape/size  
     indicating crowns 6, 7  
     peg-shaped lateral incisors 4, 19  
     supporting reconstructions 109–10  
   tilted 54–5  
   value of, in crown planning 110  
 wear  
   and crown design 59  
   future, and crown design 55  
   indicating crowns 4, 5–6, 11  
   management 6, 130–3  
 tooth tissue  
   conservation  
     and bridge design 228  
     and retainers 211, 212  
   destruction/removal  
     in bridge design 227  
     in bridge preparation 185  
     in crown preparation 37, 39, 55, 56, 134  
     central incisors 71  
     and retention 66  
 transmucosal abutments (TMAs) 180–1, 182  
   *see also* abutments, implant  
 trauma 4, 21  
   indicating crowns 5, 11  
   indicating fixed splints 287  
 ulceration around pontics 218, 220  
 unit, definition of 197  
 veneers 15  
   appearance 13, 14–16  
   cement penetration 17  
   composite 13–14, 18, 21  
   cost 18  
   failing 15, 18  
   life-expectancy 18, 299  
   physical properties 18, 21  
   polyacrylic 15  
   porcelain 13, 14–17, 18, 115  
     alternatives to 21  
   preparation 15, 16, 17  
   reversibility 13, 18  
 vital teeth, anterior crowns on 73, 75  
 wash-through pontics 215, 216, 219  
   buccal surface 222  
   cleansability 256  
 wax-added technique 102, 103  
 wax carving 102, 103  
 wax occlusal records 91, 133, 166–7  
   relining 167  
 wax-ups  
   'cheating' 113  
   diagnostic (trial) 112–13, 124  
   bridges 233  
   constructing temporary restorations-  
     114, 115  
   implant restorations 280  
   for temporary crowns 151  
 wear *see* tooth/teeth, wear  
 wind instrument players 107, 184–5, 188  
 wing, definition of 197  
 wire/acrylic splint 290  
 wire/composite splints 290, 292  
 wire loop for bridge removal 318  
 working impressions *see* impressions  
 zinc oxide-petroleum jelly cement 157, 252  
 zinc phosphate cements 157, 171, 255, 295  
   removal 314  
 zirconia 33, 47, 272

# Planning and Making Crowns and Bridges

Fourth Edition

This highly successful text, which has achieved wide acclaim among practitioners and is a recommended text in the major dental schools, has again been revised and updated to keep it at the forefront of clinical practice. As before, the intention is to help solve real clinical problems by guiding dentists to make the right initial decision and then carry it through. This new edition includes significantly expanded material on veneers and implants in particular, so as to help dentists advise patients in their choice of what to do and how to make informed choices.

#### FROM REVIEWS OF PREVIOUS EDITIONS:

*'well thought out and exceedingly well presented. I can wholeheartedly recommend this work as a worthwhile addition to any practitioner's bookshelf.'* British Dental Review

*'the greatest strength of the book lies in the sensible and comprehensive way it provides descriptions of clinical procedures'* British Dental Journal

*'must be considered a "best buy" for every practitioner interested in a planned approach to crown and bridgework'* Dental Update

*'should be on every dentist's bookshelf'* Dental Practice

#### WITH OVER 600 COLOUR AND BLACK-AND-WHITE PHOTOGRAPHS

#### CONTENTS:

Indications and contraindications for crowns • Types of crown • Designing crown preparations • Occlusal considerations • Planning and making crowns • Clinical techniques for making crowns • Indications for bridges compared with partial dentures and implant-retained prostheses • Types of bridge • Components of bridges: retainers, pontics and connectors • Designing and planning bridges • Clinical techniques for bridge construction • Dental implants • Fixed splints • Crown and bridge failures and repairs

**Bernard GN Smith, BDS, PhD, MSc, MRD, FDSRCSEng, FDSRCSEdin**, studied at the Universities of London and Michigan and spent a number of years in general practice. He is Professor Emeritus of Conservative Dentistry at Guy's, King's and St Thomas' Dental Institute, Guy's Hospital, London, and has served as examiner at several universities in the UK and other countries and at the Royal Colleges of Surgery of England, Glasgow and Edinburgh, as Honorary Consultant in restorative dentistry to the British Army and as past President of the British Society of Restorative Dentistry. He has contributed to a wide range of dental journals and is the former editor of *Restorative Dentistry*. He is the joint author of *Pickard's Manual of Operative Dentistry*.

**Leslie C Howe, BDS, FDSRCSEng**, is a Consultant in Restorative Dentistry at Guy's and St Thomas' NHS Hospitals Trust, Guy's Hospital, London, and a Specialist in Restorative Dentistry and Prosthodontics, and is in specialist practice in London. He is also the joint author of *Implants in Clinical Dentistry*.

**informa**  
healthcare

[www.informahealthcare.com](http://www.informahealthcare.com)

ISBN 0-415-39850-9



9 780415 398503